

# Oromandibular reconstruction with simultaneous free flaps: experience on 10 cases

## *La ricostruzione dei difetti oro-mandibolari compositi con due lembi liberi: nostra esperienza su dieci casi*

B. BIANCHI, S. FERRARI, T. POLI, F. BERTOLINI, T. RAHO, E. SESENNA  
Division of Maxillo-Facial Surgery, University of Parma, Italy

### Key words

Oromandibular reconstruction • Free flap • Fibula free flap  
• Iliac crest free flap

### Parole chiave

Ricostruzione oro-mandibolare • Lembi rivascolarizzati • Lembo di fibula • Lembo di ala iliaca

### Summary

Composite defects resulting from surgery for advanced oral cancer represent a difficult reconstructive problem and, in some cases, tissutal defects are extensive requiring multiple free flaps. Personal experience is reported with double free-flap technique in the reconstruction of large complex defects in 10 patients treated for T4 oral squamous-cell carcinoma. Fibula osteo-cutaneous free flap was used in association with forearm free flap in 5 cases, fibula osseous-forearm in 3 cases, fibula osseous-rectus abdominis in 1 case, iliac crest-forearm in 1 case. Forearm free flap was used for intra-oral reconstruction in all cases. Total flap survival is 100% and all patients regained adequate oral diet. At the time of evaluation (February 2001), 40% of patients are alive and mean survival rate is 36 months. In conclusion, simultaneous free flap reconstruction, in massive oro-mandibular defects, represents in some selected patients, a good choice to achieve satisfactory aesthetic and functional results.

### Riassunto

*I difetti compositi risultanti dell'asportazione di tumori avanzati di cavo orale e orofaringe presentano grandi difficoltà dal punto di vista ricostruttivo e, talvolta, la perdita tissutale è talmente ampia e complessa da richiedere più lembi microvascolari. Presso la Divisione di Chirurgia Maxillo-Facciale, in 10 pazienti sono stati trapiantati primariamente due lembi liberi nello stesso tempo operatorio al fine di ottimizzare la ricostruzione ossea, cutanea e mucosa. Abbiamo utilizzato in cinque pazienti il lembo di fibula osteocutaneo con il lembo fasciocutaneo di avambraccio, in tre quello osseo di fibula e di avambraccio, in uno osseo di fibula e mio-cutaneo di retto addominale e in 1 il lembo osteomuscolare di ala iliaca e il lembo di avambraccio. Il lembo radiale è stato da noi posizionato in tutti i pazienti a livello intraorale. Tutti i lembi sono stati trapiantati con successo e alla dimissione tutti i pazienti erano in grado di alimentarsi per via orale. Il follow-up medio è stato di 24,7 mesi e al momento dello studio il 40% dei pazienti erano viventi con una sopravvivenza media di 36 mesi. In conclusione, l'impiego di due lembi microvascolari dopo resezioni massive oro-mandibolari rappresenta in casi selezionati la tecnica ricostruttiva ideale al fine di ottenere un risultato estetico-funzionale accettabile per la vita dei pazienti affetti da tumori avanzati dell'estremo cefalico.*

## Introduction

Advanced oral cancer involving the mandible requires complex composite resection involving bone, mucosa, soft tissues, and sometimes skin.

In contrast to the pedicled flap, osseous, osteo-cutaneous, and osteo-myocutaneous free flaps have changed the oro-mandibular reconstruction on account of better healing, bone union, and survival in poor recipient site<sup>1,2</sup>.

In the majority of defects, donor sites, available for the harvesting of osseous flaps, including the iliac crest, scapula radium, and fibula have been shown to be highly reliable in restoring both the bony and soft tissue components.

Perhaps, in extensive resection or in complex

through-and-through defects, a combination of multiple microvascular flaps may be necessary to achieve optimal conditions for aesthetic and functional rehabilitation. Single transplant despite the versatile microvascular techniques may be not ideal to restore tissue defects especially in the case of intra-oral reconstruction on account of the characteristics of the skin component of the flap or due to the three-dimensional anatomy of the defect which makes flap positioning difficult<sup>3</sup>.

In these cases, the double free-flap technique is the choice procedures<sup>4</sup>.

The aim of oro-mandibular reconstruction is to restore primarily form and function, without the need of multiple procedures and prolonged hospitalisation<sup>5</sup>.

However, the simultaneous free flap procedure pre-

sents technical difficulties, prolonged surgical time, and morbidity, being, therefore, not feasible in patients in poor general conditions. As far as concerns other solutions, we use also the myo-cutaneous free flap, osseous-osteocutaneous free flaps in association with pedicled flap, reconstructive plates with myocutaneous free flap, or pedicled flap<sup>6</sup>. Herein, the indications and advantages of the free flap combinations are discussed.

## Patients and methods

A total of 10 patients (7 male, 3 female, age range 43-65 years, mean 51) with complex oro-mandibular defects underwent reconstruction using simultaneous free flap combination from January 1995 to February 2001. Of these patients, 7 presented to our attention for management of advanced primary squamous cell carcinoma (SCC) and 3 for recurrence after chemo-radiation treatment.

An analysis of defects according to Urken<sup>7</sup> classification is shown in Table I.

Osseous/osteocutaneous free flaps were harvested from the right fibula donor site in all cases, but 1 case was an osseous iliac crest free flap (young patient, good general health, dentate mandible, and 8 cm bone defect); in 5 patients, we used an osteo-cutaneous flap (anterior and lateral through-and-through defect).

Soft tissue flap, placed in the oral cavity, was harvested from the left forearm in 9 cases and from the rectus abdominis (myocutaneous) in 1 patient. In this case, the soft tissue flap was used for reconstruction of the subtotal glossectomy defect.

In one patient, a third pedicled flap (pectoralis major muscular flap) was used in association with two simultaneous free flaps to close a dead space in the submental area to reconstruct an anterior through-and-through defect.

Free flaps were harvested simultaneously by two équipes, at the end of the demolitive procedure.

The free flap containing bone was inserted primarily. We use separate pairs of recipient vessels in all patients: one ipsilateral and one contralateral in 5, and two ipsilateral in the others.

Three forearm free flaps were reinnervated to recipient ipsilateral sensory nerves.

Mean operation time was 10 hours.

## Results

### PATIENT SURVIVAL

Post-operative follow-up ranged between 12 and 72 months (median period 24.7 months).

Six patients died from their disease, 3 cases due to

systemic metastases and 3 due to local and/or regional recurrence (mean survival rate: 17.5 months).

Four patients are alive at the time of this review (median survival rate: 36 months); of these, one patient underwent resection for a primary lung tumour 3 years after first surgery and another patient was treated for primary laryngeal tumour with total laryngectomy, 1 year after oro-mandibular resection.

### FLAP SURVIVAL

Overall free flap survival was of 100%; partial skin-flap necrosis was observed in 1 patient with a fibular osteo-cutaneous free flap.

Venous congestion in 1 fibula flap required re-exploration with revision of the thrombosed venous anastomoses.

### OTHER COMPLICATIONS

One patient developed wound dehiscence, another a cervical abscess; in another patient, the reconstruction plate used to fix the iliac crest segments became exposed and, finally, in one case, an oro-cutaneous fistula occurred. Only the cervical abscess needed surgical drainage. Pneumonia complications occurred in two patients with a tracheal tube during the immediate post-operative period.

For fibula flap, donor-site problems were related to limitation in dorsiflexion of the hallux and muscular weakness, during deambulation for about two months; in the groin flap donor site, gait disturbance was experienced for two months.

### FUNCTIONAL RESULTS

At the time of discharge, all 10 patients from hospital, were able to eat by mouth with 3 patients on a normal diet and 7 on a soft diet. In 8 patients, oral competence was normal and only two patients with extensive anterior through-and-through defects present oral sphincter incompetence with severe salivary dribbling.

### CASE REPORT N. 1 (Figs. 1-7)

A 58-year-old female came to our attention for treatment of SCC of the anterior floor of the mouth extensively infiltrating bone and invading the anterior part of the tongue (T4N0M0).

The patient underwent radical tumour excision, including the mandibular arch from the first right molar to the left retromolar area. A bilateral supraomohyoid dissection was performed. The surgical defect was reconstructed using a forearm free flap and osteomuscular iliac crest free flap. The bone defect was reconstructed with a 8 cm segment of iliac crest with the muscular portion of the flap to fill the anterior defect. The deep circumflex iliac artery was anastomosed with the right superior thyroid artery (terminal-terminal), and the vein with the external jugular

**Table 1.** DOD: died from the disease; NED: alive, no evidence of disease; SCC: squamous cell carcinoma; B: body; R: ramus; S: symphysis; FOM: floor of mouth (l: lateral; a: anterior); PH: pharynx (l-lateral wall); TM: tongue mobile (1/2: half; 1/4: one quarter); TB: tongue base (1/2: half; 1/4: one quarter); S: skin (M: mental; N: neck); HN: hypoglossal; LN: lingual; IAN: inferior alveolar (B: bilateral); LND: lateral neck dissection (S: suprahyoid; M: functional; R: radical).

Patient (no.) age, sex	Tumour type, site	Radiotherapy	Mandibular defect	Soft tissue defect	Nervous defect	Neck dissection	Free flap	Other flap	Complications	Follow-up
No. 1 43, M	SCC T4N0 M0	Post-op.	SBR	FOM l-a, TM1/2 SN	HN IAN LN	MLND left	Fibula Forearm		Venous thrombosis fibula flap: salvaged	NED
No. 2 58, F	SCC T4N0M0	Post-op.	BSBR	FOM l-a-l, TM	IAN B LN B	SLND right SLND left	Fibula Forearm		Orocutaneous fistula	DOD
No. 3 55, M	SCC T4N0M0	Pre-op.	BSB	FOM l-a-l, TM, SM, SN	IAN B LN B	SLND right SLND left	Fibula Forearm	Pectoralis		DOD
No. 4 48, M	SCC T4N1M0	Post-op.	BSB	FOM l-a-l, TM	IAN B LN B	MLND right SLND left	Fibula Forearm		Cervical abscess	NED
No. 5 44, M	SCC T4N0M0	Pre-op.	RBS	FOM l-a, TM, TB 1/2, PH I	HN IAN LN	SLND right SLND left	Fibula Rectus Abdominis			DOD
No. 6 58, F	SCC T4N0M0	Post-op.	BSB	FOM l-a-l, TM	IAN B	SLND right SLND left	Iliac crest Forearm		Plate exposure	NED
No. 7 46, F	SCC T4N0M0	Post-op.	BSB	FOM l-a-l, TM1/2, SM	IAN B LN	SLND right SLND left	Fibula Forearm		Skin dehiscence	DOD
No. 8 65, M	SCC T4N1M0	Post-op.	BSBR	FOM l-a-l, TM, SM	IAN B LN B	SLND right MLND left	Fibula Forearm		Partial skin necrosis	DOD
No. 9 45, M	SCC T4N0M0	Post-op.	BSB	FOM a-l, TM1/2	IAN LN	SLND right SLND left	Fibula Forearm			DOD
N° 10 54, M	SCC T4N0M0	Pre-op.	BS	FOM a-l, TM1/2, TB 1/2, PH I SN	HN IAN LN	SLND right SLND left	Fibula Forearm			NED

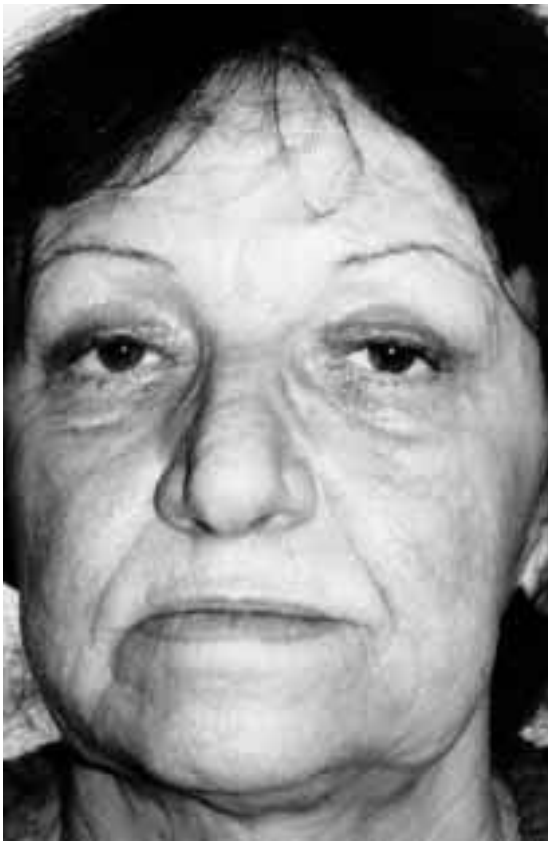

Fig. 1. Pre-operative frontal appearance (case n. 1).

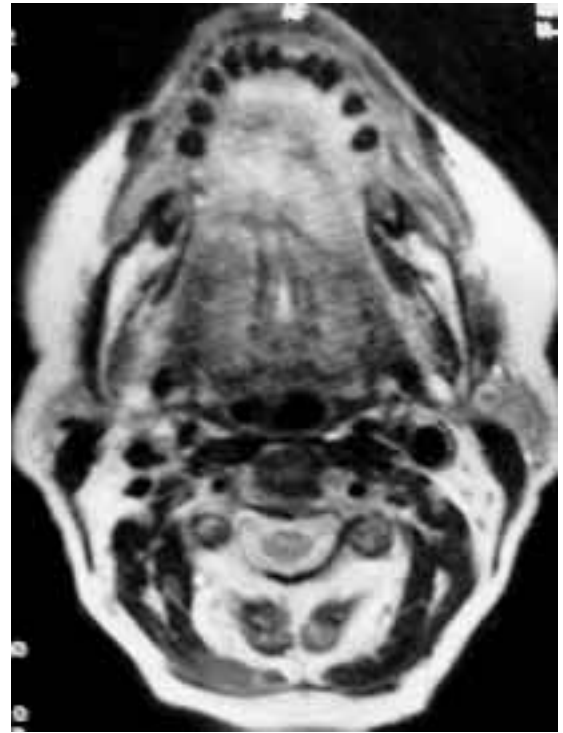

Fig. 2. Pre-operative MRI showing tumour extension.

vein (termino-terminal).

Intra-oral soft tissue reconstruction was achieved with the use of 4x6 cm fasciocutaneous forearm free flap. The radial artery was anastomosed with the left superior thyroid artery and the cephalic vein, while one comitans vein with the left internal jugular vein. The post-operative period was uneventful and 5 weeks later, radiotherapy was started.

Six months after surgery, plate exposure on the mental skin area required a modification.

The patient is still alive at the 24th post-operative month.

#### CASE REPORT N. 2 (Figs. 8-15)

A 54-year-old male came to our attention for treatment of recurrence of SCC of the tongue after radiotherapy with a cutaneous right submandibular radiodermic area (T4N0M0).

The patient underwent supraomohyoid right neck dissection with submandibular overlying skin excision (8x3 cm), supraomohyoid left neck dissection and tumour excision including the mobile and 1/2 base tongue, the floor of the mouth, and the lateral pharynx with a segment of the mandible.

The resulting composite defect (right body and symphysis) was reconstructed with simultaneous fibula osteocutaneous and fasciocutaneous forearm free flaps.

The bone and the submandibular skin were reconstructed with the fibula free flap and the pedicle was anastomosed to the right lingual artery and internal jugular vein. The oral defect was reconstructed with a forearm free flap. The pedicle was anastomosed to left superior thyroid artery and left internal jugular vein. The post-operative course was uneventful.

The patient is in good health after 13 months, with satisfactory aesthetic appearance.

#### Discussion

Despite advancement in surgical techniques, prognosis of patients with advanced head and neck tumour is poor (5 year survival rate is approximately 25%). Furthermore, despite the advancements in adjuvant and neoadjuvant chemo-radiation protocols, radical surgery represents almost the only treatment even if it causes complex and invalidating defects involving oral mucosa, soft tissue, skin, bone, and motor and sensitive nerves. In oncologic surgery, the goal is to achieve tumour-free margins with functional and aesthetic restoration, so that the quality of life is as little

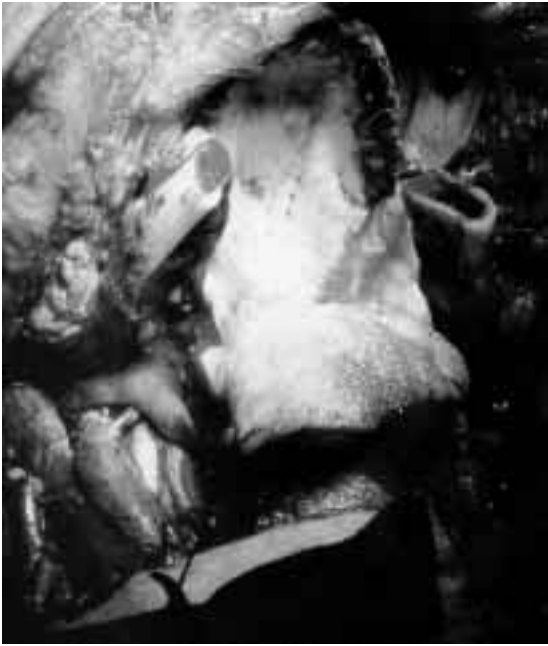

Fig. 3. Intra-operative view after demolitive procedure.

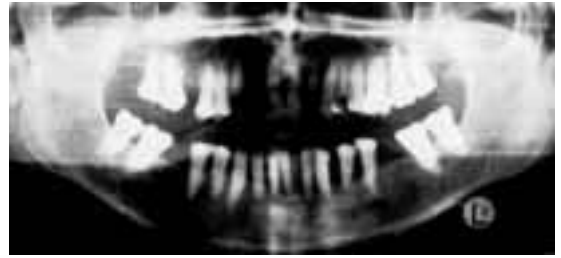

Fig. 5. Pre-operative panoramic x-ray.

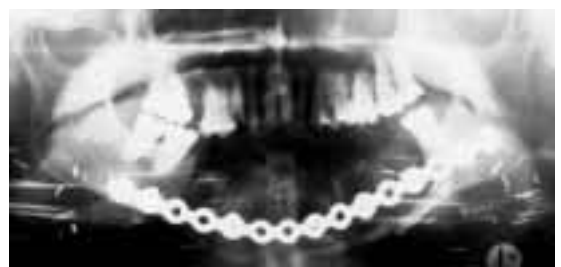

Fig. 6. Post-operative panoramic x-ray.

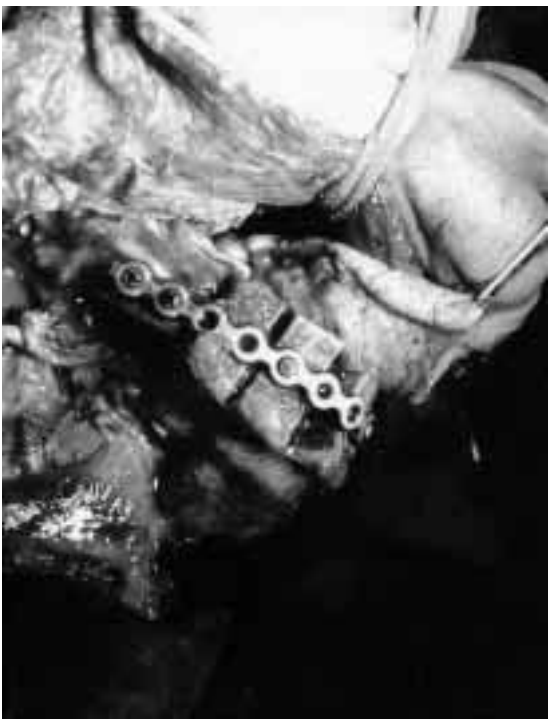

Fig. 4. Intra-operative appearance after reconstructive procedure.

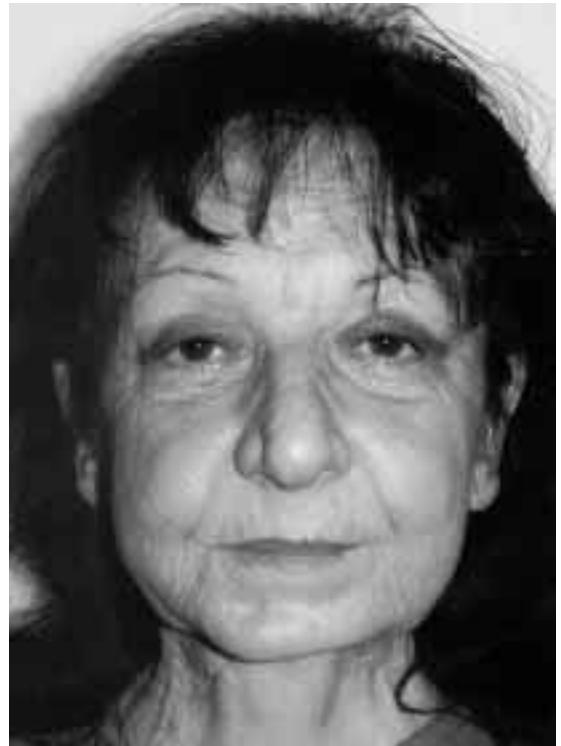

Fig. 7. Post-operative frontal appearance.

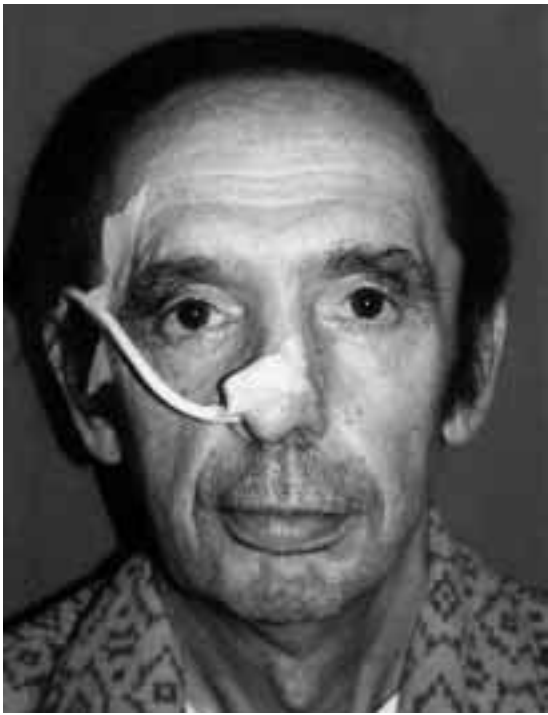

Fig. 8. Pre-operative frontal appearance (case n. 2).

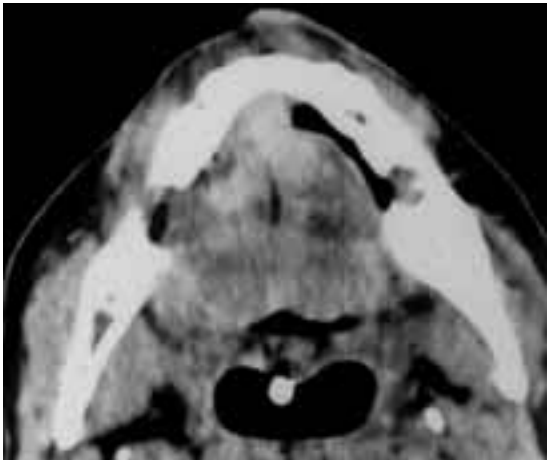


Fig. 9. Pre-operative TC scan.

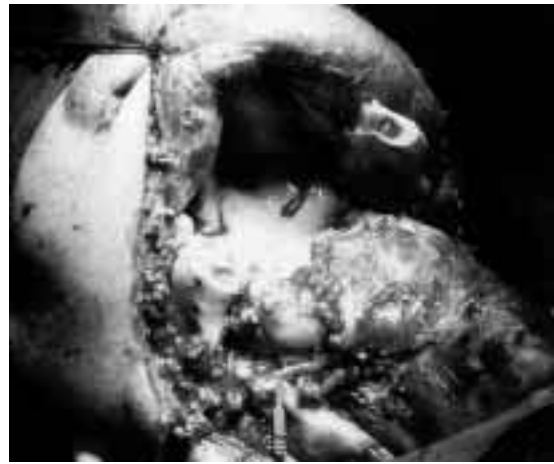


Fig. 10. Intra-operative appearance after demolitive procedure.

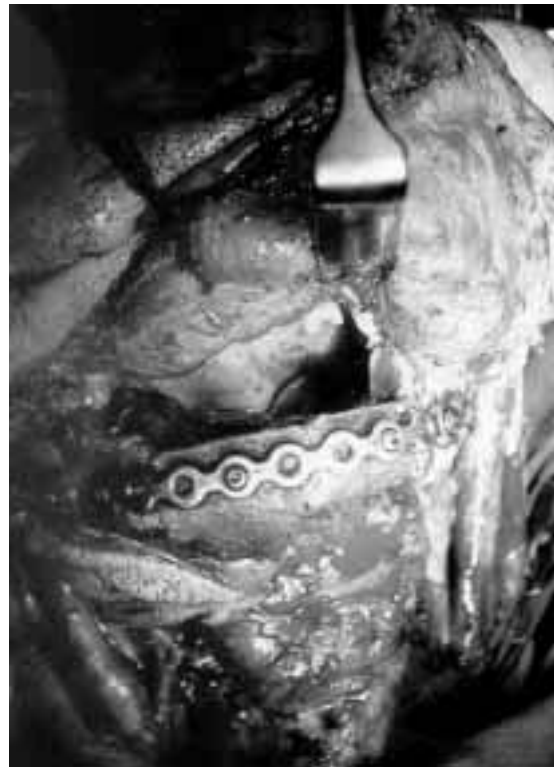

Fig. 11. Intra-operative appearance after fibula free flap inset.

impaired as possible.

Thus the ultimate result of oro-mandibular reconstruction largely depends on the anatomy, site, dimensions of the defect, amount of mandibular resection as well as the type of reconstruction itself. The introduction of microvascular techniques has

revolutionised oro-mandibular reconstruction, since transfer of free tissue offers a primary one-stage procedure with a high rate of success as well as reduc-

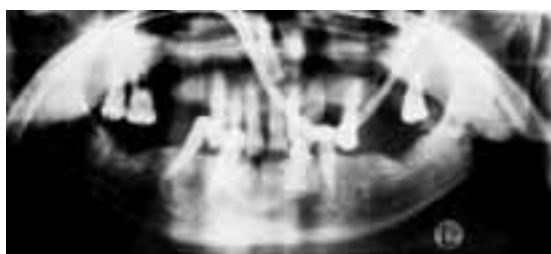

Fig. 12. Pre-operative panoramic x-ray.

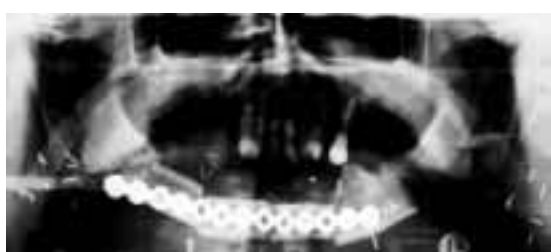

Fig. 13. Post-operative panoramic x-ray.

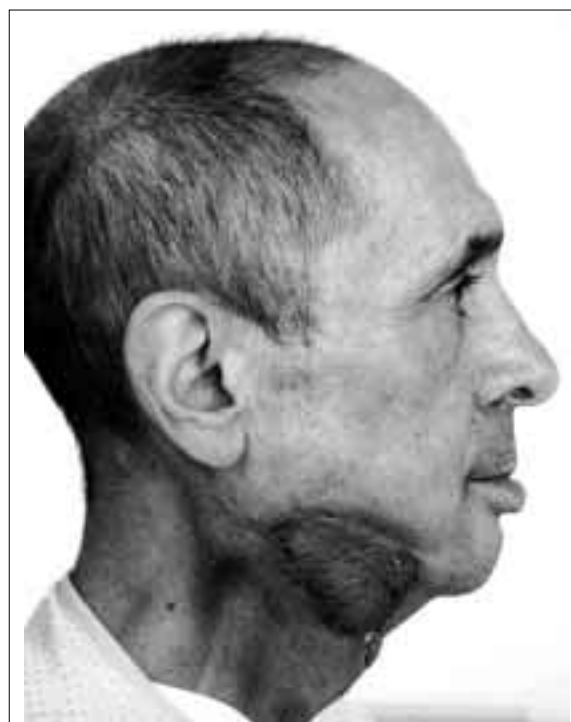


Fig. 15. Post-operative lateral appearance.

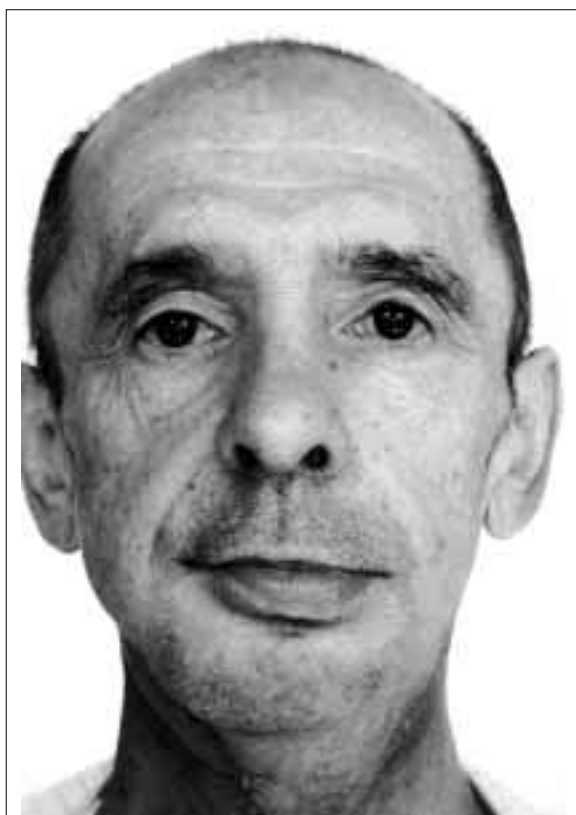


Fig. 14. Patient post-operative frontal appearance.

tion of hospitalisation, in comparison to the conventional reconstructive techniques. Otherwise, the low rate of post-operative complications offers the opportunity to carry out adjuvant radiotherapy within a few weeks after surgical procedure<sup>8</sup>.

The free flap donor sites preferentially used allow primary reconstruction of bone and soft tissue<sup>9,10</sup>.

Soft tissue restoration allows movement of the tongue after partial glossectomy or floor of the mouth resection, mouth opening in the case of cheek resection, and maintenance of normal oropharyngeal function in oropharyngeal resection. In the head and neck region the deficit of soft tissue leads to a dead space with consequently risk of infection, due to a secondary accumulation of serum and saliva, scar formation with impairment in mobility of the intra-oral structures, and wound dehiscence resulting in immediate post-operative complications<sup>11</sup>. Adjuvant radiotherapy, moreover, increases post-operative atrophy, scarring and fibrosis.

The characteristics of the skin flap have to be related to the type of defect: i.e., pliability and thinness for lining mucosal defects, and additional bulk for volume replacement, in extensive soft-tissue deficiency (fat and muscle)<sup>12,13</sup>.

The requirement of bone implants used in mandibular reconstruction includes possibility of multiple osteotomies, strong enough to withstand mastication

forces, able to accommodate endosteal implants with minimal donor site morbidity<sup>14</sup>.

At present, there is no single ideal free flap either bony or soft tissues in particular, in extensive anterior and lateral through-and-through defects or in partial mandibular resection associated with tongue resection, the single free flap shows limitations thus representing an indication for simultaneous free flaps<sup>15 16</sup>.

Some cases of secondary reconstruction following oncologic microvascular surgery for correction of residual deformity have been described in the literature limiting this approach only to carefully selected cases<sup>17</sup>.

Among the various donor sites available for harvesting osseous flaps, the iliac crest, scapular, and fibular flaps seem to be very reliable for reconstruction of mandibular defects, whereas the amount of bone available from radius, ulna, rib and metatarsus is inadequate, not osteotomised and, moreover, morbidity at the donor site is high.

Many factors influence selection of the vascularized flap donor site: age, general health status, extension and site of the defect, status of dentition.

We prefer to use the iliac crest free flap in young patients with trophic mandible, in lateral defect, including the angle<sup>18</sup>, and in all the cases in which fibula free flap is not amenable due to vascular disorders (atherosclerosis, venous thrombosis, etc.). Soft tissue components of the flap include skin and muscle. The skin paddle may be used to replace the skin defect, but it is not suitable to replace intra-oral structures due to excessive bulk, particularly in obese patients and on account of the limited mobility relative to the bone. The oblique internal muscle<sup>19</sup> offers several advantages when positioned in the oral cavity for a paramandibular defect (alveolar ridge, lateral/posterior floor of the mouth) or for the pharyngeal wall, but shows limits in partial glossectomy and/or extensive resection of the floor of the mouth. In fact, secondary muscle contracture interferes with the residual tongue movement.

Moreover, we experienced an increase in post-operative morbidity due to the absence of a watertight closure between the oral cavity and the neck, with risks of salivary fuites, infection, and exposure of the reconstruction plate. Besides, it is necessary to use redundant internal oblique muscle in the event of denervated muscle atrophy, occurring late in time.

The vascularized fibula flap has become our method of choice for mandibular restoration not only for the characteristics of bone, but also for the amount of bone which is generally adequate in most defects; pedicle length and vessel diameter make the microsurgical transfer easier with minimal donor-site morbidity, and the possibility of the simultaneous two-team approach reduces peri-operative time. Instead,

fibular skin is thinner and with more mobility in relation to the bone than that in the groin area and it is not suitable for oral and oropharyngeal reconstruction (thinness, pliability, adherence to the neomandible, possibility of sensory recovery<sup>20</sup>).

The scapular flap is the most versatile for extensive defects since it is possible to harvest the bone from the lateral border and the angle of the scapula with multiple skin paddles and muscle with great manoeuvrability as far as concerns the bone. The major drawback in the use of the scapular system is bone quality, the thickness of the skin flap is not ideal for intra-oral reconstruction, and since the patient must be positioned on one side, it is impossible for two teams to work simultaneously<sup>21 22</sup>.

In the selection of a soft-tissue flap, the forearm free flap represents the first choice for a mucosal defect especially in the case of reconstruction of the floor of the mouth and of the tongue in order to maintain residual movement and vestibular sulcus<sup>23</sup> for dental rehabilitation. When large areas of the floor of the mouth and pharynx have been resected, the forearm free flap provides innervated skin through the use of the sensory neurofasciocutaneous flap, enhancing mastication, deglutition, and oral hygiene.

The rectus abdominis free flap, instead, offers the advantage of introducing bulk to achieve adequate volume replacement, with the possibility of simultaneously transplanting muscle, fat, and skin with minimal donor-site morbidity<sup>24</sup>.

In our study, we used the technique of simultaneous free tissue transplants to provide optimal bone and soft tissue reconstruction to improve quality of life. However, the double free flap technique can be used only in selected cases (of the 70 oro-mandibular reconstructions, only 10 patients received the simultaneous flap transfer).

In anterior oromandibular defects, where primary bony reconstruction is mandatory, we use the osteocutaneous fibular free flap, except in young patients with normal mandibular height or if the bony defect does not exceed 15 cm in which case we use the osseous-osteo-muscular iliac free flap. When the soft tissue defect is extensive (floor of the mouth and partial or sub-total tongue resection), we prefer to proceed with the association of vascularized bone with the soft tissue free flap, in particular the fascio-cutaneous forearm free flap.

In fact, a single composite free flap, due to the intrinsic characteristics of the skin paddle, is not suitable to maintain residual tongue mobility and to maximise post-operative oro-pharyngeal functions.

In through-and-through defects, submental or mental skin reconstruction may be achieved with various techniques depending on the extension, site, and previous treatments. Local or loco-regional flaps such as cervico-facial or cervico-pectoral, respectively, provide the

best aesthetic results, but are not suitable in areas previously submitted to surgical or radiation treatment; in these cases, pedicled pectoral myocutaneous or cutaneous composite free flaps are preferred<sup>25</sup>.

In our experience, in 5 through-and-through anterior defects we used as skin component, the fibula osteo-cutaneous transplant for the extra-oral defect associated with the fascio-cutaneous free flap for intra-oral repair. Simultaneous reconstruction of the mucosa and skin defect with a single flap causes impairment in movement of the residual intra-oral structures and does not provide pliable tissue, thus leading to poor functional and aesthetic results.

In one case of an anterior defect including the anterior mandibular arch with an extensive extraoral and intraoral soft tissue deficit, we used a fibula osteo-cutaneous free flap in association with a fascio-cutaneous free flap and a third pedicled pectoralis muscular flap; the use of the pedicled flap was necessary to obliterate the dead space under the newly-reconstructed bony arch due to the risk of infection and fistulas in the immediate post-operative period, and scar retraction with distortion of the newly reconstructed mandible in the later post-operative period<sup>25,26</sup>.

In more lateral/posterior defects, in older patients and in patients in poor general conditions, we prefer to perform the pedicled flap or myo-cutaneous free flap in association with a reconstructive plate, if dentition is present<sup>27</sup>.

In all other cases, we perform bone reconstruction with a fibula free flap (first choice), or with an iliac crest free flap (young patient, dentition, etc.).

Nevertheless, when resection extends to the skin, the single composite free flap has proved to be inadequate and a second transplant is used to make the reconstructive procedure easier. For partial glossectomy, with resection of the floor of the mouth, a simultaneous fascio-cutaneous free flap is the better choice; when a volume defect is present, it is possible to proceed with the association of a vascularized free flap with a myo-cutaneous free transplant (rectus abdominis or latissimus dorsi) in order to achieve an adequate volume replacement also after radiation treatment.

In all patients, we used separate vessels for anastomoses, while in some cases bilateral neck dissection permitted use of bilateral recipient vessels.

In two cases requiring radical neck dissection, a pedicle of a forearm free flap harvested with additional

subcutaneous tissue was anastomosed with the transverse cervical artery and the ascending cervical artery respectively. This technique permits protection of the carotid artery, using recipient vessels not damaged by previous radiation treatments. For venous drainage, we used in both patients the internal jugular vein for venae comitans and the external jugular vein for cephalic vein.

When possible, we perform two venous anastomoses with two different drainage systems (internal and external jugular veins or their tributary).

In conclusion, simultaneous free flaps transplant in extensive oromandibular defects permits optimal use of the different tissue components, three-dimensional anatomy reconstruction, primary healing in previously treated fields with reduction of post-operative complications, and optimal oromandibular reconstruction.

Although the prognosis of advanced oral and oropharyngeal tumours is poor (60% of patients die with a median survival rate of 17.5 months), it appears that an aggressive surgical approach is justified on account of the possibility of disease-free long-term survival and the resolution of symptoms arising from progression of the tumour mass. Disphagia, pain, bleeding and infection, in fact, reduce patients' quality of life. The choice of traditional techniques, due to the grim prognosis, is justifiable only in some cases on account of the high risks of complications and long-term hospitalisation. Moreover, prolonged hospitalisation prevents commencing adjuvant radiation treatment within a reasonable time.

## Conclusions

The aim of reconstructive surgery is satisfactory aesthetic and functional restoration. In the oromandibular area, a reasonable outcome can be achieved only with ideal osseous and soft tissue reconstruction.

In our opinion, in selected patients with extensive oromandibular defects associated with mobile tongue, floor of the mouth, and tongue base resection, simultaneous free flaps are the reconstructive procedure of choice to maximize the characteristics of each flap within a reasonable operating time (10 hours) and with a high success rate (100%).

## References

- <sup>1</sup> Cordeiro PG, Disa JJ, Hidalgo DA. *Reconstruction of the mandible with osseous free flaps: a 10 year experience with 150 consecutive patients*. *Plast Reconstr Surg* 1999;104:1314-20.
- <sup>2</sup> Takushima A, Harii K, Asato H, Nakatsuka T, Kimata Y. *Mandibular reconstruction using microvascular free flaps: a statistical analysis of 178 cases*. *Plast Reconstr Surg* 2001;108:1555-63.
- <sup>3</sup> Wells MD, Luce EA, Edwards AL, Vasconez H, Sadove R, Bouzaglou S. *Sequentially linked free flaps in head and neck reconstruction*. *Clin Plast Surg* 1994;21:59-67.
- <sup>4</sup> Wei FC. *A review of 715 consecutive free flaps for oncologic surgical defects: refinement in donor-site selection and technique*. *Plast Reconstr Surg* 1998;102:733-4.
- <sup>5</sup> Urken ML. *Composite free-flap in oromandibular reconstruction: review of the literature*. *Arch Otolaryngol Head Neck Surg* 1991;117:724-32.
- <sup>6</sup> Blackwell K, Lacombe V. *The bridging lateral mandibular reconstruction plate revisited*. *Plast Reconstr Surg* 1999;125:988-93.
- <sup>7</sup> Urken ML, Weinberg H, Vickery C, Buchbinder D, Lawson W, Biller HF. *Oromandibular reconstruction using microvascular composite free flap: report of 71 cases and a new classification scheme for bony, soft tissue, and neurologic defects*. *Arch Otolaryngol Head Neck Surg* 1991;46:733-44.
- <sup>8</sup> Haughey BH, Wilson E, Kluwe L, Piccirillo J, Fredrickson J, Sessions D, et al. *Free flap reconstruction of the head and neck: analysis of 241 cases*. *Otolaryngol Head Neck Surg* 2001;125:10-7.
- <sup>9</sup> Urken ML, Weinberg H, Buchbinder D, Lawson W, Biller HF. *Microvascular free flaps in head and neck reconstruction: report of 200 cases and review of complications*. *Arch Otolaryngol Head Neck Surg* 1994;120:633-40.
- <sup>10</sup> Schliephake H, Jamil MU. *Impact of intraoral soft-tissue reconstruction on the development of quality of life after ablative surgery in patients with oral cancer*. *Plast Reconstr Surg* 2002;109:421-30.
- <sup>11</sup> Boyd JB, Morris S, Rosen IB, Gullane P, Rotstein L, Freeman JL. *The through-and-through oromandibular defect: rationale for aggressive reconstruction*. *Plast Reconstr Surg* 1994;93:44-53.
- <sup>12</sup> Swanson E, Boyd J, Manktelow R. *The radial forearm free flap: reconstructive applications and donor-site defect in 35 consecutive patients*. *Plast Reconstr Surg* 1990;85:258-66.
- <sup>13</sup> Soutar DS, Scheker LR, Tanner NSB, McGregor IA. *The radial forearm flap: a versatile method for intraoral reconstruction*. *Br J Plast Surg* 1983;36:1-8.
- <sup>14</sup> Hidalgo DA, Pusic AL. *Free-flap mandibular reconstruction: a 10-year follow-up study*. *Plast Reconstr Surg* 2002;110:438-49.
- <sup>15</sup> Wei FC, Celik N, Chen HC, Cheng MH, Huang WC. *Combined anterolateral thigh flap and vascularized fibula osteoseptocutaneous flap in reconstruction of extensive composite mandibular defects*. *Plast Reconstr Surg* 2002;109:45-52.
- <sup>16</sup> Wei FC, Demirkan F, Chen HC, Chen IH. *Double free flaps in reconstruction of extensive composite mandibular defects in head and neck carcinoma*. *Plast Reconstr Surg* 1999;103:39-47.
- <sup>17</sup> Wei FC, Demirkan F, Chen HC, Chen IH. *Management of secondary soft-tissue deficits following microsurgical head and neck reconstruction by means of another free flap*. *Plast Reconstr Surg* 1999;103:1158-66.
- <sup>18</sup> Urken ML, Vickery C, Weinberg H, Buchbinder D, Lawson W, Biller HF. *The internal oblique iliac crest osseomyocutaneous free flap in oromandibular reconstruction: report of 20 cases*. *Arch Otolaryngol Head Neck Surg* 1989;115:339-49.
- <sup>19</sup> Urken ML, Weinberg H, Vickery C, Buchbinder D, Lawson W, Biller MF. *The internal oblique-iliac crest free-flap in composite defects of the oral cavity involving bone, skin and mucosa*. *Laryngoscope* 1991;101:257-70.
- <sup>20</sup> Strackee SD, Kroon FH, Jaspers JE, Bos KE. *Modelling a fibula transplant in mandibular reconstructions: evaluation of the effects of a minimal number of osteotomies on the contour of the jaw*. *Plast Reconstr Surg* 2001;108:1915-21.
- <sup>21</sup> Urken ML, Bridger AG, Zur KB, Genden EM. *The scapular osteofasciocutaneous flap: a 12-year experience*. *Arch Otolaryngol Head Neck Surg* 2001;127:862-9.
- <sup>22</sup> Swartz WM, Banis JC, Newton ED, Ramasastry SS, Jones NF. *The osteo-cutaneous scapular flap for mandibular and maxillary reconstruction*. *Plast Reconstr Surg* 1986;77:530-45.
- <sup>23</sup> Urken ML, Weinberg H, Vickery C, Aviv JE, Buchbinder D, Lawson W, et al. *The combined sensate radial forearm and iliac crest free flaps for reconstruction of significant glossectomy-mandibulectomy defects*. *Laryngoscope* 1992;102:543-58.
- <sup>24</sup> Sanger JR, Matloub HS, Yousif NJ. *Sequential connection of flaps: a logical approach to customized mandibular reconstruction*. *Am J Surg* 1990;160:402-4.
- <sup>25</sup> Blackwell KE, Buchbinder D, Biller H, Urken ML. *Reconstruction of massive defects in the head and neck: the role of simultaneous distant and regional flaps*. *Head Neck* 1997;19:620-8.
- <sup>26</sup> Chen HC, Demirkan F, Wei FC, Chen SL, Cheng MH. *Free fibula osteoseptocutaneous-pedicled pectoralis major myocutaneous flap combination in reconstruction of extensive composite mandibular defects*. *Plast Reconstr Surg* 1999;103:839-45.
- <sup>27</sup> Poli T, Ferrari S, Bianchi B, Sesenna E. *Primary reconstruction of lateral oro-mandibular defects using titanium plates (THORP) and revascularized non-osseous flaps: a personal experience*. *Acta Otorhinolaryngol Ital* 2002;21:290-9.

■ Received August 19, 2002.  
Accepted January 7, 2003

■ Address for correspondence: Dr. B. Bianchi, Divisione di Chirurgia Maxillo-Facciale, via Gramsci 14, 43100 Parma, Italy. Fax: +39 0521 703761. E-mail: bbianchi@ao.pr.it