Case series and reports

Defect-oriented reconstruction after transoral robotic surgery for oropharyngeal cancer: a case series and review of the literature

La ricostruzione dei difetti dopo chirurgia robotica transorale per i tumori dell'orofaringe: casi clinici e review della letteratura

G. MECCARIELLO[1], F. MONTEVECCHI[1], R. SGARZANI[2], C. VICINI[1]

[1] Department of Head-Neck Surgery, Otolaryngology, Head-Neck and Oral Surgery Unit, Morgagni Pierantoni Hospital, Azienda USL della Romagna, Forlì, Italy; [2] Department of Emergency, Burn Center, Bufalini Hospital, Azienda USL della Romagna, Cesena, Italy

SUMMARY

Transoral robotic surgery (TORS) is a fascinating new technique that has been shown to be a safe and feasible treatment for selected oropharyngeal cancers. Furthermore, TORS might offer some advantages in selected locoregionally advanced cancers. Thus, the patient selection is the keypoint for the useful application of TORS. However, the reconstruction of large oropharyngeal defects is challenging due to the restoration of velopharyngeal competency and swallowing. Moreover, the absence of mandibular splitting increases the difficulties faced by reconstructive surgeons. The paradigm for oropharyngeal reconstruction has undergone changes paralleling reflecting the overall change in the trend of the treatment alternatives over the last few decades. Flap choice and harvesting should be tailored to obtain significant advantages both in functional terms and for easy insetting. In this review, we analyse the strengths and weaknesses of the various flaps used in TORS framework with particular regards on our preliminary experience.

KEY WORDS: Transoral robotic surgery • Reconstruction • Oropharyngeal carcinoma • Minimally invasive surgery • Flap

RIASSUNTO

La chirurgia transorale robotica (TORS) rappresenta una potenziale modalità di trattamento dei tumori dell'orofaringe. Sebbene la radiochemioterapia rivesta un ruolo di primaria importanza nel trattamento delle forme localmente avanzate, la TORS in casi selezionati permette di ottenere una resezione nel rispetto dei canoni della chirurgia oncologica evitando la mandibulotomia e conseguentemente le complicanze da essa derivate. Tuttavia, gli ampi difetti chirurgici che possono derivare abbisognano necessariamente di una fase ricostruttiva che consenta, oltre a ricoprire strutture nobili un discreto ripristino delle funzionalità deglutitorie. In letteratura sono stati descritti diversi approcci ricostruttivi per lesioni di piccole e grandi dimensioni con lembi peduncolati o liberi. La difficoltà maggiore potenziale nella ricostruzione dell'orofaringe in assenza di una mandibulotomia è l'inserimento del lembo ricostruttivo nella cavità, soprattutto quando si utilizzano lembi liberi. Lo scopo di questo articolo è di analizzare pregi e difetti delle opzioni ricostruttive (già descritte in letteratura) in base al difetto creatosi con particolare riguardo anche alla nostra esperienza preliminare.

PAROLE CHIAVE: *Chirurgia robotica transorale • Ricostruzione • Carcinoma orofaringeo • Chirurgia mini-invasiva • Lembi ricostruttivi*

Cite this article as: Acta Otorhinolaryngol Ital 2018;38:569-574. https://doi.org/10.14639/0392-100X-1473

Introduction

Primary chemoradiation therapy (CRT) and transoral robotic surgery (TORS) with or without adjuvant CRT are competing therapeutic approaches with similar oncologic outcomes in the management of oropharyngeal squamous cell carcinoma (OPSCC) [1]. However, CRT may also result in significant functional impairments such as severe dysphagia and feeding tube dependence [2]. On the other hand, TORS may lead to debilitating post-ablative defects depending on the size and anatomic location of the defect. TORS may benefit the patients through pathologic downstaging as well as the potential for improvement in oncologic outcomes, identifying the primary tumour, or reducing the toxicity of definitive chemoradiation therapy [3]. From this point of view, TORS might offer some advantages in select-

ed locoregionally advanced patients (i.e. early T3 lesions, cN2-3). Moreover, The National Comprehensive Cancer Network guidelines recognise transoral surgery as a potentially useful tool in the treatment of selected patients in this setting [4]. The paradigm for oropharyngeal reconstruction has undergone changes reflecting the overall change in the trend of the treatment alternatives over the last few decades. The aim of this study is to highlight the reconstruction options for oropharyngeal defects after TORS and to analyse the particular characteristics that guide the surgeon towards the best tailored reconstruction.

Case #1

A 65-year-old male patient with a cT2N1 OPSCC p16- tumour, involving the left anterior pillar extending to the homolateral soft palate (Fig. 1A), was referred to our Institution. The history revealed smoking and light drinking habits, and no significant comorbidities. The patient was scheduled for TORS and selective neck dissection (SND) of levels I-IV. A tracheostomy was performed prior to robotic surgery. Next, a Feyh-Kastenbauer retractor (Gyrus Medical Inc., Maple Grove, MN) was used to expose the operative field. The tumour margins were observed intraoperatively with a 0° or 30° 8 mm Hopkins scopes (Karl Storz, Germany) using white light and a narrow band imaging (NBI) high-definition video- endoscopy system (CV-260SL processor, CVL-260SL light source, Olympus Optical Co., Ltd., Japan). The edges of surgical excision were marked with monopolar cautery and controlled with NBI (Fig. 1B). The daVinci® Surgical Robotic System (Intuitive Surgical, Sunnyvale, CA) was positioned 30° angled on the right side of the patient. 0° or 30° 8.5 mm endoscopes were used with two 5 mm side arms Maryland dissectors and cautery (Fig. 1C). All vessels encountered during the resection were clipped prior to transaction. The entire surgical specimen was oriented and submitted to the pathologist for intraoperative assessment of the margin status with frozen sections. Next, the SND was performed. Once neck dissection was completed and clear margins confirmed by the pathologist, the temporalis muscle flap (TMF) was easily harvested and transposed to resurface the defect (Fig. 2). A nasogastric tube was placed. Tracheotomy was closed on postoperative day 5 and the patient resumed oral feeding on day 7 and discharged on day 9 with normal diet. The pathological report was consistent with a pT2N0 R0 OPSCC p16-. No indications for adjuvant treatment was posed at multidisciplinary tumour board. No swallowing disorders were reported after 6 months of follow-up.

Case #2

A 61-year-old male patient with a cT3N2c OPSCC p16- (Figure 3) tumour, involving the left soft palate, tonsil and homolateral base of tongue (BOT), was referred to our Institution. The history revealed heavy smoking and drinking habits, and no other significant comorbidities. CT and PET scan did not demonstrate distant metastasis. The patient was scheduled for TORS and bilateral modified radical neck dissection (MRND) with tracheostomy. The edges of surgical excision were marked in the same way as previously described as well as the robotic setting. The margin status with frozen sections were assessed. During the neck dissection, an antero-lateral thigh flap (ALT) was harvested with a three-petal shape skin paddle (Fig. 4). A nasogastric tube was placed. Tracheotomy was closed on postoperative day 8 and the patient resumed oral feeding on day 15 and discharged on day 20 with normal diet. The pathological report was consistent with a pT3N2c R0 OPSCC p16- lesion with extracapsular spread in one of the left cervical lymph nodes. The multidisciplinary tumour board posed indication for adjuvant CRT. No experience of loco-regional relapse or swallowing impairment were recorded after 3 months of follow-up.

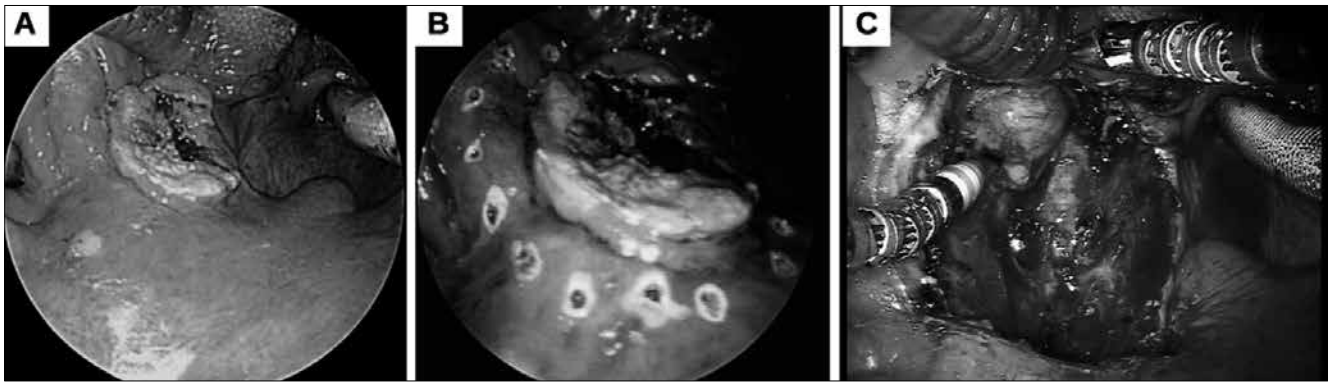

Fig. 1. A) Endoscopic view of the tumour. **B)** Checking the surgical edges with NBI. **C)** Endoscopic view of surgical field after completed tumour resection.

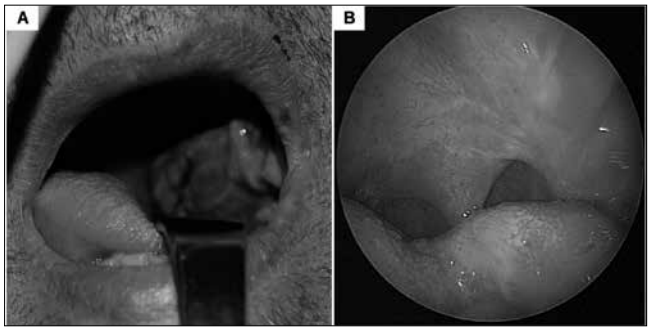

Fig. 2. A) The temporalis muscle flap on the fifth postoperative day. **B)** Endoscopic view of the left lateral pharyngeal and soft palate reconstructed with temporalis muscle flap after one month.

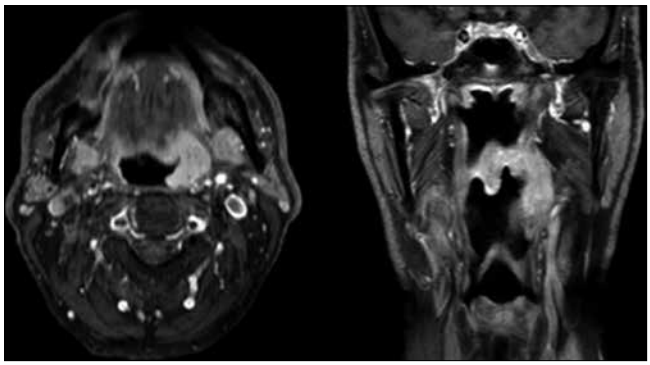

Fig. 3. Magnetic resonance imaging showing the extension of lesion: left base of tongue, tonsil and soft palate.

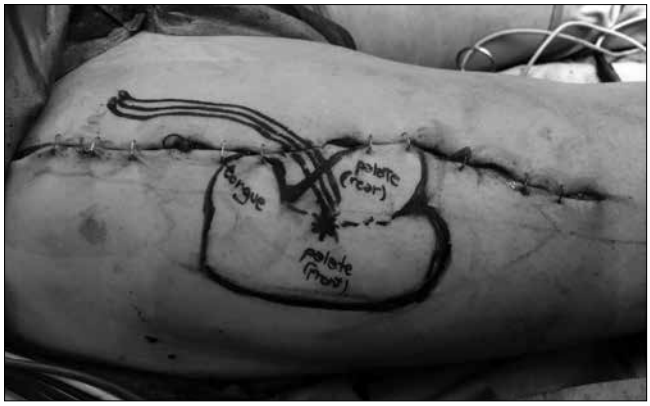

Fig. 4. Modified skin paddle of antero-lateral thigh flap according to Caliceti et al.

Case #3

A 51-year-old male patient with a cT3N0 OPSCC p16- tumour, involving the left tonsil, base of tongue and partially the soft palate, was referred to our Institution. The history revealed moderate smoking and heavy drinking habits, and no other significant comorbidities. MRI and CT scan did not demonstrate regional or distant metastasis. The patient was scheduled for TORS and SND levels II-IV with tracheostomy. The robotic resection and the reconstruction were performed in the same fashion described above. A nasogastric tube was placed. Tracheotomy was closed on postoperative day 6 and the patient resumed oral feeding on day 15 and discharged on day 17 with normal diet. The pathological report was consistent with a pT3N0 R0 OPSCC p16- lesion. The multidisciplinary tumour board posed indication for adjuvant radiotherapy on the oropharynx due to extension of the primary tumour. At 3-month follow-up, the patient did not experience any swallowing impairment or local relapses (Fig. 5).

Discussion

Currently, the majority of robotic surgeons favour leaving to heal by secondary intention the oropharyngeal defects following TORS for early OPSCC (cT1-2). However, the resection of smaller tumours involving the soft palate may result in velopharyngeal insufficiency. In fact, surgical resection inevitably affects the native function of the oropharynx; therefore, our group advocates the use of NBI in order to obtain free margins and to reduce over-resections, consequently minimising the risk of functional impairments [5].

Among existing classification schemes for oropharyngeal defects, the reconstructive algorithm developed by de Almeida et al. [6] seems to be easier to apply in the robotic surgery framework. Local flap or regional flaps are amenable for class I/II defects. In exclusive resection of the soft palate , the restoration of the velopharyngeal competency may be obtained with a posteromedially based musculomucosal flap (PMM) [6] as well as with a facial artery musculomucosal flap (FAMM) [7 8] . Theoretically, the combination of PMM and FAMM might provide a valuable solution in concomitant non-extensive lateral pharyngeal wall and soft palate defects.

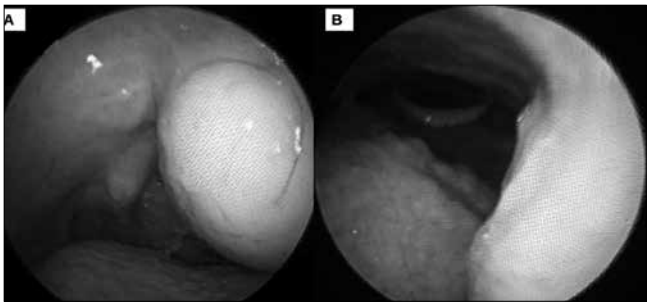

Fig. 5. Endoscopic view of insetted antero-lateral thigh flap. **A)** anterior view; **B)** retropalatal view.

An interesting application of the nasoseptal flap in covering tonsillar fossa resection is described by Pinheiro et al [9]. This flap may be considered a valid option either alone or in combination with previously described local flaps.

Regarding the BOT, our group advocates healing by secondary intention even in T3 tumours according to our experience in sleep apnoea robotic surgery [10]. Furthermore, extensive BOT resections did not lead to swallowing disorders in the post-operative course. Our experience is in accordance with de Almeida et al [6]. Obviously, in the case of the resection involving an extensive deeper muscular part of the tongue, restoration of bulk is needed and often requires soft tissue free flaps, although an infrahyoid flap may be a valuable option [11].

Class III/IV defects constitute a variable challenge for an effective functional reconstruction. Recent studies continue to demonstrate favourable functional outcomes following free tissue transfer [7 12-17], although in the vessel-depleted neck or in the presence of severe comorbidities flap failures are noted to be higher given the quality of the recipient vessels.

The radial forearm free flap (RFFF) and the ALT are the two types of reconstruction most commonly used for pharyngeal defects after TORS [7 12-17]. Perhaps the easiest of these flaps to harvest is the RFFF. However, the possibility of resulting in a reduction in dexterity and hand's grip strength of the donor's arm should be explained and discussed with the patient.

Many recent studies have been published that support an expanding role for the ALT for use in reconstruction of large pharyngeal defects [7 14 17]. In our experience (see Table I), we used the ALT for reconstructing class IV defects involving part of BOT and thoroughly the soft palate harvesting the skin paddle with a three petal shape (Fig. 4). This strategy has been described by Caliceti et al. [18] insetting the flap after transmandibular approaches. This particular shape allows one petal to replace the rear side of the palate, one for the front side of the palate and the tonsillar fossa and the third petal to reconstruct the tongue base. The dimensions of the template can be adjusted to the resected specimen before starting the flap dissection in order to optimise the precision. Flap insetting is the most challenging phase due to severely restricted physical access and visualisation. However, in our experience, the accurate shape and measure of the flap allow to thoroughly perform a manual inset, although the robot might be used for suturing parts of flap in deeper and narrower spaces. We strongly suggest to achieve the best exposure as much as possible (even modifying the position of the mouth gag after resection) and to start suturing the posterior wall between nasopharyngeal mucosa and the rear surface of the new palate (1st petal). Next, the flap is folded onto itself and sutured to the mucosa of the anterior face of the palate and the lateral pharyngeal wall (2nd petal), and the third petal is sutured to the tongue base (Fig. 4). In case of expected excessive bulky of ALT, Ghanem suggested to use the vastus lateralis free flap (VLFF) [16]. This flap might be used as rescue option in case of accidental damage of ALT perforator arteries.

Table I. Overview of published studies on oropharyngeal reconstruction in TORS framework and our experience.

Author	Year	Tumour site (T classification)	Flap	Complication
Selber et al. [7]	2010	1 RMT involving tonsil, BOT, soft palate	1 RFFF	-
		1 tonsil (T2)	1 FAMM	
Garfein et al. [13]	2011	1 BOT	1 RFFF	-
Ghanem [15]	2011	1 tonsil (T2) 1 BOT/oral tongue (T1) 1 tonsil, BOT, oral tongue (T4a)	3 RFFF	-
		1 tonsil (T4a)	1 vastus lateralis free flap	
Genden et al. [16]	2011	6 lateral pharyngeal wall involving BOT and soft palate	6 RFFF	1 partial flap necrosis
Bonawitz & Duvuuri [8]	2013	5 soft palate	5 FAMM	-
Park et al. [14]	2013	1 soft palate (T3)	1 ALT	-
		1 tonsil (T2)	1 RFFF	
Mukhija et al. [12]	2016	1 soft palate and tonsillar fossa (T3) 1 soft palate, lateralpharyngeal wall, RMT (T3)	2 RFFF	-
Pinheiro et al. [9]	2016	1 tonsil	1 nasoseptal flap	-
Forlì experience	-	2 lateral pharyngeal wall involving BOT and soft palate (T3)	2 ALT	-
		1 anterior tonsillar pillar involving soft palate (T2)	1 TMF	

RFFF: radial forearm free flap; ALT: antero-lateral thigh flap; TMF: temporalis muscle flap; FAMM: facial artery musculomucosal flap; BOT: Base of Tongue; FOM: Floor Of Mouth; RMT: Retro Molar Trigone

In the free flap era, regional flaps are often overlooked albeit they still represent a valid alternative especially in patients with severe comorbidities or vessels-depleted necks. In terms of cost-effectiveness, the use of alternative pedicled flaps in TORS framework probably reduce the risks of postoperative complications, with consequent expenditure restraints and reducing treatment costs arising from operating room duration and a double surgical team [19 20]. Our group successfully adopted the TMF restoring a competent velopharyngeal sphincter and a watertight seal between the pharynx and neck in a case of OPSCC involving part of soft palate and the anterior tonsillar pillar [21].

From the therapeutic point of view, TORS may be a valuable method of de-intensification for the locoregionally advanced patient in at least three ways: (1) decreasing the dose of radiotherapy; (2) obviating the need for chemotherapy; (3) decreasing the radiotherapy target volume [3]. Concurrent neck dissection allows to stage the lymph node involvement, and consequently to determine laterality of adjuvant radiotherapy without increasing risks of complications or delaying the adjuvant treatments [22]. Percutaneous endoscopic gastrostomy (PEG) tube dependency rates are important data that reflect on the toxicity of adjuvant treatment, functional outcomes and quality of life. Published rates of acute PEG tube dependence after definitive CRT range from 9% to 39% with median time to PEG tube removal ranging from 3.3 to 5.9 months and up to 37% of patients still PEG tube dependent at 1 year. Albeit the PEG tube insertion rate is almost similar after TORS, the dependency rate at one year is reported around 1% [2].

Conclusions

The introduction of TORS has led to a resurgence in the role of surgery in the management of patients with OPSCC. The available reconstructive options allow an expanding role of this minimally invasive surgery, even in locally advanced tumours. Given the rapidly increasing application of robotic surgery in the treatment of OPSCC, prospective comparisons of TORS versus CRT are critical to resolve the pressing clinical and cost-effectiveness issues in this disease.

Conflict of interest statement

None declared.

References

1. Sher DJ, Fidler MJ, Tishler RB, et al. *Cost-effectiveness analysis of chemoradiation therapy versus transoral robotic surgery for human papillomavirus-associated, clinical N2 oropharyngeal cancer*. Int J Radiat Oncol Biol Phys 2016;94:512–22.
2. Carpenter TJ, Kann B, Buckstein MH, et al. *Tolerability, toxicity, and temporal implications of transoral robotic surgery (TORS) on adjuvant radiation therapy in carcinoma of the head and neck.* Ann Otol Rhinol Laryngol 2014;123:791-7.
3. Ward MC, Koyfman SA. *Transoral robotic surgery: the radiation oncologist's perspective.* Oral Oncol 2016;60:96-102.
4. Pfister DG, Ang KK, Brizel DM, et al. *Head and neck cancers, version 2*.2013. Featured update to the NCCN guidelines. J Natl Comp Canc Netw 2013;11:917-23. Erratum in: J Natl Compr Canc Netw 2013;11:1458.
5. Vicini C, Montevecchi F, D'Agostino G, et al. *A novel approach emphasising intra-operative superficial margin enhancement of head-neck tumours with narrow-band imaging in transoral robotic surgery.* Acta Otorhinolaryngol Ital 2015;35:157-61.
6. de Almeida JR, Park RCW, Villanueva NL, et al. *Reconstructive algorithm and classification system for transoral oropharyngeal defects.* Head Neck 2014;36:934-41.
7. Selber JC. *Transoral robotic reconstruction of oropharyngeal defects: a case series.* Reconstr Surg 2010;126:1978-87.
8. Bonawitz SC, Duvvuri U. *Robotic-assisted FAMM flap for soft palate reconstruction.* Laryngoscope 2013;123:870-4.
9. Pinheiro CD, Galati LT. *Nasoseptal flap for reconstruction after radical tonsillectomy.* Head Neck 2016;38:E2495-8.
10. Eesa M, Montevecchi F, Hendawy E, et al. *Swallowing outcome after TORS for sleep apnea: short- and long-term evaluation.* Eur Arch Otorhinolaryngol 2015;272:1537-41.
11. Perrenot C, Phulpin B, Mastronicola R, et al. *Infrahyoid myocutaneous flap for reconstruction after robotic transoral surgery for oropharyngeal tumors.* Plast Reconstr Surg 2014;133:236e-7e.
12. Mukhija VK, Sung C-K, Desai SC, et al. *Transoral robotic assisted free flap reconstruction.* Otolaryngol Head Neck Surg 2016;140:124-5.
13. Garfein ES, Greaney PJ, Easterlin B, et al. *Transoral robotic reconstructive surgery reconstruction of a tongue base defect with a radial forearm flap.* Plast Reconstr Surg 2011;127:2352-4.
14. Park YM, Lee WJ, Yun IS, et al. *Free flap reconstruction after robot-assisted neck dissection via a modified face-lift or retroauricular approach*. Ann Surg Oncol 2013;20:891-8.
15. Ghanem TA. *Transoral robotic-assisted microvascular reconstruction of the oropharynx*. Laryngoscope 2011;121:580-2.
16. Genden EM, Park R, Smith C, et al. *The role of reconstruction for transoral robotic pharyngectomy and concomitant neck dissection*. Arch Otolaryngol Head Neck Surg 2011;137:151-6.
17. Meccariello G, Montevecchi F, Sgarzani R, et al. *The reconstructive options for oropharyngeal defects in the transoral robotic surgery framework*. Oral Oncol 2017;66:108-11.

[18] Caliceti U, Piccin O, Sgarzani R, et al. *Surgical strategies based on standard templates for microsurgical reconstruction of oral cavity and oropharynx soft tissue: A 20 years' experience.* Microsurgery 2013;33:90-104.

[19] Deganello A, Gitti G, Parrinello G, et al. *Cost analysis in oral cavity and oropharyngeal reconstructions with microvascular and pedicled flaps.* Acta Otorhinolaryngol Ital 2013;33:380-7.

[20] Montevecchi F, Cammaroto G, Meccariello G et al. *Transoral robotic surgery (TORS): a new tool for high risk tracheostomy decannulation*. Acta Otorhinolaryngol Ital 2017;37:46-50.

[21] Meccariello G, Montevecchi F, Deganello A et al. *The temporalis muscle flap for reconstruction of soft palate and lateral oropharyngeal wall after transoral robotic surgery.* Auris Nasus Larynx 2018;45:162-4.

[22] Kucur C, Durmus K, Gun R, et al. *The safety and efficacy of concurrent neck dissection and transoral robotic surgery.* Head Neck 2015;38:E519-2.

Received: October 24, 2016 - Accepted: June 6, 2017

Address for correspondence: Filippo Montevecchi, Department of Head-Neck Surgery, Otolaryngology, Head-Neck and Oral Surgery Unit, Morgagni Pierantoni Hospital, Azienda USL della Romagna, viale Forlanini 34, 47100 Forlì, Italy. Tel. +39 0543 735651. Fax +39 0543 735660. E-mail: filippomontevecchi72@gmail.com