

CASE REPORT

Otosclerosis associated with type B-1 inner ear malformation

Otosclerosi associata a malformazione dell'orecchio interno tipo B-1

A. DE STEFANO ^{1,2}, F. DISPENZA ^{1,3}, N. AGGARWAL ^{1,4}, A. RUSSO ¹

¹ "Gruppo Otologico Piacenza-Roma", Italy; ² Institute of Otorhinolaryngology, University "G. d'Annunzio", Chieti-Pescara, Italy; ³ Institute of Otorhinolaryngology, University of Palermo, Italy; ⁴ ENT Institute, Sir Ganga Ram Hospital, New Delhi, India

SUMMARY

Malformations of bony inner ear are rare anomalies occurring in approximately 20% of patients with congenital sensorineural hearing loss. Conductive hearing loss is usually associated with abnormalities of the external and middle ear. Recent reports of patients with lateral semicircular canal malformations indicate inner ear malformations to be associated with sensorineural or conductive hearing loss. Differential diagnosis of conductive hearing loss should include otosclerosis, isolated ossicular deformities, inner ear anomalies or a combination of these. In this report, a case is described with right vestibule-lateral semicircular canal dysplasia presenting at our centre with bilateral otosclerosis.

KEY WORDS: Inner ear malformation • Otosclerosis • Conductive hearing loss • Lateral semicircular canal dysplasia • Stapedotomy

RIASSUNTO

Le malformazioni ossee dell'orecchio interno sono rare anomalie che si verificano in circa il 20% dei pazienti con ipoacusia neurosensoriale congenita. La perdita trasmissiva dell'udito è solitamente associata con le anomalie dell'orecchio esterno e medio, tuttavia studi recenti su pazienti affetti da malformazioni del canale semicircolare laterale indicano che le anomalie dell'orecchio interno possono associarsi a perdite dell'udito non solo neurosensoriali ma anche trasmissive. La diagnosi differenziale delle ipoacusie trasmissive, quindi, dovrebbe includere sicuramente l'otosclerosi e le deformità isolate ossiccolari ma anche le anomalie dell'orecchio interno o una combinazione di entrambi questi fattori. In questo studio presentiamo un caso di displasia del vestibolo e del canale semicircolare destro associata ad otosclerosi bilaterale.

PAROLE CHIAVE: Malformazioni dell'orecchio interno • Otosclerosi • Ipoacusia trasmissiva • Displasia del canale semicircolare laterale • Stapedotomia

Acta Otorhinolaryngol Ital 2009;29: EPUB 19 January

Introduction

Malformations of bony inner ear are rare anomalies occurring in approximately 20% of patients with congenital sensorineural hearing loss (SNHL) ¹. Conductive hearing loss (CHL) is usually associated with abnormalities of the external and middle ear ² as both bear a common embryonic origin from the first and second branchial arches ³. Malformations of the inner ear result from an arrest of maturation during one of the stages of inner ear embryogenesis ^{4,5}. Developmental malformations of the bony inner ear are best evaluated on computerized tomography (CT). Several Authors have classified the anomalies based on the radiological anatomy and embryogenesis of the inner ear ^{1,6,7}. Recent reports of patients with lateral semicircular canal (LSC) malformations indicate inner ear malformations to be associated with SNHL and/or CHL ². Other inner ear malformations, such as large vestibular aqueduct syn-

drome and X linked mixed deafness with perilymph gusher, may also present with SNHL or CHL ⁸.

Clinically, a normal otoscopic examination with conductive loss should include a differential diagnosis of otosclerosis, isolated ossicular deformities, inner ear anomalies or a combination of these ². LSC dysplasia is the most common inner ear malformation ⁹. This may occur in isolation or be associated with middle ear, cochlear, or vestibular malformations.

In this report, the case is described of a patient with right vestibule-LSC dysplasia presenting at our centre with bilateral CHL.

Case report

A 39-year-old female presented with a 2-year history of progressively worsening right-sided hearing loss. There were no associated complaints of otorrhoea, tinnitus, ver-

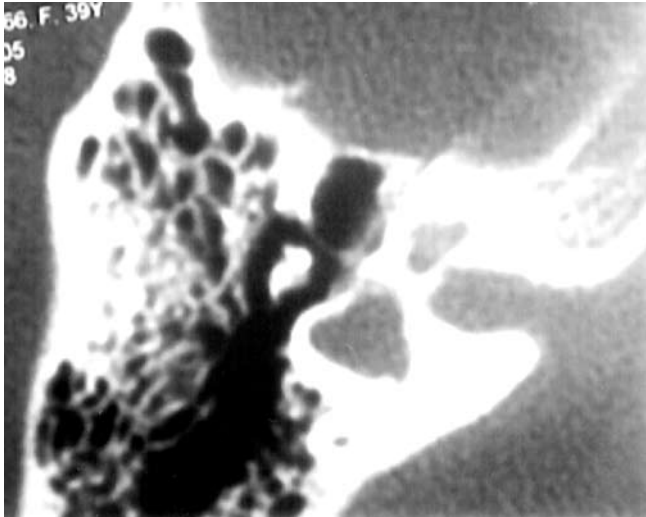


Fig. 1. Axial CT section of right ear showing LSC-vestibule dysplasia (Type B-1 malformation).

tigo/imbalance, facial weakness or trauma. A positive family history of otosclerosis (father and brother) existed. Clinically otoscopic findings were normal. On audiometric assessment, Pure Tone Audiometry (PTA) showed a right CHL (air-bone gap 35 dB) and an initial air-bone gap of 10 dB for lower frequencies (250 Hz, 500 Hz), on left side. Speech discrimination score was 100% on left side and 80% on right side with bilaterally absent stapedial reflex (ipsi - contra). A provisional diagnosis of otosclerosis was made. However, a high resolution CT scan of temporal bone, performed 6 months prior to her visit at our Centre, incidentally showed a malformation of the right inner ear. Both axial and coronal sections, on the right side, showed the vestibule to be enlarged and forming a common cavity with a dysplastic LSC (Fig. 1). The superior vestibular nerve canal was also enlarged (Fig. 2). The superior and posterior semicircular canals, cochlea and the internal auditory canal were normal. There was

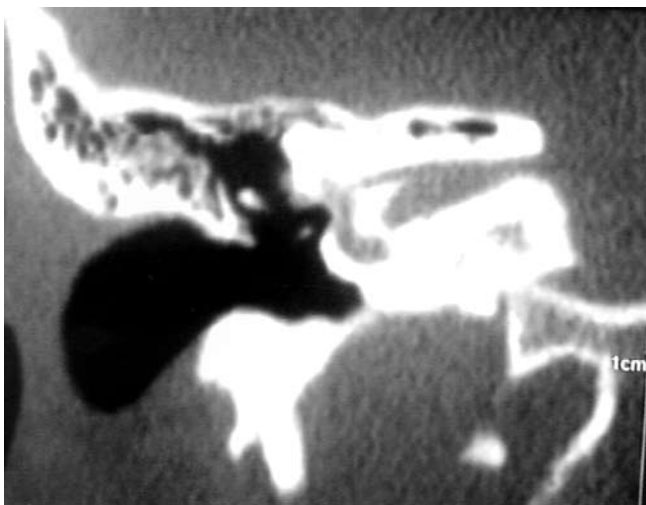


Fig. 2. Axial CT section of right ear showing superior vestibular nerve canal enlarged.

no radiological evidence of any malformation on the left side. Consequently, the radiological findings on CT contraindicated any surgery for otosclerosis because of a severe risk of hearing loss or gusher.

Discussion

Malformations of the inner ear are present in about 20% of the cases with congenital SNHL¹. In the remaining 80%, the condition exists at a cellular level with membranous anomalies and normal bony structures of the inner ear¹⁰. Usually, patients with CHL require appropriate investigations to exclude external or middle ear disease. However, recent studies have indicated that CHL is associated with inner ear anomalies. Johnson and Lalwani demonstrated that CHL is often present in LSC malformations². Karlberg et al. suggested Mondini-like cochlear dysplasia to be a cause of inner ear CHL¹¹. Superior semicircular canal dehiscence may present as CHL with or without vertigo and normal stapedial reflex¹²⁻¹⁴. Air-bone gap has been reported in the enlarged vestibular aqueduct syndrome¹⁵. Dysplasia of the inner ear may be inherited, sporadic or the result of chromosomal aberrations¹⁶ and results from an arrest of maturation during one of the stages of inner ear embryogenesis^{4,5}. Labyrinthine malformation presumably occurs due to an interruption in differentiation between the fifth and sixth weeks of foetal development¹⁶. The LSC, which is the inner ear structure most frequently found to be malformed, may be particularly vulnerable due to its late stage of formation¹. Inner ear malformations may occur isolated or as a part of a syndrome. This variability in presentation makes diagnosis and treatment difficult.

This case report highlights an isolated unilateral malformation of the vestibule and LSC forming a common dysplastic cavity associated with CHL. This is in agreement with the classification of Jackler et al.¹ of inner ear malformations, Vestibule-LSC dysplasia type B1. In type B1, the cochlea appears normal but the vestibule is enlarged with a short and dilated LSC. The remaining semicircular canals are normal. On audiometric assessment, these anomalies show an air-bone gap¹.

In the present case report, a family history of otosclerosis, normal otoscopic findings, air-bone gap on audiometry and bilaterally absent stapedial reflex, were typical of otosclerosis and thus stapedotomy was initially hypothesised as the primary treatment.

However, as CT findings of the temporal bone showed malformation of the right inner ear, it was decided not to perform any surgical intervention as it carried a substantial risk of an intra-operative gusher and post-operative hearing loss. In inner ear anomalies, surgery for otosclerosis carries a severe risk of gusher¹⁷ as it is well recognized that congenital dysplasias provide a potential communication between the subarachnoid space and middle ear cavity¹⁸.

Gusher is a very rare phenomenon associated with stapes

fixation in children or otosclerosis in adults¹⁹. This atypical anomaly, at times, presents as rhinorrhoea (cerebrospinal fluid) associated with recurrent meningitis or otorrhoea in the presence of a perforated tympanic membrane. However, it may often remain unobserved and asymptomatic for a long period. Thus the absence of definitive signs, prior to surgery for otosclerosis, makes it difficult to conclusively diagnose an impending gusher.

Intra-operatively, following stapedotomy, peri-lymphatic fluid gushes out under high pressure resulting in incomplete surgical treatment²⁰. Consequences are severe, as it exposes the patient to risk of recurrent meningitis and hearing loss.

Conclusions

This case report highlights the presence of bilateral otosclerosis with unilateral inner ear malformation. In-

creased conductive hearing loss, unilaterally, may reflect an enhanced otosclerotic process on the affected side or a combination of a hearing deficit due both to otosclerosis and inner ear malformation. It is possible that onset of otosclerosis, in the present case, led to worsening of an already existing hearing loss on the right side that had remained unnoticed because of good hearing on the other side. Radiological evidence of the inner ear malformation was revealed on a chanced CT, as, in the normal course of events, we do not advocate radiological evaluation for patients suspected of having otosclerosis. These patients are at high risk of gusher and/or hearing loss, if surgery is performed²¹. We do not advocate surgery for these patients on account of the associated risks. Pre-operative CT of otosclerosis, is still debatable, in all patients, considering the rarity of inner ear malformations and the elevated cost of the procedure.

References

- 1 Jackler RK, Luxford WM, House WF. *Congenital malformation of the inner ear: A classification based on embryogenesis*. Laryngoscope 1987;97(Suppl. 40):2-14.
- 2 Johnson J, Lalwani AK. *Sensorineural and Conductive Hearing Loss associated with lateral semicircular canal malformation*. Laryngoscope 2000;110:1673-9.
- 3 O'Rahilly R. *The early development of the otic vesicle in staged human embryos*. J Embryol Exp Morphol 1963;11:741-55.
- 4 Schuknecht HF. *Dysmorphogenesis of the inner ear*. Birth Defects Orig Artic Ser 1980;16:47-71.
- 5 Streeter GL. *On the development of the membranous labyrinth and the acoustic and facial nerves in the human embryo*. Am J Anat 1906;6:139-65.
- 6 Nager GT, Hyams VJ. *Dysplasia of the osseous and membranous cochlea and vestibular labyrinth*. In: *Pathology of the ear and temporal bone*. Baltimore: Williams & Wilkins; 1993. p. 119-43.
- 7 Marangos N, Aschendorff A. *Congenital deformities of the ear: classification and aspect regarding cochlear implant surgery*. Adv Otorhinolaryngol 1997;52:52-6.
- 8 Nance WE, Setleff R, McLeod A, Sweeney A, Cooper C, McConnel F. *X-linked mixed deafness with congenital fixation of the stapedial footplate and perilymphatic gusher*. Birth Defect Orig Artic Ser 1971;7:64-9.
- 9 Sando I, Takahara T, Ogawa A. *Congenital anomalies of the inner ear*. Ann Otol Rhinol Laryngol Suppl 1984;112:110-8.
- 10 Sennaroglu L, Saatci I. *A new classification for cochleovestibular malformation*. Laryngoscope 2002;112:2230-41.
- 11 Karlberg M, Annertz M, Magnusson M. *Mondini-like malformation mimicking otosclerosis and superior semicircular canal dehiscence*. J Laryngol Otol 2006;120:419-22.
- 12 Mikulec AA, McKenna MJ, Ramsy MJ, Rosowski JJ, Herrmann BS, Curtin HD, et al. *Superior semicircular canal dehiscence presenting as conductive hearing loss without vertigo*. Otol Neurotol 2004;25:121-9.
- 13 Cox KM, Lee DJ, Carey JP, Minor LB. *Dehiscence of bone overlying the superior semicircular canal as cause of an air-bone gap on audiometry: a case study*. Am J Audiol 2003;12:11-6.
- 14 Minor LB. *Clinical manifestations of superior semicircular canal dehiscence*. Laryngoscope 2005;115:1717-27.
- 15 Mimura T, Sato E, Sugiura M, Yoshino T, Naganawa S, Nakashima T. *Hearing loss in patients with enlarged vestibular aqueduct: air-bone gap and audiological Bing test*. Int J Audiol 2005;44:466-9.
- 16 Schuknecht HF. *Pathology of the ear*. 2nd edn. Philadelphia: Lea and Febiger; 1993.
- 17 Causse J, Causse JB. *Eighteen-year report on stapedectomy. I: Problems of stapedial fixation*. Clin Otolaryngol 1980;5:49-59.
- 18 Phelps PD, King A, Michaels L. *Cochlear dysplasia and meningitis*. Am J Otol 1994;15:551-7.
- 19 Dornhoffer JL, Helms J, Hoehmann DH. *Stapedectomy for congenital fixation of the stapes*. Am J Otol 1995;16:382-6.
- 20 Couvreur P, Baltazart B, Lacher G, Filippini JF, Vincey P. *Perilymphatic effusion as a complication of otosclerosis*. Rev Laryngol Otol Rhinol 2003;124:31-7.
- 21 Sanna M, Sunose H, Mancini F, Russo A, Taibah A, editors. *Middle ear and mastoid microsurgery*. Stuttgart: Thieme; 2003.

Received: February 2, 2009 - Accepted: April 01, 2009

Address for correspondence: Dr. A. De Stefano, via Di Palma 10, 74100 Taranto, Italy. E-mail: dr.arestefano@gmail.com