

CASE REPORT

Late diagnosis of a solitary fibrous tumour of the parapharyngeal space in a continuous positive airway pressure-treated patient

Diagnosi tardiva di un tumore fibroso solitario parafaringeo in un paziente in terapia con CPAP

C. PIPOLO, A. MACCARI, F. MESSINA, L. MENEGHINI¹, G. FELISATI

Head and Neck Department; ¹Anatomopathology Department, San Paolo Hospital, University of Milan, Milan, Italy

SUMMARY

Solitary fibrous tumours of the parapharyngeal space are a very rare finding and have been described less than 10 times in the English literature. The Authors discuss a clinical case of a solitary fibrous tumour in the parapharyngeal space in a 77-year-old male, who had begun treatment for a newly discovered obstructive sleep apnoea syndrome with a continuous positive airway pressure – device one year prior to diagnosis. This rare location of an uncommon lesion often gives rise to difficulty in diagnosis or to misdiagnosis and the Authors, therefore, made a review of the scientific literature and analysed the diagnostic and therapeutic procedures used. The importance of this report lies mainly in two aspects: on the one hand, the discussion concerning the diagnostic and therapeutic procedures and on the other, the need of a thorough evaluation in obstructive sleep apnoea syndrome patients before treating them with a chronic device like the continuous positive airway pressure device.

KEY WORDS: Parapharyngeal space tumour • Solitary fibrous tumour • CPAP

RIASSUNTO

Il tumore fibroso solitario dello spazio parafaringeo rappresenta un evento molto raro descritto nella letteratura inglese in meno di dieci casi complessivi. Gli Autori discutono il caso clinico di un paziente di 77 anni con una diagnosi di sindrome delle apnee ostruttive del sonno, trattata da circa un anno con apparecchio notturno di respirazione sotto pressione positiva, e rivelatosi affetto da un tumore fibroso solitario dello spazio parafaringeo. Il caso, per le sue caratteristiche di rarità clinica e di difficoltà diagnostica, che hanno portato ad un inquadramento molto tardivo, si presta per una analisi della letteratura scientifica volta a definire le più corrette procedure diagnostiche e terapeutiche. Scopo di questo report è anche sottolineare la necessità di uno studio approfondito di tutti i pazienti con sindrome delle apnee ostruttive del sonno volto ad una precisazione diagnostica prima del loro trattamento con uno strumento "cronico" come lo è l'apparecchio di respirazione sotto pressione positiva.

PAROLE CHIAVE: Tumore parafaringeo • Tumore fibroso solitario • CPAP

Acta Otorhinolaryngol Ital 2009;29: EPUB 19 January

Introduction

Tumours of the parapharyngeal space (PPS) are uncommon, representing 0.5-1% of all head and neck neoplasms ¹. Approximately, 70-80% of PPS tumours are benign whereas 20-30% are malignant ². Most are neurogenic, paragangliomas or derive from the salivary glands or the lympho-reticular tissue. The remainder include a wide variety of lesions, comprising the solitary fibrous tumour (SFT). To our knowledge, fewer than 10 cases of a SFT, in this region, have been described in the English literature and this is the first case of a SFT

presenting with an obstructive sleep apnoea syndrome (OSAS).

The SFT is an uncommon neoplasm that usually arises from the pleura and peritoneum. However, as shown by well documented examples of SFTs in soft tissues ³⁻⁸, it is now known that this tumour is quite ubiquitous and can be found wherever mesenchymal tissue is located ⁹. Most tumours, in the peripheral soft tissue, are found in the subcutis, others are located in the deep soft tissues of extremities and the head and neck.

Microscopically, the most characteristic features are the alternation of hyper-cellular and hypo-cellular areas, the

deposition of dense bundles of collagen and the occurrence of a haemangiopericytoma (HPC)-like vascular pattern, at least focally¹⁰.

Immunohistochemically, tumour cells in SFTs are typically uniformly positive for CD34. Many cases are also variably positive for bcl-2 and CD99¹¹.

In most cases, as well as in our case, the diagnosis of a SFT is not made until the excised tumour is submitted to histopathology and immunohistochemistry investigations¹². In this article, a clinical case of a parapharyngeal SFT, in a 77-year-old male patient, is discussed.

Clinical case

A 77-year-old male, with a one-year history of CPAP-treated OSAS, was referred to our clinic for the study of a large laterocervical mass, dysphagia and respiratory insufficiency. A physical examination showed a firm, mobile mass anterior to the sternocleidomastoid muscle and almost complete closure of the hypopharynx with an integral mucosa.

Consequently, a computerized tomography (CT) scan of the neck was performed which showed a lesion 9.5 x 13.5 x 4.7 cm in size extending from the rhino-pharyngeal region to the thyroid and the left para-oesophageal region; causing almost complete dislocation and compression of the hypopharynx (Fig. 1). Two subsequent Fine Needle Aspirations were not successful in defining the cytology of the lesion.

A magnetic resonance could not be performed due to the patient's pacemaker.

Tracheostomy was performed under local anaesthesia to secure the airway; then, under general anaesthesia, a transcervical incision was made to access the mass. The latter was approached after ligation of the superior thyroid artery which lay on top of the capsulated mass. The next step was blunt dissection of the mass from the sternocleidomastoid muscle, which together with the vascular-neural bundle had been dislocated postero-laterally by the tumour (Fig. 2).

The tumour was then digitally freed from the pre-vertebral region allowing its complete detachment and removal *in toto* (Fig. 3). The resected specimen was then measured (Fig. 4).

Primary reconstruction of the neck was performed and the post-operative period was free of complications.

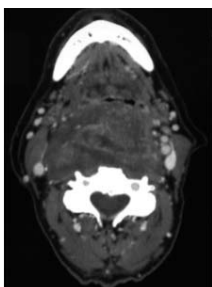


Fig. 1. CT finding: subtotal obstruction of upper airways.

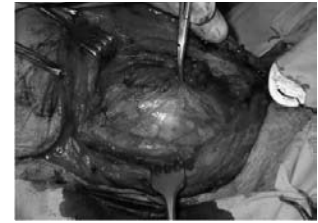


Fig. 2. Appearance of surgical field after ligation of superior thyroid artery. Neuro-vascular bundle displaced postero-laterally.

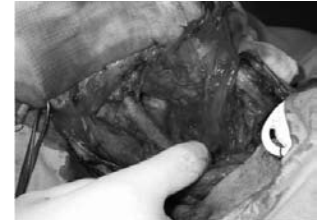


Fig. 3. Surgical field after exposure and removal of the mass, showing paravertebral space.

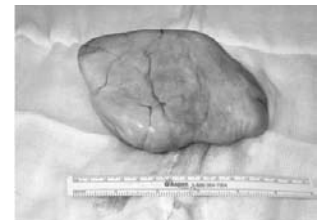

Fig. 4. Specimen: 13.8 x 10 x 4.4 cm.

After surgery, the patient had no further need for the tracheostomy tube, which was removed after 5 days.

Evaluation of his sleep apnoea was carried out 20 days after surgery (15 days after closure of the tracheostomy) and compared with his results prior to polysomnographic investigations. His oxygen desaturation index (ODI; the number of desaturation events equal or more than 4%/h) at polysomnography, one year prior to the surgery, scored 63; 20 days after removal of the mass, the ODI was 0, whereas the apnoea-hypopnoea index/h (AHI/h) values were 51 and 2.2, respectively. Given these values, it was decided that the patient had no further need for the CPAP device. A follow-up polysomnography, 12 months later, confirmed the results.

Macroscopically, the specimen presented as an oval mass which during sectioning appeared solid, yellowish and inhomogeneous.

The microscopic examination revealed a mesenchymal proliferation with a hypocellulated external area equal to 30% of the mass and a central part with high cellularity, cellular pleomorphism, necrotic areas and a mitotic rate of 5/10 (10 high power field – HPF, 40x).

Immunohistochemically the cells were uniformly positive for CD34, Bcl-2 and occasionally positive for CD117(c-kit) and CD99. Instead, there was no reactivity to smooth-muscle actin, specific muscle actin, desmin, S-100 protein and cytocheratin pool.

The morphologic and immunohistochemical features of this mass were, therefore, highly consistent with the diagnosis of SFT of the parapharyngeal space

The decision of a watchful follow-up was reached after careful evaluation of the literature on SFTs and the histological assessment of the surgical margins, which were free of neoplasia.

Discussion

Parapharyngeal space tumours, in this case a SFT, are an infrequent entity and because of their mostly benign characteristics are difficult to diagnose in the early stage. The first symptom, in our patient, was obviously his need for a CPAP device, more than a year prior to diagnosis. The attentive examination and the interest concerning the origin of this patient's sudden onset of symptoms could have prevented the late diagnosis or at least the late referral to an ENT specialist in this case of OSAS. Imaging is certainly essential for defining the site and extension of the mass. In particular, FDG positron emission tomography (PET) could be a crucial component in the initial evaluation of patients with solitary neck masses as described by Wakisaka et al.¹³ because it offers useful information indicating the nature of the tumour. Cytology can help to define the origin of the lesions but tumours of the parapharyngeal space are frequently deep and it is generally very difficult to perform a correct or at least positive fine needle aspiration. In very selected cases, biopsy specimens of a neoplasm penetrating the pterygopalatine fossa, corresponding to the posterior maxillary sinus wall, may be taken under endoscopic control through the maxillary sinus.

Imaging and cytology together contributed to ruling out a number of pathological conditions that could have impaired the airway in such a significant way as to lead to a severe form of OSAS, including malignant neoplasms, for example, lymphomas, metastases and benign cystic neoplasms like brachial cysts, etc. but could not, previously have excluded well capsulated neoplasms like neurinomas, etc.

Surgical treatment

Parapharyngeal space tumours are often considered very difficult to approach surgically due to the restricted access area and their frequent spreading into adjoining spaces, often as dumbbell tumours. Many different approaches have been proposed for the surgical control of these neoplasms which differ in relation to the involvement of the parapharyngeal space, and their expansion towards the

neck area. The laterocervical approach, with or without mandibulotomy, is the treatment of choice in caudally originating and expanding tumours and does not represent a true surgical challenge. Instead, for the tumours with a cranial extension towards the infra-temporal space, a more complicated approach has to be adopted. In these cases, caudal access, as described by Bozzetti et al.¹⁴, with a double mandibulotomy resection or the trans-zygomatic approach for cranial access, as illustrated by Terasaka et al.¹⁵, are methods of choice for these areas which are more difficult to reach. Other approaches, worthwhile mentioning, are the transcervical-transparotid¹⁶ approach for tumours of the PPS originating in the deep lobe of the parotid gland and the orbitozygomatic-middle fossa approach as described by Fisch¹⁷ for large tumours of the PPS that involve the temporal bone.

In the case described here, the surgical approach used was adequate to remove the tumour and remain in control of the whole lesion, since the tumour originated from the lower post-styloid-retropharyngeal space and its elastic consistency prevented the capsule from rupturing during extraction.

Conclusions

After surgical treatment, although solitary fibrous tumours tend to behave in a benign manner, the follow-up of patients is mandatory since there are reports of cases in the literature describing the development of recurrent disease with malignant characteristics, even up to 6 years after excision⁵. There are also rare cases with sudden transition from conventional benign-appearing SFT to overtly high grade sarcoma¹⁰.

The frequency of follow-up examinations does not vary according to the tumour histology, which gives us only an indication regarding its malignant potential. These indicators include cellular pleomorphism, abnormal mitotic features and the presence of more than 4 mitoses per 10 high-power field¹⁸.

The behaviour of extra-thoracic SFTs remains unpredictable, entirely comparable to that of their better known pleural counterparts⁸ and, therefore, the radicality of the surgical resection remains the most important parameter for prognosis.

Thorough and careful evaluation of all patients with upper obstructive respiratory difficulties is mandatory in order to detect the less common neck neoplasms.

References

- 1 al Sinawi A, Johns AN. *Parapharyngeal solitary fibrous tumour: an incidental finding at ENT examination.* J Laryngol Otol 1994;108:344-7.
- 2 Attia A, El-Shafiey M, El-Shazly S, Shouman T, Zaky I. *Management of parapharyngeal space tumors at the Na-*

tional Cancer Institute, Egypt. J Egypt Natl Canc Inst 2004;16:34-42.

- 3 Hasegawa T, Hirose T, Seki K, Yang P, Sano T. *Solitary fibrous tumor of the soft tissue. An immunohistochemical and ultrastructural study.* Am J Clin Pathol 1996;106:325-31.
- 4 Morimitsu Y, Nakajima M, Hisaoka M, Hashimoto H. *Ex-*

- tripleural solitary fibrous tumor: clinicopathologic study of 17 cases and molecular analysis of the p53 pathway.* APMIS 2000;108:617-25.
- ⁵ Nielsen GP, O'Connell JX, Dickersin GR, Rosenberg AE. *Solitary fibrous tumor of soft tissue: a report of 15 cases, including 5 malignant examples with light microscopic, immunohistochemical, and ultrastructural data.* Med Pathol 1997;10:1028-37.
- ⁶ Safneck JR, Alguacil-García A, Dort JC, Phillips SM. *Solitary fibrous tumour: report of two new locations in the upper respiratory tract.* J Laryngol Otol 1993;107:252-6.
- ⁷ Shnayder Y, Greenfield BJ, Oweity T, DeLacure MD. *Malignant solitary fibrous tumor of the tongue.* Am J Otolaryngol 2003;24:246-9.
- ⁸ Vallat-Decouvelaere AV, Dry SM, Fletcher CD. *Atypical and malignant solitary fibrous tumors in extrathoracic locations: evidence of their comparability to intra-thoracic tumors.* Am J Surg Pathol 1998;22:1501-11.
- ⁹ Cizmarevic B, Lanisnik B, Didanovic V, Kavalar R. *Solitary fibrous tumor of the parapharyngeal space.* Wien Klin Wochenschr 2004;116(Suppl.2):68-71.
- ¹⁰ Bisceglia M, Spagnolo D, Galliani C, Fisher C, Suster S, Kazakov DV, et al. *Tumoral, quasitumoral and pseudo-tumoral lesions of the superficial and somatic soft tissue: new entities and new variants of old entities recorded during the last 25 years. Part XII: appendix.* Pathologica 2006;98:239-98.
- ¹¹ Cassarino DS, Auerbach A, Rushing EJ. *Widely invasive solitary fibrous tumor of the sphenoid sinus, cavernous sinus, and pituitary fossa.* Ann Diagn Pathol 2003;7:169-73.
- ¹² Gangopadhyay K, Taibah K, Manohar MB, Kfoury H. *Solitary fibrous tumor of the parapharyngeal space: a case report and review of the literature.* Ear Nose Throat J 1996; 75:681-4.
- ¹³ Wakisaka N, Kondo S, Murono S, Minato H, Furukawa M, Yoshizaki T. *A solitary fibrous tumor arising in the parapharyngeal space, with MRI and FDG-PET findings.* Auris Nasus Larynx 2009;36:367-71.
- ¹⁴ Bozzetti A, Biglioli F, Gianni AB, Brusati R. *Mandibulotomy for access to benign deep lobe parotid tumors with parapharyngeal extension: report of four cases.* J Oral Maxillofac Surg 1998;56:272-6.
- ¹⁵ Terasaka S, Sawamura Y, Goto S, Fukushima T. *A lateral transzygomatic-transtemporal approach to the infratemporal fossa: technical note for mobilization of the second and third branches of the trigeminal nerve.* Skull Base Surg 1999;9:277-87.
- ¹⁶ Attia EL, Bentley KC, Head T, Mulder D. *A new external approach to the pterygomaxillary fossa and parapharyngeal space.* Head Neck Surg 1984;6:884-91.
- ¹⁷ Fisch U. *Infratemporal fossa approach to tumours of the temporal bone and base of the skull.* J Laryngol Otol 1978;92:949-67.
- ¹⁸ Fine SW, McCarthy DM, Chan TY, Epstein JI, Argani P. *Malignant solitary fibrous tumor of the kidney: report of a case and comprehensive review of the literature.* Arch Pathol Lab Med 2006;130:857-61.

Received: January 15, 2009 - Accepted: July 26, 2009