ACTA Otorhinolaryngologica Italica

Official Journal of the Italian Society of Otorhinolaryngology Head and Neck Surgery

Organo Ufficiale della Società Italiana di Otorinolaringoiatria e Chirurgia Cervico-Facciale

Review

Brain abscess of odontogenic origin in children: a systematic review of the literature with emphasis on therapeutic aspects and a new case presentation

Head and neck

Trans-oral robotic surgery for the management of oropharyngeal carcinomas: a 9-year institutional experience

Long-term disease-free survival in surgically-resected oral tongue cancer: a 10-year retrospective study

Rhinology

Lateral osteotomy plus hump resection vs hump re-modeling without lateral osteotomy: impact on frontal nasal view

Evaluation of nasal symptoms in septoplasty patients using SNOT-22

Audiology

Right-to-left shunt and idiopathic sudden sensorineural hearing loss

Validation of the Chronic Tinnitus Acceptance Questionnaire (CTAQ-I): the Italian version

Maxillo facial and plastic surgery

Use of a CAD-CAM inferior alveolar nerve salvage template during mandibular resection for benign lesions

Otology

Canal wall down approach for tympano-mastoid cholesteatoma: long-term results and prognostic factors

Case series and reports

Internal carotid artery injury during endonasal sinus surgery: our experience and review of the literature

S.I.O.E.C.I.C.F.

PACINI EDITORE MEDICINA

Volume 39
April 2019

2

www.actaitalica.it

ACTA Otorhinolaryngologica Italica

Official Journal of the Italian Society of Otorhinolaryngology Head and Neck Surgery

Organo Ufficiale della Società Italiana di Otorinolaringoiatria e Chirurgia Cervico-Facciale

Former Editors-in-Chief:
C. Calearo, E. de Campora, A. Staffieri, M. Piemonte, F. Chiesa, G. Paludetti

Italian Scientific Board

M. Alicandri-Ciufelli
Policlinico, Modena
G. Bellocchi
Ospedale "San Camillo", Roma
A. Bertolin
Presidio Ospedaliero, Vittorio Veneto
F. Dispenza
Policlinico "Paolo Giaccone", Palermo
M. Falcioni
Azienda Ospedaliera, Parma
F. Fiorino
Ospedale "Mater Salutis", Legnago
J. Galli
Policlinico Gemelli, Roma
G. Giourgos
Ospedale "Papa Giovanni XXIII", Bergamo
A. Greco
Policlinico "Umberto I", Roma
G. Marioni
Azienda Ospedaliera, Padova
A. Murri
Ospedale "Guglielmo Da Saliceto", Piacenza
P. Petrone
Ospedale "San Giacomo", Monopoli
C. Piazza
Istituto Nazionale dei Tumori, Milano
N.A.A. Quaranta
Policlinico, Bari
R. Teggi
Ospedale "San Raffaele", Milano
D. Testa
Seconda Università, Napoli

International Scientific Board

J. Betka
Charles University, Prague Czech Republik
P. Clement
ENT Department,University Hospital, Brussels, Belgium
M. Pais Clemente
Department of Otolaryngology, University of Porto, Portugal
R.W. Gilbert
Otolaryngology H&N Surgery, University of Toronto, Canada
M. Halmagyi
Royal Prince Alfred Hospital, Camperdown, Australia
L.P. Kowalski
A C Camargo Cancer Center, Sao Paulo, Brazil
R. Laszig
Universitäts-HNO-Klinik, Freiburg, Germany
C.R. Leemans
VU University Medical Center, Amsterdam, The Netherlands
F. Marchal
Hopitaux Universitaires, Geneve, Switzerland
G. O'Donoghue
ENT Department, Queen's Medical Centre, Nottingham, UK
M. Remacle
CHL Clinique d'Eich, Luxembourg
R.J. Salvi
Center for Hearing and Deafness, Buffalo, NY, USA
B. Scola Yurrita
Hospital General Universitario G. Marañón, Madrid, Spain
J. Shah
Memorial Sloan Kettering Cancer Centrer, New York, USA
H. Stammberger
Medical University, Graz, Austria
H.P. Zenner
Universitäts Hals-Nasen-Ohren-Klinik, Tübingen, Germany

Editorial Board
Editor-in-Chief:
M. Ansarin
President of S.I.O.:
C. Vicini
Former Presidents of S.I.O.:
L. Coppo, A. Ottaviani, P. Puxeddu, M. Maurizi, G. Sperati, D. Passali, E. de Campora, A. Sartoris, P. Laudadio, M. De Benedetto, S. Conticello, D. Casolino, A. Rinaldi Ceroni, M. Piemonte, R. Fiorella, A. Camaioni, A. Serra, G. Spriano, R. Filipo, C.A. Leone, E. Cassandro

Editorial Staff
Editor-in-Chief:
M. Ansarin
Division of Otolaryngology Head & Neck Surgery
European Institute of Oncology
Via Ripamonti, 435
20141 Milan, Italy
Tel. +39 02 57489490
Fax +39 02 94379216
actaitalicaorl@ieo.it

Associate Editors:
E. De Corso
Fondazione Policlinico Universitario A. Gemelli IRCCS, Università Cattolica del Sacro Cuore, Roma, Italy
eugenio.decorso@policlinicogemelli.it

M.G. Rugiu
SOC ORL, Azienda Universitaria Integrata di Udine, Italy
mgrugiuactaorl@gmail.com

E. Zanoletti
Otorinolaringoiatria, Ospedale-Università di Padova, Italy
ezanolettiactaorl@gmail.com

Editorial Coordinator:
F. Chu
Division of Otolaryngology Head & Neck Surgery
European Institute of Oncology, Milan, Italy
francesco.chu@ieo.it

Scientific Secretariat:
G. Pietrobon
Division of Otolaryngology Head & Neck Surgery
European Institute of Oncology, Milan, Italy
giacomo.pietrobon@ieo.it

Editorial Assistant:
P. Moore

Copy Editor:
L. Andreazzi - landreazzi@pacinieditore.it

Treasurer:
F. Pagella - tpagella@libero.it

Argomenti di Acta Otorhinolaryngologica Italica
Editor-in-Chief: M. Ansarin
Editorial Coordinator: M. Tagliabue
Division of Otolaryngology Head & Neck Surgery
European Institute of Oncology, Milan, Italy
marta.tagliabue@ieo.it

© Copyright 2019 by
Società Italiana di Otorinolaringoiatria
e Chirurgia Cervico-Facciale
Via Luigi Pigorini, 6/3 - 00162 Rome, Italy

Publisher
Pacini Editore Srl
Via Gherardesca, 1 - 56121 Pisa, Italy
Tel. +39 050 313011 -Fax +39 050 3130300
info@pacinieditore.it - www.pacinimedicina.it

Acta Otorhinolaryngologica Italica is cited in Index Medicus, MEDLINE, PubMed Central, Science Citation Index Expanded, Scopus, Open-J Gate, Free Medical Journals, Index Copernicus, Socolar

Journal Citation Reports: Impact Factor 1.196
Acta Otorhinolaryngologica Italica is available on Google Scholar

S.I.O.R. CIIC-E

PACINI EDITORE MEDICINA

Volume 39
April 2019
2

www.actaitalica.it

Contents

Review

Brain abscess of odontogenic origin in children: a systematic review of the literature with emphasis on therapeutic aspects and a new case presentation
Ascessi cerebrali di natura odontogena nei bambini: revisione sistematica della letteratura con attenzione agli aspetti terapeutici e presentazione di un nuovo caso clinico
C. Lajolo, G. Favia, L. Limongelli, A. Tempesta, A. Zuppa, M. Cordaro, I. Vanella, M. Giuliani 67

Head and neck

Trans-oral robotic surgery for the management of oropharyngeal carcinomas: a 9-year institutional experience
Chirurgia transorale robotica per il trattamento del carcinoma orofaringeo: esperienza di 9 anni
G. Meccariello, F. Montevecchi, G. D'Agostino, G. Iannella, S. Calpona, E. Parisi, M. Costantini, G. Cammaroto, R. Gobbi, E. Firinu, R. Sgarzani, D. Nestola, C. Bellini, A. De Vito, E. Amadori, C. Vicini 75

Long-term disease-free survival in surgically-resected oral tongue cancer: a 10-year retrospective study
Sopravvivenza libera da malattia a lungo termine nel tumore della lingua mobile operato: studio retrospettivo a 10 anni
A. Marra, M. Violati, F. Broggio, C. Codecà, M. Blasi, A. Luciani, S. Zonato, D. Rabbiosi, L. Moneghini, A. Saibene, A. Maccari, G. Felisati, D. Ferrari 84

Rhinology

Lateral osteotomy plus hump resection vs hump re-modeling without lateral osteotomy: impact on frontal nasal view
Confronto tra osteotomia laterale più gibbectomia e rimodellamento del gibbo senza osteotomia laterale: effetti sulla visione frontale
P.G. Giacomini, A. Boccieri, E. Fuccillo, R. Di Mauro, S. Di Girolamo 92

Evaluation of nasal symptoms in septoplasty patients using SNOT-22
Valutazione dei sintomi nasali mediante SNOT-22 nei pazienti sottoposti a settoplastica
D. Dizdar, A. Bozan, S.K. Dizdar, S. Göde, H.C. Alpay 98

Audiology

Right-to-left shunt and idiopathic sudden sensorineural hearing loss
Shunt destro-sinistro e ipoacusia neurosensoriale improvvisa idiopatica
L. Capuano, M. Cavaliere, D. Lopardo, G. Parente, A. Damiano, R. Perone, A. Marino, P. Bottiglieri, M. Iemma 103

Validation of the Chronic Tinnitus Acceptance Questionnaire (CTAQ-I): the Italian version
Validazione della versione italiana del Questionario sull'Accettazione dell'Acufene Cronico (CTAQ-I)
R. Moschen, A. Fioretti, A. Eibenstein, E. Natalini, . Chiarella, P. Viola, D. Cuda, C. Cassandro, A. Scarpa, G. Rumpold, D. Riedl 107

Maxillo facial and plastic surgery

Use of a CAD-CAM inferior alveolar nerve salvage template during mandibular resection for benign lesions
Utilizzo di una guida CAD-CAM per la preservazione del nervo alveolare inferiore durante le resezioni mandibolari nelle lesioni benigne
F. Ricotta, S. Battaglia, A. Sandi, A. Pizzigallo, C. Marchetti, A. Tarsitano 117

Otology

Canal wall down approach for tympano-mastoid cholesteatoma: long-term results and prognostic factors
La timpanoplastica aperta per il trattamento dei colesteatomi timpanomastoidei: risultati a lungo termine e fattori prognostici
R. Pareschi, D. Lepera, R. Nucci 122

Case series and reports

Internal carotid artery injury during endonasal sinus surgery: our experience and review of the literature
Rottura dell'arteria carotide interna durante la chirurgia nasale endoscopica: nostra esperienza e review della letteratura
S.G. Lum, B.S. Gendeh, S. Husain, H.S. Gendeh, M.R. Ismail, C.J. Toh, A. Izaham, H.J. Tan 130

Errata Corrige 137

Articles in open access, information for authors including editorial standards for the preparation of manuscripts and submission and Publisher's note available on-line: www.actaitalica.it

ACTA OTORHINOLARYNGOLOGICA ITALICA 2019;39:67-74; doi: 10.14639/0392-100X-2281 OPEN ACCESS

Review

Brain abscess of odontogenic origin in children: a systematic review of the literature with emphasis on therapeutic aspects and a new case presentation

Ascessi cerebrali di natura odontogena nei bambini: revisione sistematica della letteratura con attenzione agli aspetti terapeutici e presentazione di un nuovo caso clinico

C. LAJOLO[1], G. FAVIA[2], L. LIMONGELLI[2], A. TEMPESTA[2], A. ZUPPA[3], M. CORDARO[1], I. VANELLA[1], M. GIULIANI[4]

[1] Head and Neck Department, "Fondazione Policlinico Universitario A. Gemelli – IRCCS"; School of Dentistry, Università Cattolica del Sacro Cuore, Rome, Italy; [2] Department of Interdisciplinary Medicine, Complex Operating Unit of Odontostomatology, "Aldo Moro" University, Bari, Italy; [3] Department of Women's and Children's Health, Division of Paediatrics, "Fondazione Policlinico Universitario A. Gemelli – IRCCS", Università Cattolica del Sacro Cuore, Rome, Italy; [4] Department of Clinical and Experimental Medicine, University of Foggia, Italy

SUMMARY

Brain abscesses (BAs) are rare but life-threatening infections. BAs of an odontogenic origin should always be considered as a possible aetiological factor, especially when other infectious foci are not present. Clinical presentation in children may be ambiguous and pose a difficult differential diagnosis: the identification of causal bacteria can be difficult and odontogenic origin is often a diagnosis of exclusion. The aim of this paper was to systematically review the literature reports with particular emphasis on therapy and propose a diagnostic flowchart for odontogenic brain abscess in children. A systematic literature review was performed on PubMed, Scopus and ISI Web of Science to identify cases of BAs in children and discuss clinical management: only human research articles, published in peer-reviewed English language journals, were included. Among 109 articles, 7 publications were selected for data analysis: clinical data could be extracted for only 8 subjects; different clinical approaches are descripted in the reports, even if therapy should be started as soon as possible to prevent rapid diffusion to the rest of the central nervous system. Due to their rarity and ambiguous clinical presentation in children, BAs of odontogenic origin are difficult to diagnose. A thorough oral-maxillofacial investigation should always be performed to exclude an oral origin.

KEY WORDS: Brain abscess • Oral abscess • Antibiotic therapy • Children

RIASSUNTO

Gli ascessi cerebrali (BA) sono infezioni rare, ma potenzialmente letali. L'origine odontogena degli ascessi cerebrali dovrebbe essere presa in considerazione soprattutto quando non sono presenti altri focolai infettivi. La presentazione clinica nei bambini può essere ambigua e potrebbe porre una diagnosi differenziale difficile: l'identificazione dei batteri causali può essere complessa e la conferma di un'origine odontogena dell'ascesso è spesso derivante da una diagnosi di esclusione. Lo scopo di questo articolo è quello di ottenere una revisione sistematica della letteratura con particolare attenzione alla terapia e proporre un diagramma di flusso diagnostico per l'ascesso cerebrale odontogeno nei bambini. È stata eseguita una revisione sistematica della letteratura su PubMed, Scopus e ISI Web of Science per identificare casi di BA nei bambini e discutere la loro gestione clinica: sono stati inclusi solo articoli su umani, pubblicati su riviste in inglese peer-reviewed. Tra 109 articoli, solo 7 pubblicazioni sono state selezionate per l'analisi dei dati: i dati clinici potevano essere estratti solo per 8 soggetti; nei rapporti vengono descritti diversi approcci clinici, tuttavia la terapia deve essere iniziata il prima possibile per impedire una rapida diffusione al resto del sistema nervoso centrale. A causa della loro rarità e della presentazione clinica ambigua nei bambini, le BA di origine odontogena sono difficili da diagnosticare. Un'analisi approfondita oro-maxillo-facciale dovrebbe sempre essere eseguita per escludere l'origine orale dell'ascesso.

PAROLE CHIAVE: *Ascessi cerebrali • Ascessi orali • Terapia antibiotica • Bambini*

Introduction

Brain abscesses (BAs) are focal infections that start as circumscribed cerebritis and evolve to necrosis with purulent exudate surrounded by a pseudo-capsule. BAs in the adult population have a higher rate in men than in women and have an incidence of approximately 1 in 100,000 new cases per year. Although more accurate diagnostic tools (CT and MRI) and the use of more powerful and targeted antibiotics have greatly improved prognosis, both quoad

© Società Italiana di Otorinolaringoiatria e Chirurgia Cervico-Facciale

vitam and quoad valetudinem, BAs are still extremely serious and life-threatening infections, with 0 to 24% mortality. The cause of BAs remains unknown in 15 to 30% of cases [1-3].

Twenty-five percent of all BAs occur in children, between 4 and 7 years, most often presenting with multiple abscesses (approximately 30% of cases) [4-6].

This age group might be particularly susceptible because the first phase of teeth exfoliation takes place in this period, and the remaining deciduous teeth are exposed to the oral cavity for several years, which makes them more vulnerable to tooth decay. Furthermore, in this age, children become more autonomous in dental brushing and do not always achieve optimal plaque control. The most frequently involved tooth seems to be the deciduous canine. The permanent bud is localised in a very cranial position in the maxilla ramus and can spread infection to the proximal maxillary and ethmoidal sinus [7 8]. For all these reasons, it is highly recommendable to have children visited by a dentist, on a regular basis, beginning at the age of 3.

Because BAs may be the result of dental infections, it is essential to perform careful clinical and radiological exam of the maxillofacial region whenever other infective sources are not detected.

In this paper, we present the results of a systematic literature review of odontogenic brain abscesses arising in childhood with emphasis on diagnosis and therapy, propose a clinical flow chart and describe a new representative case.

Materials and methods

The systematic search and review processes [9] were conducted on PubMed, ISI Web of Science and Scopus databases to identify articles concerning BAs in children until June 2017: we carried out a systematic search for the terms “brain abscess” and “odontogenic” which were combined with the operator ‘AND’. The research was limited to children age using website limits. Two of the authors (C.L. and G.F.) independently examined all titles and abstracts retrieved and selected articles concerning with the selected topics. These included all types of human peer-reviewed research articles (i.e. case reports, cross-sectional, cohort, case-control or retrospective studies), published in English on peer-reviewed journals and describing or reporting clinical characteristics and management of odontogenic BAs in children. For a more comprehensive view on the topic, reviews, letters and commentary articles were also included. Exclusion criteria were: articles concerning odontogenic BAs in adults or reporting BAs in children not of ontogenic origin, and papers published in languages other than English. If there were no accordance on one paper, it was evaluated by a third reviewer (M.G.) for the final decision.

Results

The preliminary search retrieved 13 references in PubMed, 21 results in ISI web of Science and 75 in Scopus for a total of 109 articles. After exclusion of studies that did not meet the inclusion criteria and removal of duplicates, our search identified a total of 7 publications (Fig. 1) for review. The extracted data are reported in Table I.

Clinical data on 8 subjects, mean age 9 years (range 3-18), 5 males and 3 females could be extracted from the 7 papers. No diagnostic symptom could be identified, whereas radiological findings showed a predominance of frontal localisation (4 in the frontal lobe, 1 in the front/temporal and 1 in the temporal lobe). Therapeutical protocols will be described in the discussion section.

An interesting and representative new case is described in Figures 2 and 3: briefly, a 5-year-old boy, previously in good health, was hospitalised for suspected meningitis. He was confused and presented with fever, headache, vomit, neck stiffness and sight impairment. The medical history reported by his parents was non-contributory, except for the report of neglected recurrent dental abscesses mainly in the upper jaw. After examining the fundus oculi to exclude intracranial hypertension, rachicentesis was performed. No abnormal findings were detected in the cerebrospinal fluid, which appeared transparent, without sediment, and had normal chemical properties (glucose and proteins). In the following days, the culture was re-

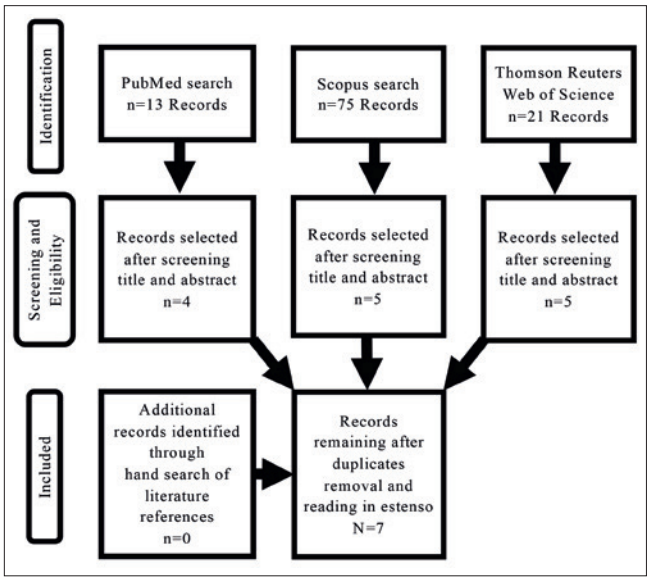

Fig. 1. The flow chart summarises the article search and revision strategy.

Table I. Clinical data on the 8 children.

References	Kanu OO, 2011 [19]	Maraki S, 2016 [27]	Hibberd CE, 2012 [11]	Solanki R, 2014 [26]	Vargas J, 2006 [21]	Moskovitz M, 2012 [22]	Canpolat M, 2015 [4]
Age	10	6	11	12	18	3	4 and 11
Sex	M	M	M	F	M	F	M
Presenting symptoms	Fever Recurrent headaches	Worsening Drowsiness Episodes of vomiting	Confusion/ Somnolence/ Behavioral disorders/ Dysphasia/ Unsteady ambulation/ Neck stiffness	Endocranial hypertension symptoms	Endocranial hypertension symptoms/ Behavioural disorders	Fever/ Vomiting/ Somnolence	Nausea/ vomiting/ headache / convulsion/fever/ altered state of consciousness.
Clinical examination	No neurological symptoms/ Oral exam: cavities and periodontal disease (cavity of inferior premolar and high mobility of superior canine and inferior premolar)	Heart rate of 110 beats/minute, blood pressure 110/85 mmHg, oxygen saturation 97%. Afebrile, pale, with supple neck, dry mucous membranes, slightly decreased level of consciousness (Glasgow coma scale 12)	Oral exam: dental abscess of deciduous inferior molar 3 weeks before	CHD (Congenital Heart Disease)/ Fever/ Headache/ Vomiting/ Papilledema/ Poor oral hygiene	Headache/ Vomiting/ Aphasia/ Weakness of the left lower limb/ Behavioural disorders/ Fever/ Medical history of multiple periodontal treatments and extractions	Cyanotic Heart Disease/ Oral exam: cyanotic lips, left submandibular lymphadenopathy, gingivitis, poor oral hygiene, cavities, dental abscess with vestibular fistula from a deciduous molar	Normal neurological examination
Radiology	Frontal lesion with dura mater detachment and compression of frontal lobe	Chest radiograph normal. Sizable ring-enhancing lesion in the left frontal lobe (TC-SCAN). Brain oedema	Lesion of temporal lobe	Lesion of frontal lobe (size: 6x5 cm)	Lesion of left fronto-parietal lobe	Hypodense lesion of right medial and posterior region of the frontal lobe (size: 10x11 mm)	
Microbiology (culture)	Brain inflammatory exudate: no bacteria. Dental inflammatory exudate: *Staphylococcus aureus* sensitive to Ceftriaxon	*A. aphrophilus Catalase* and oxidase negative, and X and V factor independent Gram-negative coccobacillus. Isolate susceptible to ampicillin, amoxicillin plus clavulanic acid, cefuroxime, ceftriaxone, cefotaxime, imipenem, meropenem, clarithromycin, azithromycin, ciprofloxacin, levofloxacin, cotrimoxazole, tetracycline, and chloramphenicol	Brain inflammatory exudate: *S. anginosus*. Dental inflammatory exudate: *Streptococcus sp*	*Streptococcus oralis*	*Arcanobacterium haemolyticum*	*Streptococcus Intermedius*	Cultures sterile in 40%, *Peptostreptococcus*

continues ▶

Table I. *follows.*

References	Kanu OO, 2011 [19]	Maraki S, 2016 [27]	Hibberd CE, 2012 [11]	Solanki R, 2014 [26]	Vargas J, 2006 [21]	Moskovitz M, 2012 [22]	Canpolat M, 2015 [4]
Treatment	Craniotomy and drainage/ Antibiotic treatment (Ceftriaxone, Gentamycin, Metronidazole iv for 2 weeks and Cefpodoxime po for 3 week)/ Dental surgery	Frontoparietal (pterional) Craniotomy. (Metronidazole intravenous high-dose meropenem was administered as monotherapy for a total of 8 weeks)	Craniotomy and drainage/ Antibiotic treatment (Vancomycin, Ceftriaxone, Metronidazole and Phenytoin)/ Dental surgery	Drainage/ Antibiotic treatment (Empiric therapy: Ceftriaxon 500 mg ev, Amikacin 500 mg ev, Metronidazole 100 ml ev + support therapy. Targeted therapy: Vancomycin 30 mg/Kg per 12 h, than Levofloxacin 250 mg 2/die for 15 days)	Craniotomy and drainage/ Antibiotic treatment (Empiric therapy: Ceftriaxone 2 g/ day iv; Metronidazole 500 mg each 8 h ev; Targeted therapy: Penicillin G 24 mU /die ev for 21 days)	Pharmacological therapy (Dexamethasone 0.6 mg/Kg/die; Ceftriaxone 100 mg/Kg/die; Vancomycin 60 mg/Kg/die; Mannitol iv for 7 weeks; Metronidazole 30 mg/kg/day and Cefixime po for 3 months)/ Dental surgery	Surgical treatment: excision and drainage surgery. Medical treatment: antibiotic therapy for 6 weeks (ampicillin/sulbactam+amikacin+metronidazolo) 4y (Ceftriaxone+vancomicina+matronidazolo+rifampicina) 11y
Outcome	Good	Good	Residual comprehension problems	Good after 2 weeks of therapy	Good after 4 weeks	Good	No neurological sequelae in 1 patient, epilepsy and hemiparesis in the other.

vealed to be negative. Because of the history of recurrent dental abscesses, a CT scan of the skull and of the maxillofacial area was performed, revealing the presence of BAs in the right frontal and occipital lobes; the right maxillary and ethmoidal sinus were completely opaque, demonstrating a diffusion by contiguity of an inflammatory process from the upper maxilla (Fig. 2). Intraoral examination and panoramic radiograph of the jaws showed multiple infective foci (granulomas) and poor oral health status (Fig. 3). No other relevant head (middle ear, mastoid) or body foci were detected. After broad spectrum antibiotic therapy (ceftriaxone 100 mg/kg/day; gentamicin 3 mg/kg/day; metronidazole 10 mg/ kg/8 h; for 4 weeks) and the extraction of many dental roots (14 elements), the child was discharged with complete recovery. To date, four years later, the child shows no sequelae.

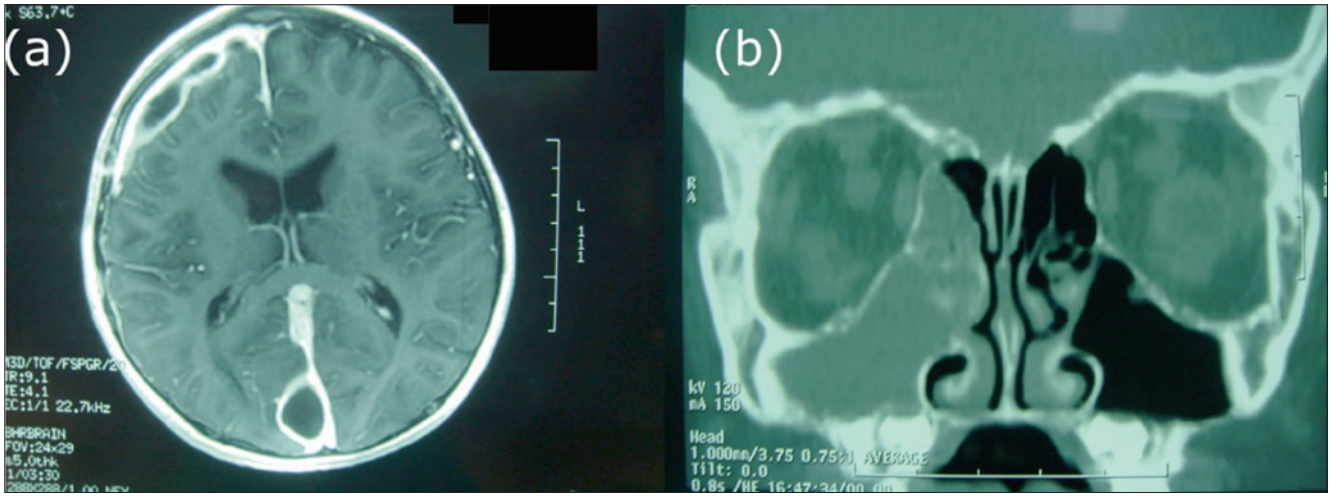

Fig. 2. A) Axial CT scan of the skull showing multiple brain abscesses in the frontal and occipital right parenchyma. **B)** Coronal CT scan of the mid-face showing the opacified right paranasal sinuses and the close relation with the brain (frontal fossa). In the case presented herein, diagnosis was driven by careful history and dental examination and was confirmed by CT scan, which showed diffusion of the infectious process to the brain.

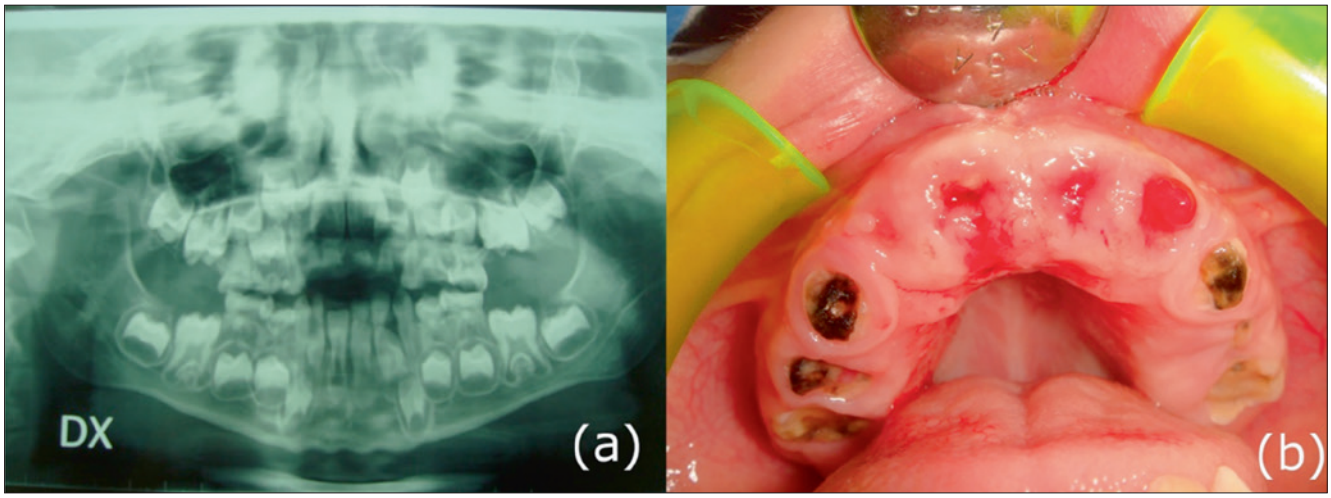

Fig. 3. A) Panorex shows poor oral health condition of the child. **B)** Intra-oral clinical presentation: numerous residual roots can be seen in the upper jaw.

Discussion

Brain abscesses are focal necrotic infections of the brain parenchyma which have a severe prognosis, both quoad vitam and quoad valetudinem, even if more effective antibiotic therapies are now available [1-6]. The literature reports highlight that about one-quarter of the BAs occur in children and, among these, the most affected age is between 4 and 7 years: in this regard, in our review a wide range of ages were found (3 to 18 years with a mean age of 8): such a wide age range should be carefully considered in the therapeutic approach and regimen [4-6].

Generally, BAs are favoured by immunosuppression and follow three main pathogenetic mechanisms: 1) haematogenous dissemination due to predisposing conditions (e.g., acute bacterial endocarditis, congenital heart defects with right to left shunt and by-pass of the pulmonary filter, bronchiectasis and other chronic septic foci); 2) direct inoculation during neurosurgical manoeuvres or brain trauma; and 3) spread by direct head, maxillofacial and ENT foci, of which odontogenic dissemination represents 3 to 10% of all cases [10 11].

Thrombophlebitis of the cavernous sinus due to thrombophlebitis of the facial (retromandibular) or ophthalmic veins has been advocated in the past as a major cause of the onset of BAs secondary to dental infections. More recently, Zhang and Stringer have demonstrated, in a study on cadavers, the presence of valves in the facial and ophthalmic veins; the increased risk of blood-borne brain infections from the oro-maxillo-facial area was thus attributed to the presence of diffuse facial anastomosis between the facial vein, pterygoid plexus, angular vein, ophthalmic vein and the cavernous sinus. Through these and other anatomical structures (maxillary and ethmoid sinuses), many infectious processes of the oral cavity (dental abscesses, periodontal osteomyelitis) can cause BAs [12].

Regarding the clinical features of BAs, there are several recognizable general and specific signs and symptoms that can indicate brain involvement. The most common general features of brain involvement are increased intracranial pressure, severe headache, nausea and vomiting, fever, convulsions, stiff neck, lethargy, aphasia, paresthetic crisis, behavioural changes and difficulty walking. Some cases have reported suture separation and bulging fontanelles. Specific brain involvement features are proportional to the involved parenchyma (e.g., cortical signs, bulb/pons nuclei involvement, cranial nerves). Paediatric presentation of BAs often does not encompass the classic triad of symptoms (fever, headache and neurological deficits) because symptoms can be nonspecific and mild [5].

The onset of mild and unspecific neurological symptoms can make differential diagnosis between meningitis and BAs difficult. Lumbar puncture can be of great diagnostic help; however, it can only be performed after exclusion of intracranial hypertension (in this regard, the fundus examination can show papilledema), otherwise transtentorial brain hernias can occur. In adults, intracranial hypertension was detected in 40 to 70% of BAs. In paediatric populations, this frequency is lower due to the possible distention of the skull [13-15]. If the lumbar puncture is negative, meningitis can usually be excluded. Therefore, a brain MRI should be performed to diagnose cerebritis or BAs.

There are four main phases that can be recognised in the pathogenesis of BAs: 1) early cerebritis, undifferentiated from the rest of the brain; 2) late cerebritis, with the onset of a reticular matrix (precursor of collagen) and the

development of a necrotic centre; 3) development of an early capsule with neo-vascularisation around a necrotic centre; and 4) late formation of the capsule characterised by a collagen capsule, necrotic centre and gliosis around the capsule [10].

In the case of history of recurrent dental abscesses and clinical examination that confirms the presence of numerous dental lesions, a CT scan can be performed to assess the presence of spread from oro-maxillo-facial structures. Microbiological investigations must be carried out on the blood, cerebrospinal fluid and exudate (drainage) together with imaging procedures. The diagnostic process we propose is summarised in a flow chart (Fig. 4).

The diagnostic corroboration of BAs of dental origin can be very complex because many potential sources of primary infection, even extraoral, should be considered. Thus, dental origin is often a diagnosis of exclusion. The diagnostic criteria [2] that should be collected to reach a diagnosis of BAs of odontogenic nature are as follows:

1) No other infection sources, particularly heart (endocarditis) and ENT diseases (recent sinusitis, otitis media, upper respiratory tract infections).
2) Microbiological evidence in brain exudate of bacteria pathogens normally found either in periodontal pockets, such as *Porphyromonas gingivalis*, *Prevotella intermedia*, *Aggregatibacter actinomycetemcomitans*, or in periapical foci, such as *Bacteroides species*, *Streptococcus, Fusobacterium, Peptostreptococcus, Actinomyces* and S*pirochaetes*, as well as the *Enterococcus faecalis* and *Candida albicans*, which are associated with persistent endodontic infections.
3) Presence of clinical and radiographic signs of dental infection that can cause acute or chronic abscesses.

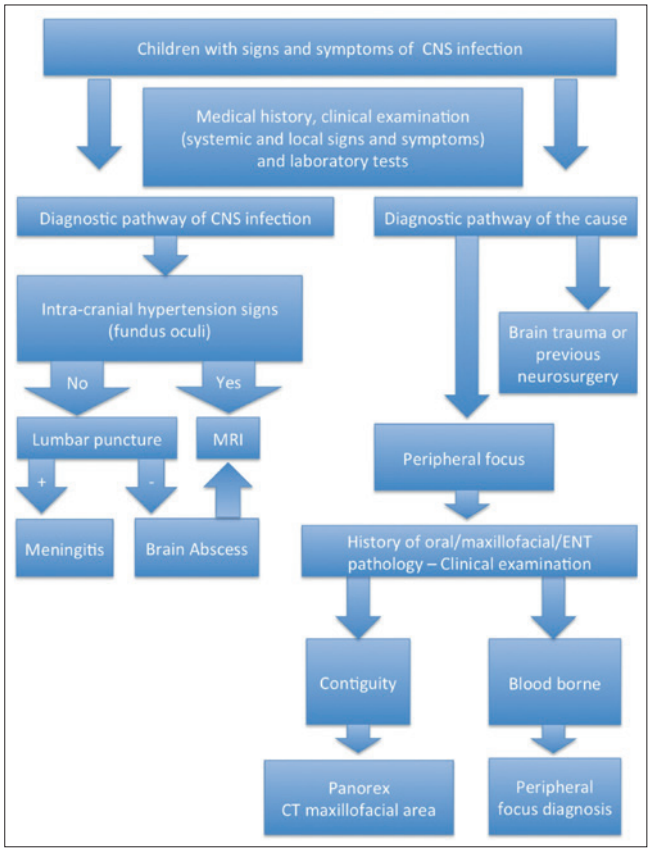

Fig. 4. Flowchart describing the clinical approach to children presenting with signs and symptoms of central nervous system (CNS) acute infection. (MRI: Magnetic Resonance Imaging; ENT: ear, nose and throat; CT: Computed Tomography).

According to a previous study, microbiological concordance between the oral cavity and the BA alone is not sufficient to diagnose odontogenic BA. The microbiological concordance could be due to chance, as there are many intraoral bacterial strains, BAs can occur spontaneously and dental infections (especially periodontal disease and periapical lesions) are common in adults [16]. Moreover, many studies have shown the occurrence of frequent bacteraemia of oral origin during the day, either as a result of masticatory acts, hygienic manoeuvres or therapeutic procedures.

Despite advanced microbiological culture and molecular biology techniques (PCR), microbiological diagnosis is not always successful. The literature regarding odontogenic BAs indicates that microorganisms from the oral cavity have been found in different areas of the brain parenchyma (in the fronto-parietal lobe, the pre-septal region, the occipital lobe, and the frontal and parietal lobe), either in single or multiple lesions [17].

The most commonly reported microorganisms are *Streptococci viridanti* (or *α-haemolitic*), *Bacteroides* and *Aggregatibacter actinomycetemcomitans* [1 3 18]. Viridans species can be isolated in the mouth or in other body sites and the most frequently encountered species in human pathology are *S. mutans*, *S. salivarius*, *S. sanguis*, *S. mitior* and *S. milleri*. The first four species can produce glucans that favour adherence to smooth surfaces, such as enamel or other structures (e.g., endocardium); *S. milleri*, however, does not produce glucans and has only been occasionally isolated from abscess lesions (periodontal abscesses, brain, bowel, etc.). The *S. milleri* group is now more properly called the Streptococci anginosus group. These bacteria are involved in various purulent infections, including abscesses in various parts of the body and are divided into three species: *S. anginosus*, *S. intermedius* and *S. constellatus*, which each have a different tissue tropism. In particular, a strong association between S. intermedius and BAs has been detected [16]. Identification of a single specific strain within the *S. anginosus* group cannot

be achieved with routine microbiological technique. Only molecular biology techniques, such as PCR, can identify the single sub-species. In children, *Staphylococcus aureus* is the most frequently involved microorganism, followed by the *Bacteroides*, *Clostridium, Proteus, Pseudomonas* and *Haemophilus species* [19]. In this regard, several studies have highlighted that many dental procedures (e.g., extractions, alveolar surgery, periodontal therapy, injection of local anaesthetic and dental hygiene) can cause bacteraemia; even minimally invasive procedures can cause transient bacteraemia. In a study by Roberts et al. (1997) conducted on children, transient bacteraemia was detected in 38.5% of cases after tooth brushing, whereas more invasive procedures (such as tooth extractions) resulted in a massive general circulation of microorganisms [20]. In most individuals, however, the immune system eliminates and controls the numerous microorganism intrusions that occur during the day. Therefore, the duration of bacteraemia, an individual's predisposition or a particular bacteria virulence are necessary for the onset of a distant infection [11]. These findings led to a change in the antibiotic prophylaxis protocols for oral surgery procedures to indicate precise procedures and patient types with particular risk factors (e.g., prosthetic valves, carriers of prostheses, previous infective endocarditis) [18].

Among different systemic factors, such as immunosuppression, diabetes, congenital heart disease represents the most important predisposing factor for BAs in childhood [4 22]. Other individual predispositions, such as arteriovenous malformations (AVMs), can contribute to developing BAs. Inherited bleeding telangiectasia (HHT), or Rendu-Osler-Weber syndrome, is an autosomal dominant disorder that is a predisposing factor for the onset of BAs. Recurrent episodes of spontaneous epistaxis, skin telangiectasia and mucous and visceral AVMs are its major clinical features and may involve the pulmonary circulatory system, liver, brain, spinal and other systems [23]. It is estimated that BAs occur in approximately 5 to 10% of patients with HHT; bacteraemia, especially of dental origin, plays a decisive role in the pathogenesis of BAs in patients with HHT. HHT, similar to some cardiac and pulmonary arteriovenous malformations, promotes haematogenous dissemination of septic emboli to the CNS, most likely because it facilitates the bypass of pulmonary capillary filtration (and thus avoids the action of reticuloendothelial system cells). Furthermore, patients with HHT may have a mild immunodeficiency condition [24].

The treatment of BAs consists of local infection control (antibiotic therapy with or without surgical drainage) and therapy of the focus that caused the BA (e.g., oral rehabilitation) [2 3 16 25]. A combined pharmacological-surgical approach is usually preferred, but it is still a matter of debate in the literature because medical management of the disease is sufficient to resolve the problem in some situations. Some clinical variables, such as the size of the abscess, location, origin, virulence of microorganisms, presence of multiple abscesses, patient response to antibiotic therapy and degree of perilesional oedema, can influence the therapeutic approach. Antibiotic therapy alone is preferred in cases of abscesses with a diameter of < 2 cm, high density lesions, multiple abscesses and systemic conditions that make surgery dangerous.

Drainage is the most common surgical approach, as it presents an opportunity to perform bacterial culture and antibiogram and helps to decompress intracranial hypertension. More rarely, craniotomy and excision are suggested for large abscesses (> 2.5 cm) that behave as a space-occupying process [24 26 27].

Although Evidence Based Medicine (EBM) clinical protocols for children are not available [Randomised Controlled Trials (RCTs) are not carried out], data emerging from the literature suggest that the combination of ceftriaxone 100 mg/kg/day, gentamycin 3 mg/kg/day (or vancomycin 60 mg/kg/day) and metronidazole 10 mg/kg/8 h for 4 weeks is the most used pharmacological protocol. Table I summarises the case reports of BAs of odontogenic origin in paediatric patients. A craniotomy with drainage of the abscess was practiced in three of the 7 children, while the other children, as in the case we present herein, received only antibiotics and resolution of the generating focus. In our case, the small dimensions of the BAs together with the easily resolution of the infective oral focus drove us to a more conservative therapy as suggested by Frazier [5], with the complete recovery of the child.

Conclusions

Due to their rarity and ambiguous clinical presentation in children, BAs of odontogenic origin are difficult to diagnose. A thorough oral-maxillofacial-ENT investigation should always be performed to exclude the oral origin.

Conflict of interest statement

None declared.

References

1 Carpenter J, Stapleton S, Holliman R. *Retrospective analysis of 49 cases of brain abscess and review of the literature*. Eur J Clin Microbiol Infect Dis 2007;26:1-11.

2 Ewald C, Kuhn S, Kalff R. *Pyogenic infections of the central nervous system secondary to dental affections - a report of six cases*. Neurosurg Rev 2006;29:163-6, discussion 166-7.

3 Rahamat-Langendoen JC, van Vonderen MGA, Engstrom LJ, et al. *Brain abscess associated with Aggregatibacter actinomycetemcomitans: case report and review of literature*. J Clin Periodontol 2011;38:702-6.

4 Canpolat M, Ceylan O, Per H, et al. *Brain abscesses in children: results of 24 children from a reference center in Central Anatolia, Turkey*. J Child Neurol 2015;30:458-67.

5 Frazier JL, Ahn ES, Jallo GI. *Management of brain abscesses in children*. Neurosurg Focus 2008;24;E8.

6 Volkan E. *Guidelines International Society for Pediatric Neurosurgery. Pathology of brain abscesses in children.* Website: https://www.ispn.guide/infections-of-the-nervous-system-in-children/brain-abscesses-in-children-homepage/. Accessed on February 5, 2019.

7 Sarumathi T, Saravana Kumar B, Manjula D, et al. *Prevalence, severity and associated factors of dental caries in 3-6 year old children*. J Clin Diagn Res 2013;7:1789-92.

8 Gershwin ME, Incaudo GA. *Diseases of the sinuses: a comprehensive textbook of diagnosis and treatment*. 1st edition. Ottawa: Humana Press; 1996. p. 259.

9 Moher D, Liberati A, Tetzlaff J, et al. *Preferred reporting items for systematic reviews and meta-analyses: the PRISMA statement*. Int J Surg 2010;8:336-41.

10 Frosch MP, Anthony DC, De Girolami U. *Robbins and Cotran, Pathologic basis of disease*. 8th edition. Philadelphia: Saunders Elsevier; 2010. pp. 1300-1301.

11 Hibberd CE, Nguyen TD. *Brain abscess secondary to a dental infection in an 11-yo child: case report*. J Can Dent Assoc 2012; 78:c49.

12 Zhang J, Stringer MD. *Ophthalmic and facial veins are not valveless*. Clin Experiment Ophthalmol 2010;38:502-10.

13 Gelabert-Gonzales M, Serramito-Garcìa R, Garcìa-Allut A, et al. *Management of brain abscess in children*. J Paediatr Child Health 2008;44:731-5.

14 Wong TT, Lee LS, Wang HS, et al. *Brain abscesses in children - a cooperative study of 83 cases*. Childs Nerv Syst 1989;8:19-24.

15 Hirsch JF, Roux FX, Sainte-Rose C, et al. *Brain abscess in childhood. A study of 34 cases treated by puncture and antibiotics*. Childs Brain 1983;10:251-65.

16 Corson MA, Postlethwaite KP, Seymour RA. *Are dental infections a cause of brain abscess? Case report and review of the literature*. Oral Dis 2001;7:61-5.

17 Azenha MR, Homsi G, Garcia IR Jr. *Multiple brain abscess from dental origin: case report and literature review*. Oral Maxillofac Surg 2012;16:393-7.

18 Tong DC, Rothnell BR. *Antibiotic prophylaxis in dentistry: a review and practice reccomandations*. J Am Dent Assoc 2000;131:366-74.

19 Kanu OO, Ukponmwan E, Bankole O, et al. *Intracranial epidural abscess of odontogenic origin.* J Neurosurg Pediatr 2011;7:311-5.

20 Roberts GJ, Holzel HS, Sury MRJ. *Dental bacteraemia in children*. Pediatr Cardiol 1997;18:24-7.

21 Vargas J, Hernandez M, Silvestri C, et al. *Brain abscess due to Arcanobacterium after dental extraction*. Clin Infect Dis 2006;42:1810-1.

22 Moskovitz M, Birenboim R, Katz-Sagi H, et al. *A brain abscess of probable odontogenic origin in a child with cyanotic heart disease*. Pediatr Dent 2012;34:403-6.

23 Larsen L, Marker CR, Kjeldsen AD, et al. *Prevalence of hereditary hemorrhagic telangiectasia in patients operated for cerebral abscess: a retrospective cohort analysis.* Eur J Clin Microbiol Infect Dis 2017;36:1975-80.

24 Mylona E, Vadala C, Papastamopoulos V, et al. *Brain abscess caused by Enterococcus faecalis following a dental procedure in a patient with hereditary hemorrhagic telangectasia*. J Clin Microbiol 2012;50:1807-9.

25 Lazow SK, Izzo SR, Vazquez D. *Do dental infections really cause central nervous system infections?* Oral Maxillofac Surg Clin North Am 2011;23:569-78.

26 Solanki R, Subramanian S, Lakshmi V, et al. *Brain abscess due to Streptococcus oralis in an immunocompetent patient*. Indian J Med Microbiol 2014;32:179-80.

27 Maraki S, Papadakis IS, Chronakis E, et al. *Aggregatibacter aphrophilus brain abscess secondary to primary tooth extraction: Case report and literature review*. J Microbiol Immunol Infect 2016; 49:119-22.

Received: July 20, 2018 - Accepted: November 22, 2018

How to cite this article: Lajolo C, Favia G, Limongelli L, et al. *Brain abscess of odontogenic origin in children: a systematic review of the literature with emphasis on therapeutic aspects and a new case presentation.* Acta Otorhinolaryngol Ital 2019;39:67-74. https://doi.org/10.14639/0392-100X-2281

Address for correspondence: Carlo Lajolo, Head and Neck Department, Division of General Dentistry and Orthodontics, "Fondazione Policlinico Universitario A. Gemelli – IRCCS", Università Cattolica del Sacro Cuore, Rome. School of Dentistry, largo A. Gemelli 8, 00168 Rome, Italy. Tel. +39 06 3015 4286. E-mail: carlo.lajolo@unicatt.it

ACTA OTORHINOLARYNGOLOGICA ITALICA 2019;39:75-83; doi: 10.14639/0392-100X-2199 OPEN ACCESS

HEAD AND NECK

Trans-oral robotic surgery for the management of oropharyngeal carcinomas: a 9-year institutional experience

Chirurgia transorale robotica per il trattamento del carcinoma orofaringeo: esperienza di 9 anni

G. MECCARIELLO[1], F. MONTEVECCHI[1], G. D'AGOSTINO[1], G. IANNELLA[2], S. CALPONA[3], E. PARISI[4], M. COSTANTINI[5], G. CAMMAROTO[1, 6], R. GOBBI[1], E. FIRINU[1], R. SGARZANI[7], D. NESTOLA[1], C. BELLINI[1], A. DE VITO[1], E. AMADORI[8], C. VICINI[1]

[1] Department of Head-Neck Surgery, Otolaryngology, Head-Neck and Oral Surgery Unit, Morgagni Pierantoni Hospital, Azienda USL della Romagna, Forlì, Italy; [2] Department of Organs of Sense, Ear, Nose, and Throat Section, University of Rome "La Sapienza," Italy; [3] Osteoncology and Rare Tumors Center, [4] Radiotherapy Department, Istituto Scientifico Romagnolo per lo Studio e la Cura dei Tumori (IRST), IRCCS, Meldola (FC), Italy; [5] Department of Surgical Pathology, Morgagni Pierantoni Hospital, Azienda USL della Romagna, Forlì, Italy; [6] Department of Otolaryngology, University of Messina, Italy; [7] Department of Emergency, Burn Center, Bufalini Hospital, Azienda USL della Romagna, Cesena, Italy; [8] Radiology Department, Istituto Scientifico Romagnolo per lo Studio e la Cura dei Tumori (IRST), IRCCS, Meldola (FC), Italy

SUMMARY

Trans-oral robotic surgery (TORS) has changed surgical management of patients with oropharyngeal squamous cell carcinomas (OPSCC). In this study we present surgical and oncologic outcomes of patients with oropharyngeal squamous cell carcinomas, treated using TORS, with and without an adjuvant therapy. Sixty patients with oropharyngeal squamous cell carcinomas treated with TORS between January 2008 and December 2017 have been retrospectively evaluated considering clinicopathologic features, disease characteristics, adjuvant treatments and oncological outcomes. TORS was performed for OPSCC to the base of tongue in 41.7%, tonsils in 46.7%, soft palate and posterior pharyngeal wall in 3.3% and 5%, respectively. Neck dissection was performed in 43.3% of patients. Management strategies included surgery alone in 30%, TORS and adjuvant radiotherapy in 33.3%, and TORS plus adjuvant chemotherapy in 36.7%. The 5-year overall survival of the total group was 77.6%, the 5-year disease-free survival rate was 85.2%, and the 5-year local recurrence-free survival rate was 90.6%. Finally, in selected patients TORS appears to yield similar oncologic outcomes and functional outcomes to traditional techniques and non-operative treatment with a possible benefit on long-term quality of life. The future offers exciting opportunities to combine TORS and radiotherapy in unique ways. However, further research is urgently needed to clarify the indications for adjuvant therapy following TORS resections.

KEY WORDS: Robotic surgery • Oropharyngeal • Cancer • Neck • HPV • p16 • Radiotherapy • Chemotherapy

RIASSUNTO

Nell'ultimo decennio, la chirurgia robotica trans-orale (TORS) ha rivoluzionato la gestione chirurgica dei pazienti con carcinoma dell'orofaringe(OPSCC). Questo studio monocentrico presenta i risultati oncologici delle neoplasie orofaringee trattate con TORS con e senza terapia adiuvante nei primi nove anni della nostra esperienza robotica. Sessanta pazienti sono stati trattati tra gennaio 2008 e dicembre 2017. Sono stati acquisiti i dati riguardanti le caratteristiche clinico-patologiche, i trattamenti adiuvanti e gli esiti oncologici. La TORS è stata eseguita per OPSCC della base della lingua nel 41,7% dei casi; nel 46,7% per carcinoma tonsillare, mentre neoplasie del palato molle e/o della parete posteriore faringea sono state rispettivamente il 3,3% e 5% dei casi. La svuotamento del collo è stato eseguito nel 43,3% dei pazienti. Le strategie di gestione includevano la sola chirurgia nel 30% dei casi, TORS e radioterapia adiuvante nel 33,3% e TORS e radiochemioterapia adiuvante nel 36,7%. La sopravvivenza globale a 5 anni del gruppo totale è del 77,6%, il tasso di sopravvivenza libera da malattia a 5 anni è dell'85,2% e il tasso di sopravvivenza libera da recidiva locale a 5 anni è del 90,6%. Infine, in alcuni pazienti selezionati, la TORS sembra fornire esiti oncologici e funzionali simili alle tecniche tradizionali e al trattamento di preservazione d'organo con un possibile beneficio per la qualità della vita a lungo termine. Tuttavia, ulteriori ricerche sono urgentemente necessarie per chiarire le indicazioni e l'erogazione della terapia adiuvante dopo le resezioni TORS.

PAROLE CHIAVE: *Chirurgia robotica • Orofaringeo • Cancro • Collo • HPV • p16 • Radioterapia • Chemioterapia*

© Società Italiana di Otorinolaringoiatria e Chirurgia Cervico-Facciale

Introduction

Over the past 40 years, non-operative management has become the most common therapy for oropharyngeal squamous cell carcinomas (OPSCC) due to advances in radiotherapy and the significant functional deficits left by traditional surgical approaches. On the other hand, the introduction of trans-oral robotic surgery (TORS) has led to a resurgence in the role of surgery in the management of patients with OPSCC. The oncologic efficacy of TORS is clear and for selected patients, functional outcomes are outstanding [1]. The goal of any oncological therapy should be to achieve long-term disease-free survival while minimising acute and late toxicities. With modern radiotherapy techniques, severe late toxicity is often minimal [2]. Therefore, the decision to pursue an operative versus non-operative strategy is centred on patient and tumour factors identified on history, physical exam and imaging. One of the goals of a TORS resection is to obtain negative margins on the primary tumour with minimal functional morbidity. This issue is most achieved in early OPSCC, clearly localised in an oropharyngeal subsite. Effectively, TORS was approved by the United States Food and Drug Administration for benign and malignant tumours classified as T1-2 in 2009 [3]. Nevertheless, the use of TORS for select locoregionally advanced patients (cT3 or cN2-3) may improve oncologic control compared to chemoradiation (CRT) alone [1]. NCCN guidelines recognise transoral surgery as a potentially useful tool in the treatment of these selected patients [1]. In addition, TORS may be a valuable method of de-intensification for the locoregionally-advanced patient in at least three ways: decreasing the dose of radiotherapy (RT); obviating the need for chemotherapy and decreasing the radiotherapy target volume.
Herein, we specifically investigate our experience in treating OPSCC patients with TORS.

Materials and methods

The medical charts of consecutive patients who underwent TORS for OPSCC at our Department between January 2008 and December 2017 were evaluated retrospectively. Clinicopathologic features of interest included age at surgery, comorbidity, sex, HPV status, final margin status, pathologic T classification, pathologic N classification, overall American Joint Committee on Cancer (AJCC) stage (7th edition), extracapsular spread (ECS) and primary treatment, including TORS alone, TORS and RT, and TORS and CRT. Tumour HPV status was considered positive if either HPV in situ hybridisation or HPV p16 was positive. Exclusion criteria included distant metastases at presentation, primary treatment other than intent-to-cure, or a history of previously treated head and neck squamous cell carcinoma. The surgical approach has previously been described [4 5]. Of note, narrow band imaging (NBI) was used intraoperatively after 2010 to enhance resection of margins [4]. The edges of surgical excision were set at least 1 cm from the tumour. Negative margins or close margins were stated if more than 5 mm or less than 5 mm of surrounding free tissue was present on microscopic evaluation, respectively. Adjuvant RT was recommended for patients with N2b/N2c/N3 disease, close final margins, and all patients with T3 tumours. Adjuvant CRT was recommended for patients with pathologic ECS and positive margins. Recurrence was classified as the time between surgical treatment and the date at which a patient was diagnosed with a local recurrence, nodal recurrence, or distant metastases. A second primary tumour was defined as occurring > 5 years after initial treatment or occurring in a unique subsite separate from the original tumour bed. Additionally, a re-evaluation of tumour staging based on the 8th edition of the AJCC cancer staging was performed. Disease-free survival (DFS), local recurrence-free survival (LRFS), regional recurrence-free survival (RRFS), total follow-up and 5-year overall survival (OS) were registered.

Statistical analysis

To test for differences among groups, Fisher's exact test was used for categorical data, while the Student's t-test was used for continuous data. The role of each possible prognostic factor (univariate analysis) and their independent effect (multivariate analysis) was explored using logistic regression model or Cox-proportional hazard model as appropriate. Survival analysis was performed by the Kaplan-Meier method. Probability values lower than 0.05 were considered statistically significant. All analyses were performed with STATA 12.1 software (Stata Corp., College Station, TX, USA).

Results

Since 2008, our institution has used TORS mainly to resect hypertrophic bases of tongue (BOT) in case of sleep apnoea disorders and surgically resectable OPSCC. Up to December 2017, 514 TORS procedure were executed. In the same period, a total of 60 OPSCC were treated with TORS alone or in combination with adjuvant RT or CRT based on pathologic cancer staging.
All patients were treated with intent-to-cure. Management strategies included surgery alone in 30% (18/60), TORS-RT in 33.3% (20/60) and TORS-CRT in 36.7% (22/60). Patients undergoing TORS-CRT were more likely to have

higher nodal, ECS and overall AJCC stages ($p < 0.001$). The primary tumour was classified as cT1(22/60; 36.7%), cT2(23/60; 38.3%), cT3(6/60; 10%) and cTx(9/60; 15%). The primary tumour arose in the BOT in 25 patients (41.7%), tonsils in 28 patients (46.7%), soft palate in 2 (3.3%) and posterior pharyngeal wall in 3 (5%). Unfortunately in 2 cTx, the primary was not found, while the primary was in the palatine tonsil or in the BOT in 3 and 4 cases, respectively (all pT1). Regarding HPV status, 33 (61.1%) were considered HPV-positive.

In all patients, frozen section margins were obtained to check for clear margins. Margins remained clear in 56.7% of patients on final pathology. Of the remaining 26 patients 4 had only positive lateral margin, while 4 had only positive deep margin. Only close lateral margin was found in 5 cases, while 6 had only close deep margin and 3 patients had close both deep and lateral margins. In all, patients with at least one positive margin were 12 (20%) and those with close margins were 14 (23.3%).

The pathological staging according the 7th edition AJCC is shown in Table I. The re-evaluation according 8th AJCC is displayed in Table II for HPV-/p16-OPSCC and in Table III for HPV-related OPSCC. The secondary intention healing was the predominant choice in simple and no-extensive resection's cases (90%; 54/60). One facial artery myo-mucosal (FAMM) and 1 buccinator-based myomucosal (BMM) flaps were used to cover extensive carotid exposure in two patients with a tonsillar cancer (T2). The temporalis myofascial flap (TMF) was adopted to restore a competent velopharyngeal sphincter and a watertight seal between the pharynx and neck in a case of OPSCC involving part of soft palate and the anterior tonsillar pillar (T2). In 3 cases with extensive tumour of BOT involving tonsil and soft palate (T3), the surgical defect was reconstructed with an antero-lateral thigh (ALT) free flap.

Concurrent neck dissection was performed in 26 patients (43.3%). In 15 (25%) cases with high probability of fistula, a staged neck dissection was done after a mean of 27.7 ± 13.4 days (range 8-60). In 7 patients (11.7%), the neck dissection was previously done (-28.1 ± 11.5 days; range -41 to -12) because of the high risk of vascular injury or because the patient was referred to our institution for a primary tumour (unknown cases). The extent of dissection most commonly included levels IIa, IIb, III and IV. The ECS was noted in 24% of neck dissections, and the rate decreased in HPV-related OPSCC (21.4%).

Patients undergoing TORS-RT received a mean dose of 57 ± 5.6 Gy on T (range 50-66 Gy) and a mean of 51.4 ± 15.4 on N (range 0-60). In the TORS-CRT group, a mean dose of 59.7 ± 4.2 Gy of radiation was delivered on T, ranging from 54 to 66, and a mean dose of 59 ± 3.1 on N (range 54-66). Further, TORS-CRT group most commonly received a mean dose of 254.5 ± 46 mg/m^2 cisplatin (range 180-300).

The mean duration of follow-up for the 60 patients was 30.3 ± 26.9 months. The 5-year OS rate of the total group was 77.6%, in case of HPV-related OPSCC the 5-year OS increased to rate of 88.2%. The 5-year DFS rate was 85.2% (HPV+ group = 93.6%); the 5-year LRFS rate 90.6% (HPV+ group = 96.8%) and 5-year RRFS was 87.4% (HPV+ group = 93.6%).

Figure 1 shows the different survivals by HPV infection.

Data for the univariate and multivariate Cox regression model are shown in Table IV. Of note, at univariate analysis positive margins were predictive of regional relapses while HPV-related cancers were related to better OS. However, the statistical significance was lost in multivariate analysis for both factors. On the contrary, at multivariate analysis, tonsillar and BOT cancers were

Table I. Clinical TNM classification 7th ed.

	cN (%)					
cT	N0	N1	N2a	N2b	N2c	Total
Tx	0	1 (6.7)	3 (60)	4 (36.4)	1 (50)	9 (15)
T1	13 (48.2)	5 (33.3)	1 (20)	3 (27,3)	0	22 (36.7)
T2	11 (40.7)	8 (53.3)	1 (20)	3 (27.3)	0	23 (38.3)
T3	3 (11.1)	1 (6.7)	0	1 (9.1)	1 (50)	6 (10)
Total	27	15	5	11	2	60

Table II. New pathological TNM classification 8th ed. in HPV-/p16- OPSCC.

	pN (%)						
pT	N0	N1	N2a	N2b	N2c	N3b	Total
T0	0	1 (20)	0	0	0	0	1 (4.8)
T1	2 (33.3)	1 (20)	1	1 (50)	0	1 (16.7)	6 (29.6)
T2	3 (50)	3 (60%)	0	1 (50%)	1 (100)	3 (50)	11 (52.4)
T3	1 (16.7)	0	0	0	0	2 (33.3)	3 (14.3)
Total	6	5	1	2	1	6	21

Table III. New pathological TNM classification 8th ed. in HPV+/p16+ OPSCC.

	pN (%)			
pT	N0	N1	N2	Total
T0	0	1 (6.3)	0	1 (3.6)
T1	4 (40)	8 (50)	1 (50)	13 (46.4)
T2	4 (40)	6 (37.5)	1(50)	11 (39.3)
T3	2 (20)	1 (6.25)	0	3 (10.7)
Total	10	16	2	28

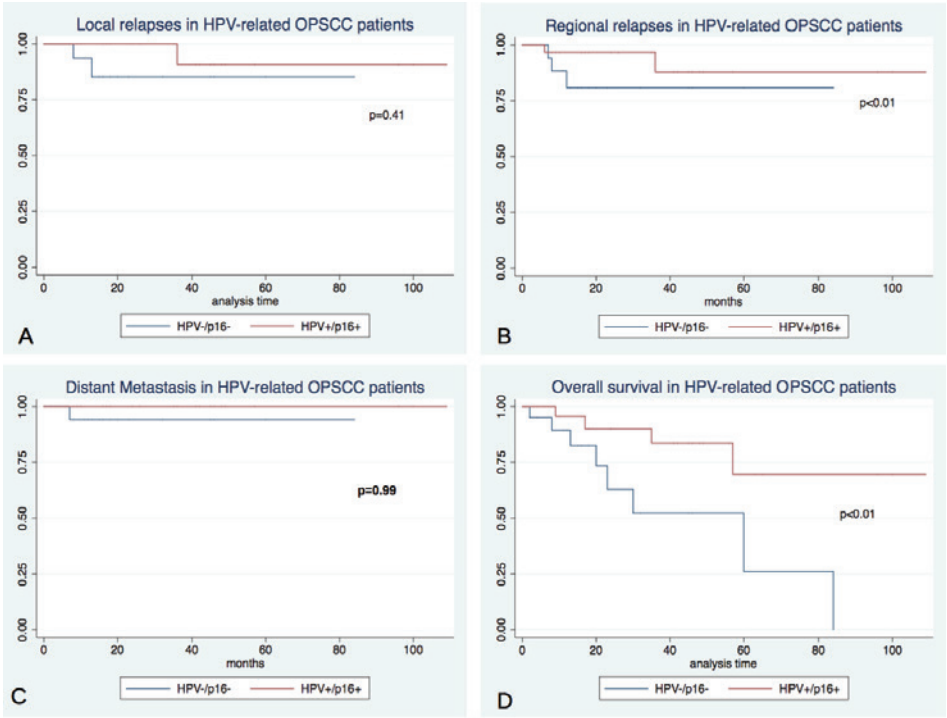

Fig. 1. A) Local Recurrence-Free Survival; **B)** Regional Recurrence-Free Survival; **C)** Distant Metastasis-Free Survival; **D)** Overall Survival.

significantly related with a high risk of neck recurrence, but should be considered a bias. In fact, 53 of 60 (88.3%) patients were palatine tonsil or BOT cancers; hence, if only both sites were considered, any statistical significance not correlating the site to any risk of neck recurrence was lost (HR = 6.1, p = 0.27, 95% CI = 0.24-156.06).

Regarding complications, we did not register any major or life-threatening intra-operative complications. Only one patient, who had concurrent neck dissection, experienced post-operative bleeding into the neck. Eight (13.3%) patients had post-operative bleeding from primary tumour resection field; 5 patients from tonsil and 3 from BOT. Oral bleeding had a mean of 6.2 ± 3.7 days. No total local or free flap failure were registered; whilst a partial necrosis of TMF that did not affect the healing and two flap dehiscences (1 FAMM and 1 ALT) that needed a surgical revision were recorded. Only the same ALT patient with flap dehiscence experienced pharyngocutaneous fistula that was treated with both surgical revision and compressive dressings. Tracheostomy was performed routinely in the first series of patients (15 cases until 2012). As our experience increased, tracheostomy was reserved only in difficult intubation cases, cT3 tumours, or cases who needed reconstruction with free flaps or local bulky flaps. The mean duration of tracheostomy use was 7.4 ± 2.6 days, and nasogastric tube 14.3 ± 6.9 days. Only one patient (pT3N2b of BOT invading tonsil and soft palate with ALT reconstruction) experienced a post-operative severe dysphagia, needing a permanent tracheostomy tube and percutaneous endoscopic gastrostomy (PEG) feeding.

Discussion

TORS is a fascinating new tool that is useful in the modern management of selected cases of OPSCC. In a systematic review of surgical and nonoperative therapy data for oropharyngeal SCC, Yeh et al. [6] found that TORS can achieve oncologic outcomes that compare favourably to primary RT, with an improved toxicity profile. In that review, TORS-based therapy OS was reported to range from 81%-100% and DFS from 85.7%-96%. Recently, Moore et al. [7] reported excellent outcomes with a 1, 3 and 5-year OS rate of 98%, 91% and 86%, DFS of 99%, 96% and 94%, and a local or regional disease-free survival rate of 95%, 93%, and 92%. Furthermore, Mahmoud et al. [8] demonstrated that 3-year survival was superior in patients undergoing TORS versus non-surgically treated patients (93% vs 83%, p < 0.001), although patients with HPV-positive disease showed no significant difference in sur-

Table IV.

Univariate and multivariate Cox regression model for local relapses						
	Univariate			Multivariate		
	HR	P value	95% CI	HR	P value	95% CI
Age	0.60	0.58	0.1-3.6	0.75	0.84	0.5-11.22
Tumour site	0.67	0.53	0.19-2.31	1.38	0.81	0.11-17.92
pT	1	1	0.3-3.25	2.39	0.36	0.37-15.31
pN	1.9	0.2	0.71-5	1.6	0.39	0.55-4.62
Margins	2	0.16	0.76-5.28	1.96	0.39	0.42-9.19
HPV	0.25	0.26	0.02-2.81	0.08	0.23	0.01-4.85
Univariate and multivariate Cox regression model for regional relapses						
	Univariate			Multivariate		
	HR	P value	95% CI	HR	P value	95% CI
Age	0.7	0.63	0.15-3.08	2.17	0.59	0.13-37.42
Tumour site	1.3	0.5	0.6-2.83	6.05	0.03	1.16-31.56
pT	1.54	0.39	0.57-4.17	16.2	0.11	0.53-493
pN	1.5	0.34	0.67-3.12	1.96	0.28	0.58-6.6
Margins	2.7	0.03	1.1-6.7	3	0.27	0.42-21.36
HPV	0.36	0.27	0.06-2.19	0.97	0.986	0.05-20.4
Univariate and multivariate Cox regression model for disease-free survival						
	Univariate			Multivariate		
	HR	P value	95% CI	HR	P value	95% CI
Age	0.92	0.9	0.23-3.66	2.83	0.35	0.32-24.9
Tumour site	1.15	0.71	0.54-2.47	2.93	0.13	0.73-11.85
pT	1.27	0.6	0.5-3.2	2.7	0.24	0.5-14.47
pN	1.65	0.17	0.81-3.32	2.27	0.11	0.83-6.19
Margins	2.14	0.06	0.98-4.67	1.59	0.45	0.48-5.27
HPV	0.27	0.14	0.05-1.51	0.43	0.51	0.03-5.28
Univariate and multivariate Cox regression model for overall survival						
	Univariate			Multivariate		
	HR	P value	95% CI	HR	P value	95% CI
Age	0.99	0.98	0.34-2.86	0.28	0.24	0.32-2.38
Tumour site	1.39	0.24	0.8-2.42	1.92	0.37	0.47-7.9
pT	1	0.99	0.44 2.28	1.57	0.68	0.18-13.88
pN	1.11	0.68	0.67-1.85	0.95	0.94	0.26-3.44
Margins	1.3	0.33	0.74-2.39	1.94	0.23	0.66-5.71
HPV	0.24	0.02	0.07-0.79	0.23	0.16	0.03-1.81
Neck Dissection	0.8	0.65	0.3-2.14	0.6	0.56	0.11-3.26
ECS	2.23	0.23	0.6-8.36	8.8	0.22	0.27-292.66
Radiotherapy	0.7	0.56	0.22- 2.25	1.24	0.86	13.6
Chemotherapy	0.21	0.13	0.03-1.6	0.03	0.164	0-3.9

HR: hazard ratio; 95% CI: confidence interval; ECS: Extra-capsular spread.

vival by treatment modality (p = 0.116), while the 3 year-survival advantage of TORS over definitive radiotherapy was only evident in the HPV-negative cohort (83% vs 66%, p = 0.2). Our data support these excellent outcomes as the 5-year DFS rate of 85.2% increased to 93.6% in case of HPV-related OPSCC, and a 5-year OS rate of 77.6% (HPV+ group = 88.2%).

An important consideration should be made about surgi-

cal margins in TORS for OPSCC. No universal definition of what constitutes an inadequate resection margin exists yet [9]. The guidelines from the American Society of Clinical Oncology (ASCO), National Comprehensive Cancer Network (NCCN) and European Oncology Institute (IEO) all define a close margin as 5 mm or less without any subsite distinction. A published survey of members of the American Head and Neck Society, regarding the definition of margins, revealed that the most common cutoff for a clear margin was greater than 5 mm on microscopic examination [10]. Alicandri-Ciufelli et al. [11], in their comprehensive review on surgical margins in the head and neck, reported that most studies use a margin distance of 5 mm or greater to define margin clearance, with the exception of glottic cancer in which there is long-standing consensus that resection margins may be as limited as 1 to 2 mm and still be considered adequate. For TORS resection of oropharyngeal tumours, Weinstein et al. [12] defined a margin of 2 mm or less to be considered close and those greater than 2 mm considered a free margin, which has been adopted at the authors' institution. Obviously, the positive margin rate after TORS for OPSCC widely varies in the literature (2-26%) [8 13]. In our study, we stated that clear margin was > 5 mm on microscopic evaluation, and thus we obtained 23.3% close margins and 20% positive margins.

This relative high positive margin rate, compared to outcomes at other institutions, might be affected by several factors. Our series also included all patients since the beginning of our robotic experience as well as T3 tumours that are not usually included in most published series. It is well known that the rate of clear margins increases with surgical experience; nevertheless, it is crucial to note that the experience of our pathologists in reporting clear margins increased with the workload over time. In fact, no dedicated head-neck pathologists are present in our institution. Furthermore, our hospital can be considered as a low volume centre. This issue is clearly evident in the literature. Cracchiolo et al. [13] reported that the incidence of positive margins was higher in lower volume than higher volume hospitals, but improves over time.

On the other hand, other authors have failed to find surgical margin status as a significant prognostic factor in head and neck cancer [14-17]. Reasons for failing to find a significant impact for margin status include other variables that have a greater impact on prognosis than margins, such as limitations in standard histopathology for assessment of margin status field cancerisation and effect of postoperative RT in negating the adverse impact of positive margins. In addition, technical issues during surgery, such as tearing of the specimen, tissue retraction, or shrinkage cautery effect around tumour margins may lead to close or positive margins on the pathology report, despite complete tumour resection. However, Molony et al. [18] showed that margin status had no impact on disease specific survival in patients with p16-positive disease. Similarly, Iyer et al. [19] reported that margin status predicted poorer survival in p16-negative patients, but not among patients who were p16- positive. Moreover, Kaczmar et al. [20] reported that margins < 2 mm did not lead to increased recurrence compared with margins > 2 mm in patients undergoing TORS. Regarding the survival, another study did not demonstrate any significant changes even after excluding TORS-treated patients with HPV-related OPSCC with positive surgical margins from 3-year survival analyses [8].

Usually tracheostomy is avoided in most (70-100%) cases, regardless of the use of adjuvant therapy [21], especially in early OPSCC even in case of local flap reconstruction. At many centres, tracheostomy was performed initially at the time of TORS in anticipation of airway oedema during the perioperative period; however, the majority of patients were decannulated within a few days. As the surgeons' experience increased, many of the centres moved away from routine tracheostomy at the time of TORS. In our experience, tracheostomy was routinely performed at the beginnings and then reserved to patients with difficult exposure or those with cT3 that needed regional or free flap reconstruction.

Additionally, TORS is usually associated with low morbidity rates and lower blood loss in comparison with open surgical procedures. These associated characteristics also reflect the shorter average hospital stays (4.2 days). The percutaneous endoscopic gastrostomy (PEG) dependency rate following TORS is 0-9.5% in 1 year and 0% in 2 years [22 23]. Another analysis of 177 patients from a multicentre study reported a long-term tracheostomy rate of 2.3%, and a long-term gastrostomy tube rate of 5%. The average duration of tracheostomy use was 7 days, and nasogastric tube 12.5 days [23]. Our study showed overlapping data. Amongst the TORS studies, the quality of life was investigated in only a few studies. Leonhardt et al. [23] demonstrated a decline in the eating, diet and speech domains from baseline at 6 months in the postoperative course, but these scores improved to baseline levels for eating and diet by 12 months. Lee et al. [24] showed improved dysphagia scores when comparing TORS to open surgery with mandibulotomy for patients with T1-T3 tonsil SCC. Dziegielewski et al. [25] demonstrated a decline in all scores at 3 weeks after surgery, with the lowest scores observed at 3 months in the postoperative course. Speech attitude, aesthetic, social and overall scores eventually returned to baseline, but speech function and aesthetic scores had only partial recovery and remained below baseline scores

at 12 months. Two studies included a comparison of quality of life (QOL) outcomes between TORS and RT. More et al. [26] found that the preoperative and 3 month postoperative MD Anderson Dysphagia Index (MDADI) scores were similar between the two groups. However, by 6 months and at the 12-month postoperative follow-up, patients treated with TORS and adjuvant therapy had significantly better MDADI scores. Chen et al. [27] compared QOL scales between patients who underwent initial surgical resection with either transoral laser microsurgery or TORS versus definitive CRT. At 1-year, there was no significant difference between the surgical group and the definitive chemoradiation group except for the swallowing score, which was better in the surgical group.

In one of the largest prospective studies of patients undergoing TORS [28], postoperative dysphagia improved significantly more quickly in the TORS-only group vs. patients who had adjuvant CRT. In summary, the TORS-only group had significantly better scores than the TORS+CRT group in the different QOL questionnaires. Similarly, Sethia et al. [29] showed that patients who underwent TORS alone had continued improvement in QOL in multiple domains shortly after surgery. These TORS-alone patients reported higher QOL scores in eating at 3 and 6 months postsurgery compared to adjuvant RT or CRT. TORS alone and adjuvant RT reported less social disruption than adjuvant CRT at 3 months, and TORS alone had higher speech scores compared to adjuvant CRT at 3 months and adjuvant RT at 6 months. Adjuvant CRT had lower overall QOL scores compared to adjuvant RT or TORS alone at baseline and 3 months, adjuvant RT at 3 weeks and TORS alone at 6 months. Although many patients in this study received PEG placement, it is important to note that the total number of patients with PEG dependence greatly diminished from 3 to 12 months. Thus, the majority of patients received PEG placement prophylactically as recommended by their radiation oncologist or as a direct result of dysphagia due to adjuvant therapy.

For what concerns surgical complications, fistula formation was noted in the series from the Mayo Clinic in 6% of cases. These patients underwent concurrent neck dissection at the time of TORS. In all four cases, the fistulae responded to treatment with daily packing and antibiotics [21 30]. Postoperative haemorrhage can be a life-threatening event in the case of TORS. The rate of postoperative haemorrhage varied 0% to 9% [31-35]. Chia et al. [36] summarised the common complications in a 2013 multi-institutional survey of all TORS-trained surgeons in the United States. An electronic survey was sent to 300 TORS-trained surgeons. Forty-five surgeons responded to the survey and reported a postoperative haemorrhage rate of 3.1% requiring readmission. There were a total of 6 deaths among

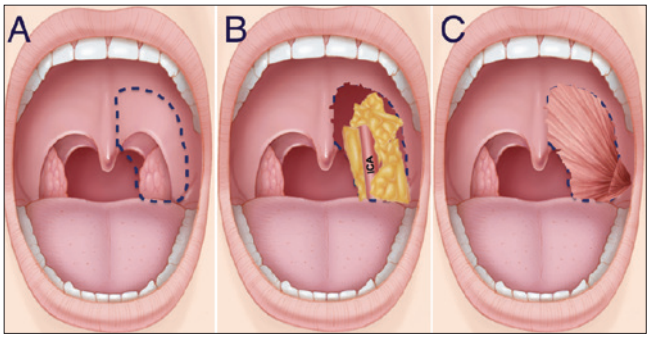

Fig. 2. Schematic illustration of the oropharyngeal resection suitable for reconstruction with the temporalis muscle flap. **A)** The dotted line shows the surgical resection of the area that includes part of the soft palate and the lateral pharyngeal wall; **B)** The surgical defect with internal carotid artery exposure; **C)** The temporalis muscle flap reconstruction covering the lateral pharyngeal wall and restoring the soft palate.

2015 procedures (0.3%). Other complications included temporary hypoglossal nerve injury (0.9%), lingual nerve injury (0.6%) and tooth injury (1.4%).

For what concerns reconstructive options, the majority of robotic surgeons favour leaving the oropharyngeal defects to heal by secondary intention following TORS for early OPSCC (cT1-2). However, surgical resection inevitably affects the native function of the oropharynx; therefore our group advocates the use of NBI in order to obtain free margins and reduce over-resections, consequently minimising the risk of functional impairments [4]. Among existing classification schemes for oropharyngeal defects, the reconstructive algorithm developed by de Almeida et al. [37] seems to be easier to apply in the robotic surgery framework. In our experience, we satisfactorily used FAMM and BMM for class I/II defects [38]. Additionally, in a case of class III defect our group successfully adopted the TMF (Fig. 2) to restore a competent velopharyngeal sphincter and a watertight seal between the pharynx and neck [39]. In cases of class IV defects, we used the ALT harvested in a particular petal shape that allows one petal to replace the rear side of the palate, one for the front side of the palate and the tonsillar fossa and the third petal to reconstruct the BOT. Flap insetting is the most challenging phase due to severely restricted physical access and visualisation. However, in our experience the accurate shape and measure of the flap allow to thoroughly perform manual inset, although the robot might be used for suturing parts of flap in deeper and narrower spaces.

From an economical point of view, comparing the cost of TORS to the cost of primary radiotherapy is more challenging. In a comparative study, de Almeida et al. [40] performed an extensive cost-analysis, comparing the cost of TORS versus that of primary RT for the management of early T-classification oropharyngeal cancer. Their study accounted

for variations in adjuvant therapy, costs, utilities, complications and recurrence rates. TORS demonstrated a cost savings of $ 1,366. However, the cost-effectiveness of TORS is unlikely to be realised if used in an unselected fashion. This concept was demonstrated in three recent cost-effectiveness studies comparing TORS and radiotherapy for various populations of OPSCC [40-42]. The results of each study, although varied in their conclusions, demonstrate significant sensitivity to the frequency of adjuvant therapy. This implies that the use of TORS in unselected patients who are likely to require adjuvant therapy is unlikely to be a cost-effective strategy. Thus, patient selection is the key to the useful application of this modality. Furthermore, the recognition of OPSCC subgroups that would most likely benefit from TORS alone or with adjuvant treatments would be advisable in order to provide a significant treatment opportunity with fewer complications and better quality of life.

Conclusions

In selected patients TORS appears to yield similar oncologic outcomes and functional outcomes to traditional techniques and non-operative treatment with a possible benefit on long-term quality of life. Our data demonstrate comparable treatment outcomes to other published larger series. In our practice, TORS is easy and safe, and reconstruction with flaps might increase the surgical indications without compromising oncological and functional outcomes.
The future offers exciting opportunities to combine TORS and radiotherapy in unique ways. However, further research is needed to clarify the indications for and delivery of adjuvant therapy following TORS resections.

Conflict of interest statement

None declared.

References

1. Ward MC, Koyfman SA. *Transoral robotic surgery: the radiation oncologist's perspective.* Oral Oncol 2016;60:96-102.
2. Setton J, Lee NY, Riaz N, et al. *A multi-institution pooled analysis of gastrostomy tube dependence in patients with oropharyngeal cancer treated with definitive intensity-modulated radiotherapy.* Cancer 2015;121:294-301.
3. FDA 510(k) summary. 2009. www.accessdata.fda.gov/cdrh_docs/pdf9/K090993.pdf [accessed November 18, 2015].
4. Vicini C, Montevecchi F, D'Agostino G, et al. *A novel approach emphasising intra-operative superficial margin enhancement of head-neck tumours with narrow-band imaging in transoral robotic surgery.* Acta Otorhinolaryngol Ital 2015;35:157-61.
5. De Vito A, Meccariello G, Vicini C. *Narrow band imaging as screening test for early detection of laryngeal cancer: a prospective study.* Clin Otolaryngol 2017;42:347-53.
6. Yeh DH, Tam S, Fung K, et al. *Transoral robotic surgery vs. radiotherapy for management of oropharyngeal squamous cell carcinoma - a systematic review of the literature.* Eur J Surg Oncol 2015;41:1603-14.
7. Moore EJ, Van Abel KM, Price DL, et al. *Transoral robotic surgery for oropharyngeal carcinoma: surgical margins and oncologic outcomes.* Head Neck 2018;40:747-55.
8. Mahmoud O, Sung K, Civantos FJ, et al. *Transoral robotic surgery for oropharyngeal squamous cell carcinoma in the era of human papillomavirus.* Head Neck 2018;40:710-21.
9. Sim FW, Xiao HD, Bell RB. *Margin analysis: squamous cell carcinoma of the oropharynx.* Oral Maxillofac Surg Clin North Am 2017;29:269-80.
10. Meier JD, Oliver DA, Varvares MA. *Surgical margin determination in head and neck oncology: current clinical practice. The results of an International American Head and Neck Society Member Survey.* Head Neck 2005;27:952-8.
11. Alicandri-Ciufelli M, Bonali M, Piccinini A, et al. *Surgical margins in head and neck squamous cell carcinoma: what is 'close'?* Eur Arch Otorhinolaryngol 2013;270:2603-9.
12. Weinstein GS, O'Malley BW Jr, Magnuson JS, et al. *Transoral robotic surgery: a multicenter study to assess feasibility, safety, and surgical margins.* Laryngoscope 2012;122:1701-7.
13. Cracchiolo JR, Baxi SS, Morris LG, et al. *Increase in primary surgical treatment of T1 and T2 oropharyngeal squamous cell carcinoma and rates of adverse pathologic features: National Cancer Data Base.* Cancer 2016;122:1523-32.
14. Barry CP, Ahmed F, Rogers SN, et al. *Influence of surgical margins on local recurrence in T1/T2 oral squamous cell carcinoma.* Head Neck 2015;37:1176-80.
15. McMahon J, O'Brien CJ, Pathak I, et al. *Influence of condition of surgical margins on local recurrence and disease-specific survival in oral and oropharyngeal cancer.* Br J Oral Maxillofac Surg 2003;41:224-31.
16. Molteni G, Valerini S, Alicandri-Ciufelli M, et al. *Unravelling the risk factors that underlie oral and oropharyngeal surgery in elderly.* Acta Otorhinolaryngol Ital 2018;38:409-16.
17. Cadoni G, Giraldi L, Petrelli L, et al. *Prognostic factors in head and neck cancer: a 10-year retrospective analysis in a single-institution in Italy*. Acta Otorhinolaryngol Ital 2017;37:458-66.
18. Molony P, Kharytaniuk N, Boyle S, et al. *Impact of positive margins on outcomes of oropharyngeal squamous cell carcinoma according to p16 status.* Head Neck 2017;39:1680-8.
19. Iyer NG, Dogan S, Palmer F, et al. *Detailed analysis of clinicopathologic factors demonstrate distinct difference in outcome and prognostic factors between surgically treated HPV-positive and negative oropharyngeal cancer.* Ann Surg Oncol 2015;22:4411-21.
20. Kaczmar JM, Tan KS, Heitjan DF, et al. *HPV-related oropharyngeal cancer: risk factors for treatment failure in pa-*

tients managed with primary transoral robotic surgery. Head Neck 2016;38:59-65.

21 Moore EJ, Olsen KD, Kasperbauer JL. *Transoral robotic surgery for oropharyngeal squamous cell carcinoma: a prospective study of feasibility and functional outcomes.* Laryngoscope 2009;119:2156-64

22 White HN, Moore EJ, Eosental EL, et al. *Transoral robotic-assisted surgery for head and neck squamous cell carcinoma: one- and 2-year survival analysis.* Arch Otolaryngol Head Neck Surg 2010;136:1248-52.

23 Leonhardt FD, Quon H, Abrahao M, et al. *Transoral robotic surgery for oropharyngeal carcinoma and its impact on patient-reported quality of life and function.* Head Neck 2012;34:146-54.

24 Lee SY, Park YM, Byeon HK, et al. *Comparison of oncologic and functional outcomes after transoral robotic lateral oropharyngectomy versus conventional surgery for T1 to T3 tonsillar cancer.* Head Neck 2014;36:1138-45.

25 Dziegielewski PT, Teknos TN, Durmus K, et al. *Transoral robotic surgery for oropharyngeal cancer.* JAMA Otolaryngol Neck Surg 2013;139:1099-108.

26 More YI, Tsue TT, Girod DA, et al. *Functional swallowing outcomes following transoral robotic surgery vs primary chemoradiotherapy in patients with advanced-stage oropharynx and supraglottis cancers.* JAMA Otolaryngol Neck Surg 2013;139:43-8.

27 Chen AM, Daly ME, Luu Q, et al. *Comparison of functional outcomes and quality of life between transoral surgery and definitive chemoradiotherapy for oropharyngeal cancer.* Head Neck 2015;37:381-5.

28 Achim V, Bolognone RK, Palmer AD, et al. *Long-term functional and quality-of-life outcomes after transoral robotic surgery in patients with oropharyngeal cancer.* JAMA Otolaryngol Head Neck Surg 2017. doi: 10.1001/jamaoto.2017.1790. [Epub ahead of print].

29 Sethia R, Yumusakhuylu AC, Ozbay I, et al. *Quality of life outcomes of transoral robotic surgery with or without adjuvant therapy for oropharyngeal cancer.* Laryngoscope 2018;128:403-11.

30 Moore EJ, Olsen SM, Laborde RR, et al. *Long-term functional and oncologic results of transoral robotic surgery for oropharyngeal squamous cell carcinoma.* Mayo Clin Proc 2012;87:219-25.

31 Lorincz BB, Mockelmann N, Busch CJ, et al. *Functional outcomes, feasibility, and safety of resection of transoral robotic surgery: single-institution series of 35 consecutive cases of transoral robotic surgery for oropharyngeal squamous cell carcinoma.* Head Neck 2015;37:1618-24.

32 Lee SY, Park YM, Byeon HK, et al. *Comparison of oncologic and functional outcomes after transoral robotic lateral oropharyngectomy versus conventional surgery for T1 to T3 tonsillar cancer.* Head Neck 2014;36:1138-45.

33 Weinstein GS, Quon H, Newman H, et al. *Transoral robotic surgery alone for oropharyngeal cancer: an analysis of local control.* Arch Otolaryngol Head Neck Surg 2012;138:628-4.

34 Olsen SM, Moore EJ, Laborde RR, et al. *Transoral surgery alone for human-papillomavirus-associated oropharyngeal squamous cell carcinoma.* Ear Nose Throat J 2013;92:76-83.

35 Dean NR, Rosenthal EL, Carroll WR, et al. *Robotic-assisted surgery for primary or recurrent oropharyngeal carcinoma.* Arch Otolaryngol Head Neck Surg 2010;136:380-4.

36 Chia SH, Gross ND, Richmon JD. *Surgeon experience and complications with Transoral Robotic Surgery (TORS).* Otolaryngol Head Neck Surg 2013;149:885-92.

37 de Almeida JR, Park RCW, Villanueva NL, et al. *Reconstructive algorithm and classification system for transoral oropharyngeal defects.* Head Neck 2014;36:934-41.

38 Meccariello G, Montevecchi F, Sgarzani R, et al. *The reconstructive options for oropharyngeal defects in the transoral robotic surgery framework.* Oral Oncol 2017;66:108-11.

39 Meccariello G, Montevecchi F, Deganello A, et al. *The temporalis muscle flap for reconstruction of soft palate and lateral oropharyngeal wall after transoral robotic surgery.* Auris Nasus Larynx 2018;45:162-4.

40 de Almeida JR, Moskowitz AJ, Miles BA, et al. *Cost-effectiveness of transoral robotic surgery versus (chemo)radiotherapy for early T classification oropharyngeal carcinoma: a cost-utility analysis.* Head Neck 2016;38:589-600.

41 Sher DJ, Fidler MJ, Tishler RB, et al. *Cost-effectiveness analysis of chemoradiation therapy versus transoral robotic surgery for human papillomavirus-associated, clinical N2 oropharyngeal cancer.* Int J Radiat Oncol Biol Phys 2016;94:512-22.

42 Rudmik L, An W, Livingstone D, et al. *Making a case for high-volume robotic surgery centers: a cost-effectiveness analysis of transoral robotic surgery.* J Surg Oncol 2015;112:155-63.

Received: May 16, 2018 - Accepted: September 15, 2018

How to cite this article: Meccariello G, Montevecchi F, D'Agostino G, et al. *Trans-oral robotic surgery for the management of oropharyngeal carcinomas: a 9-year institutional experience.* Acta Otorhinolaryngol Ital 2019;39:75-83. https://doi.org/10.14639/0392-100X-2199

Address for correspondence: Giuseppe Meccariello, Department of Head-Neck Surgery, Otolaryngology, Head-Neck and Oral Surgery Unit, Morgagni Pierantoni Hospital, via Carlo Forlanini 34, 47100 Forlì, Italy. Tel. +39 0543 735651. Fax +39 0543 735660. E-mail: drmeccariello@gmail.com

OPEN ACCESS

HEAD AND NECK

Long-term disease-free survival in surgically-resected oral tongue cancer: a 10-year retrospective study

Sopravvivenza libera da malattia a lungo termine nel tumore della lingua mobile operato: studio retrospettivo a 10 anni

A. MARRA[1], M. VIOLATI[1], F. BROGGIO[1], C. CODECÀ[1], M. BLASI[1], A. LUCIANI[1], S. ZONATO[1], D. RABBIOSI[2], L. MONEGHINI[3], A. SAIBENE[4], A. MACCARI[4], G. FELISATI[4], D. FERRARI[1]

[1] Medical Oncology Unit, [2] Maxillo-Facial Surgery Unit, [3] Pathology Unit, [4] Otolaryngology Unit, ASST Santi Paolo e Carlo, University of Milan, Italy

SUMMARY

Early and loco-regionally advanced oral tongue squamous cell carcinoma (OTSCC) can be treated by surgery alone or followed by adjuvant radiotherapy or chemoradiotherapy. Nevertheless, up to 40% of patients develop tumour relapse. The aim of our study is to investigate the clinical and pathological features associated with reduced disease-free survival (DFS) in a cohort of surgically-resected OTSCC patients. One hundred and six patients surgically resected for OTSCC were retrospectively identified from clinical records. DFS was calculated according to the Kaplan–Meier method and differences between variables were assessed with Log-Rank test. A multivariable Cox regression model was used to analyse the impact of different prognostic factors on DFS. After a median of follow-up of 8.9 years, 22 events, including 11 deaths, were observed. Overall, the 5-year DFS-rate was 87.4%. The presence of extra-nodal extension (p = 0.023) and perineural invasion (p = 0.003) were significantly correlated with shorter DFS (in univariate analysis). In multivariable analysis, extra-nodal extension and perineural invasion confirmed their role as independent prognostic factors associated with an increased risk of disease recurrence [hazard ratio (HR) 2.87, 95% CI 1.11 - 7.42, p = 0.03; HR 3.85, 95% CI 1.49 - 9.96, p = 0.006, respectively]. p16 and p53 expressions in tumour cells were detected in 12% (n = 9) and 46% (n = 40) of cases, respectively. No differences in DFS were observed between p16+ and p16- (p = 0.125) and between p53+ and p53- tumours (p = 0.213). In conclusion, radical surgery, eventually followed by adjuvant radiotherapy or chemo-radiotherapy, can achieve high cure rates in OTSCC. After long-term follow-up, perineural invasion and extra-nodal extension confirmed their role as prognostic factors associated with reduced DFS in OTSCC patients.

KEY WORDS: Oral cancer • Tongue cancer • Head and neck squamous cell carcinoma • p53 • p16

RIASSUNTO

Il tumore della lingua mobile, in fase iniziale o localmente avanzata, può essere trattato mediante chirurgia, da sola o seguita da radioterapia o chemio-radioterapia. Tuttavia, fino al 40% dei pazienti sviluppa una recidiva di malattia. Lo scopo del nostro studio è quello di valutare le caratteristiche anatomo-patologiche e cliniche associate ad una ridotta sopravvivenza libera da malattia (DFS) in pazienti con tumore della lingua mobile sottoposti a chirurgia. Sono stati identificati 106 pazienti operati per tumore della lingua mobile. Dopo un follow-up mediano di 8,9 anni, sono stati osservati 22 eventi, incluse 11 morti. Il tasso di DFS a 5 anni è stato dell'87,4%. La presenza di estensione extranodale (p = 0,023) ed invasione perineurale (p = 0,003) erano significativamente correlate ad una DFS ridotta (analisi univariata). Nell'analisi multivariata, sia l'estensione extranodale che l'invasione perineurale hanno confermato il loro ruolo quali fattori prognostici associati ad un aumentato rischio di recidiva di malattia [Hazard Ratio (HR) 2,87, 95% CI 1,11 - 7,42, p = 0,03; HR 3,85, 95% CI 1,49 - 9,96, p = 0,006]. L'espressione di p16 e p53 è stata identificata nel 12% (n = 9) e 46% (n = 40) dei casi, rispettivamente. Non sono state identificate differenze in termini di sopravvivenza tra tumori p53+ e p53-, né tra tumori p16+ e p16-. In conclusione, la chirurgia primaria, eventualmente seguita da radioterapia o chemio-radioterapia, può consentire alti livelli di guarigione nel tumore della lingua mobile. L'invasione perineurale e l'estensione extra-nodale si sono confermati fattori prognostici correlati ad una minore DFS.

PAROLE CHIAVE: *Tumori del cavo orale • Tumore della lingua • Tumori della testa e del collo • p53 • p16*

Introduction

Oral tongue squamous cell carcinoma (OTSCC) is the most common cancer diagnosed in the oral cavity, accounting for 25-40% of all oral malignancies [1]. In the United States, almost 17,000 new cases and 2,500 OTSCC-related deaths are expected in 2018 [2]. OTSCC is burdened by significant morbidity and mortality and its incidence is continuously arising, particularly in young subjects [3 4]. Despite advances in detection and treatment, 5-year overall survival (OS) and disease-free survival (DFS) are steadily in the range of 50-60% [1 5]. The pathogenesis of OTSCC is related to several factors involved

© Società Italiana di Otorinolaringoiatria e Chirurgia Cervico-Facciale

in the carcinogenetic process such as heat, chronic injuries, poor oral hygiene, cigarette smoking and alcohol consumption [6]. Moreover, OTSCC is characterised by a high frequency of lymphatic metastasis, a high risk of recurrence and the possibility to develop drug resistance to chemotherapy during treatment [7].

Clinical outcomes strictly correlate with disease stage and lymph node spread at the time of presentation. Moreover, some characteristics, such as tumour depth, vascular and perineural invasion (PNI) and tumour budding are widely recognised as prognostic factors [8-13]. Conversely, the impact on survival of other features, including anatomic site, age, tumour grade and some biological markers is still uncertain, depending on the great variability among reports in the literature, which is mainly represented by limited case series [14 15]. A further confusing factor is the evaluation of oral tongue cancers either in series including base of tongue tumours or in series reporting a combination of cancers from different sites in the head and neck district. The management and outcomes of each subsite tend to be different [16 17].

Surgery is the standard treatment for early OTSCC. Locally and loco-regionally advanced cases can be treated by surgery and adjuvant radiotherapy (RT) or chemoradiotherapy (CRT) according to the presence of risk factors such as lymph node metastases, extra-nodal extension (ENE) and involved surgical margins [18 19]. Alternatively, primary concomitant CRT can be offered to patients with the aim of sparing organ function.

In this study, we retrospectively evaluated the role of surgery on clinical outcomes in a cohort of patients affected by OTSCC treated at our institution in the last decade.

Materials and methods

Study setting

This was a monocentric, retrospective, independent study on patients with surgically-resected OTSCC treated and followed at San Paolo Hospital (Milan, Italy) between July 2004 and December 2012. Demographic data, risk factors, tumour characteristics and disease status were obtained from medical records. The study was approved by local Ethics Committee. All patients alive at the time of data collection and/or analysis signed an informed consent for use of personal data.

All pathological specimens were reviewed by two independent pathologists to confirm diagnosis and evaluate tumour depth, grade of tumour cell differentiation, presence of perivascular invasion and PNI, marginal status and the presence of ENE. Tumour size and nodal involvement were categorised according to the American Joint Committee on Cancer (AJCC) TNM staging (7th Edition, 2009).

All cases were previously discussed and evaluated by a multidisciplinary team, consisting minimally of an oncologist, surgeon, radiotherapist, and dedicated radiologists and pathologists. Patients with localised or loco-regional disease were treated by radical surgery, consisting of tumour resection +/- lymph node neck dissection. The decision to proceed with lymph node neck dissection was taken after careful evaluation of nodal involvement at baseline imaging or as a consequence of pathological diagnosis. Patients with a tumour depth greater than 3 mm were deferred to elective neck dissection [20]. Patients with positive or close surgical margins, defined as the presence of tumour cells at the margin or within 5 mm, received surgical re-intervention (whenever possible) or RT/CRT. Patients at risk of relapse (node metastases, ENE, critical margins) were treated with adjuvant RT or CRT, according to national and international guidelines [18 21].

Patients were then referred to the Oncology Unit for follow-up. Each follow-up visit included physical examination, blood tests and CT scan or MRI of the head and neck region (every 3 months during the first 2 years, and then every 6 to 12 months).

Study population

Eligibility criteria were: (1) age ≥18 years; (2) pathologically confirmed diagnosis of resected OTSCC; (3) ECOG performance status (PS) of 0-2; (4) available data on risk factors, tumour characteristics and patient outcomes. Patients with (1) distant metastases at baseline imaging and/or (2) primary tumour of the tongue base or other sites of the head and neck district were not included in the study.

Objectives

The main objective of the study was to investigate the impact of clinical and pathological characteristics on survival of patients with completely resected OTSCC. The primary endpoint was disease-free survival (DFS), defined as the time from surgery until the date of relapse, date of death or last follow-up visit, whichever occurred first. The secondary endpoint was overall survival (OS), defined as the time from surgery until the date of death.

Immunohistochemistry for p16 and p53

Immunohistochemistry (IHC) was performed according to standard protocols at our institution. Formalin-fixed, paraffin-embedded tissue sections (4 μm) from OTSCC tumour samples were used as substrates in IHC reactions. IHC staining with monoclonal antibodies (mAbs) labeled for $p16^{INK4A}$ (clone E6H4, Dako, Glostrup, Denmark) and

p53 (clone DO-7, Thermo Fisher Scientific, MA, US) was performed, as previously described [22 23]. Tumour slides were evaluated and classified by two pathologists. Positive p16 and p53 expressions were defined as the presence of strong and diffuse nuclear and cytoplasmic staining in more than 70% of tumour cells.

Statistical analysis

Demographic and clinical-pathological features were analysed using descriptive statistics. Absolute frequency and percentage were used to describe categorical variables, while median and interquartile range were reported for continuous variables. DFS was estimated using the Kaplan-Meier method and differences between variables were assessed with the Log-Rank test (univariate analysis). Cox proportional hazard regression models were used to evaluate the association between demographic and clinical-pathological variables and the survival endpoint. Statistical tests were two-sided and *p*-value less than 0.05 was considered as statistically significant. All the analyses were performed using SAS software v. 9.4 (SAS Institute, Cary, NC, US).

Results

Between July 2004 and December 2012, 106 OTSCC patients were included in the study. Patient characteristics are summarised in Table I.

Median age was 61 years (interquartile range = 51-69). Sixty-eight patients (64.1%) were male. Most patients presented with pT1 and pT2 disease (n = 56, 52.8%, and n = 31, 29.2%, respectively), while only a minority with pT3 and pT4 disease (n = 5, 4.7%, and n = 14, 13.2%, respectively). A tumour depth greater than 3 mm was found in 74 cases (69.8%). Nodal involvement was detected in 37 patients (34.9%), with the presence of ENE in 16 tumours (15.1%). Tumours were well/moderately or poorly differentiated in 83 (78.3%) and 23 (21.7%) cases, respectively. PNI and perivascular invasions were detected in 13 (12.2%) and 9 (8.4%) tumours, respectively. Close or positive surgical margins were present in 17 (16.0%) cases.

Overall, 63 patients (59.4%) were diagnosed with stage I or II disease, while stages III and IV were present in 14 (13.2%) and 29 (27.4%) cases, respectively. Regarding neck management, 82 patients (77.3%) underwent neck dissection, concomitant to or deferred with respect to radical surgery. Sixty patients did not receive any postoperative treatment. Conversely, 27 (25.5%) and 19 (17.9%) patients received postoperative RTX or CRT, respectively, according to the presence of risk factors as previously described.

Table I. Baseline characteristics (N = 106).

	N	%
Age		
Median (IQR)	61 (51-69)	
< 40 years	14	13.2
≥ 40 years	92	86.8
Sex		
Male	68	64.1
Female	38	35.9
Smoker		
No	31	29.2
Yes	75	70.8
Neck dissection		
No	24	22.6
Yes	82	77.4
Tumour		
pT1/2	87	82.1
pT3/4	19	17.9
pT1	56	52.8
pT2	31	29.2
pT3	5	4.7
pT4	14	13.2
Node		
pN0/X	69	65.1
pN1/2/3	37	34.9
pNX	25	23.6
pN0	44	41.5
pN1	13	12.3
pN2	23	21.7
pN3	1	0.9
Stage		
I/II	63	59.4
III/IV	43	40.6
I	46	43.4
II	17	16.0
III	14	13.2
IV	29	27.4
ENE		
Missing	3	2.8
No	87	82.1
Yes	16	15.1
Depth		
< 3 mm	32	30.2
≥ 3 mm	74	69.8
Vascular invasion		
Missing	3	2.8
No	94	88.7
Yes	9	8.5

continues ▶

Table I. *follows.*

	N	%
Perineural invasion		
Missing	3	2.8
No	90	84.9
Yes	13	12.3
Tumour differentiation		
G1/2	83	78.3
G3	23	21.7
Margins		
No	89	84.0
Yes	17	16.0
Postoperative treatment		
None	60	56.6
RT	27	25.5
CRT	19	17.9

CRT: chemo-radiotherapy ENE: extra-nodal extension; IQR: interquartile range; RT: radiotherapy.

To evaluate any difference between age and clinical-pathological features, patients were subdivided into 2 age groups: <40 and ≥40 years (n = 14, 13.21% and n = 92, 86.79%, respectively). No significant differences in terms of tumour characteristics were observed between the two groups.

Survival analysis

Three patients were excluded from survival analysis due to the lack of information about the time of disease progression and/or death.

After a median of follow-up of 8.9 years (5.3 - 11.4), 22 (21.4%) events occurred, including 11 (10.7%) deaths (Table II).

In the first five years of follow-up, 13 tumour relapses, including 11 deaths, were observed. The 5-year DFS and OS rates were 87.4% and 91.3%, respectively.

Using log-rank test, no significant differences in terms of DFS were observed for age groups (p = 0.222), smoking status (p = 0.193), tumour size (p = 0.407), nodal involvement (p = 0.379), tumour depth (p = 0.161), vascular invasion (p = 0.291), tumour differentiation (p = 0.062) and surgical margins (p = 0.064). Conversely, the presence of ENE (p = 0.023) and PNI (p = 0.003) were significantly correlated with shorter DFS (Fig. 1).

In multivariable Cox regression analysis, the presence of ENE [Hazard Ratio (HR) 2.87, 95% CI 1.11 - 7.42, p = 0.03] and PNI (HR 3.85, 95% CI 1.49 - 9.96, p = 0.006) were significantly associated with a higher risk of disease recurrence (Table III).

Regarding OS, in the multivariable Cox regression analysis, no significant differences were detected for age groups (p = 0.837), smoking status (p = 0.526), PNI (p = 0.178), ENE (p = 0.961), nodal involvement (p = 0.553), tumour depth (p = 0.515), tumour size (P = 0.751), vascular invasion (p = 0.753), tumour differentiation (p = 0.087) and surgical margins (p = 0.702).

Analysis for p16 and p53 expressions

Of the 106 tumours examined, 75 tissue samples were available for evaluation of p16 and p53 expression, which was present in 12% (n = 9) and 46% (n = 40) of the samples, respectively. However, no significant correlations with clinical features were observed.

In univariate analysis, no differences in terms of DFS and OS were observed between p16+ and p16- (p = 0.125), as well as between p53+ and p53- tumours (p = 0.213).

Discussion

Radical surgery, eventually followed by RT or CRT, is the standard treatment for OTSCC leading to about a 70% probability of cure in the early stages [18]. Loco-regionally advanced disease still has a dismal prognosis and less than half of patients have a real chance of cure [24]. An integrated approach consisting of multimodality diagnostic and therapeutic workup is mandatory for high risk patients, defined by the presence of aggressive features such as advanced primary tumour (T3 or T4), number and sites of

Table II. DFS and OS events according to different stages of disease.

Stage	DFS events		OS events	
	No N (%)	Yes N (%)	No N (%)	Yes N (%)
I	35 (33.9)	10 (9.7)	42 (40.8)	3 (2.9)
II	15 (14.6)	2 (1.9)	16 (15.5)	1 (0.9)
III	11 (10.7)	1 (0.9)	12 (11.6)	0 (0.0)
IV	20 (19.4)	9 (8.7)	22 (21.4)	7 (6.9)
Total	81 (78.6)	22 (21.4)	92 (89.3)	11 (10.7)

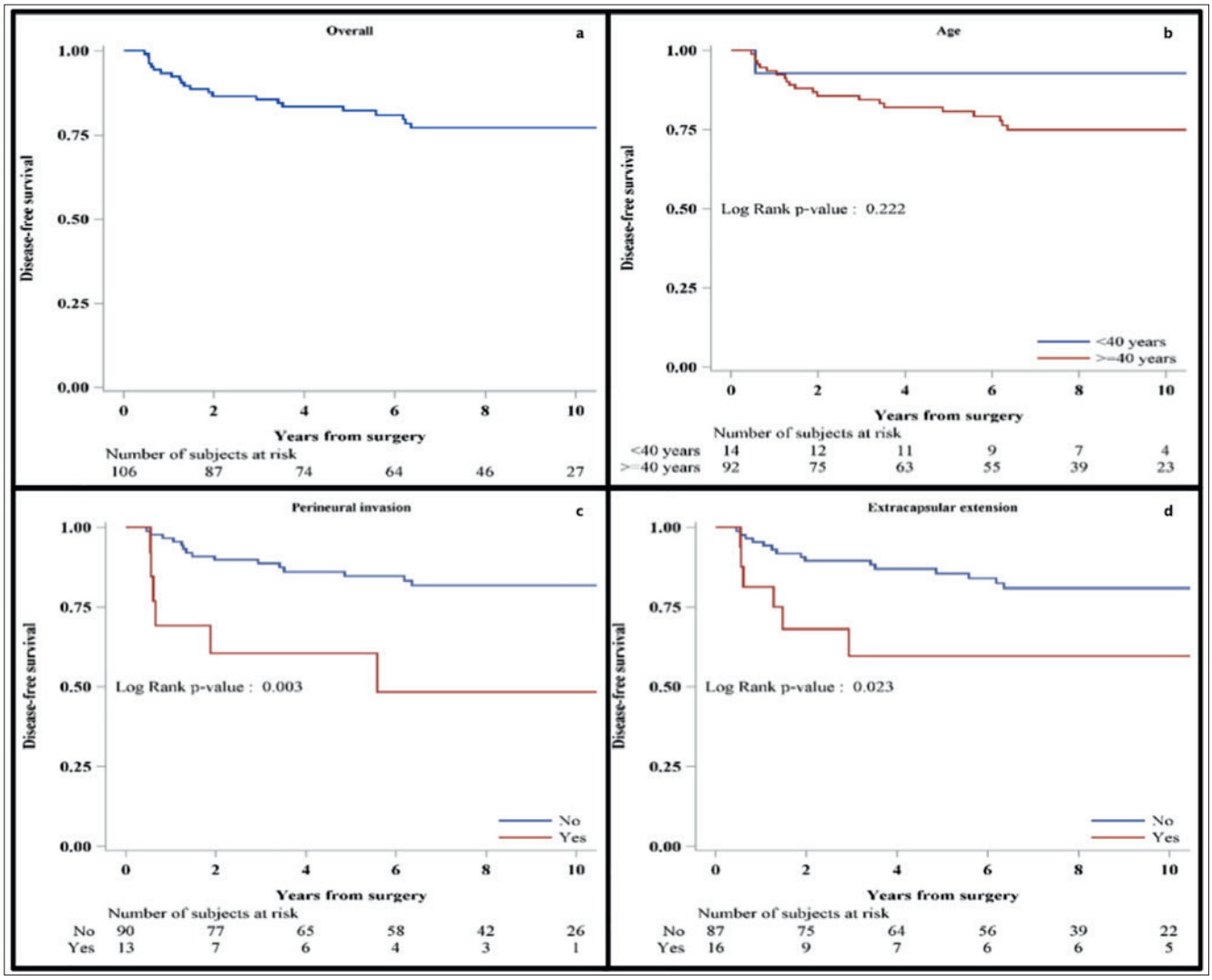

Fig. 1. Disease-free survival (DFS) in the overall population (a), and according to age (b), perineural invasion (c) and extracapsular extension (d).

lymph node involvement, ENE, PNI, vascular infiltration, poor tumour differentiation and incomplete surgery [8-13]. Although many studies have evaluated the role of multimodality treatment in head and neck cancers, only a few have focused on the impact of surgery and (chemo)radiation in tongue cancer exclusively.

We retrospectively analysed 106 OTSCC patients to identify risk factors associated with a reduced survival. The features of our population are in line with data available in the literature. Most of our patients had small tumours (especially pT1 and pT2), but nodal involvement was detected in about one-third of cases.

To detect differences in clinical-pathological features of disease presentation and recurrence, we subdivided the population in two cohorts in relation to age (< 40 and ≥ 40 years). However, we found no difference between the two age groups. In the 14 patients in the youngest group, only one subject had disease recurrence in the observation period. We are aware that this could be related to the low percentage of young subjects in our population, nonetheless young age seems to consistently correlate with improved prognosis. Regarding survival differences between young and older OTSCC patients, contrasting data have been provided so far. Some authors reported that young subjects present worse survival outcomes than the elderly, justifying more intensive treatments in this subgroup [25-28]. Conversely, other studies demonstrated the absence of difference in terms of higher risk of disease recurrence or worse survival in young (< 40 years) OTSCC patients [29]. On the other hand, some authors have highlighted the role of aging in poor prognosis [30] and the negative impact of comorbidities on elderly patients in terms of OS and postsurgical compli-

Table III. Cox regression analysis for disease-free survival (DFS).

	N	Events/PY	HR	95% CI	P-value
Age					
< 40 years	14	1/106	3.26	0.44-24.23	0.25
≥ 40 years	92	21/625			
Smoker					
No	31	4/240	2.03	0.69-5.99	0.20
Yes	75	18/491			
pT					
pT1/2	87	17/620	1.52	0.56-4.13	0.41
pT3/4	19	5/112			
pN					
pN0/X	69	13/498	1.46	0.62-3.42	0.38
pN1/2/3	37	9/234			
ENE*					
No	87	15/625	2.87	1.11-7.42	0.03
Yes	16	6/86			
Depth					
< 3	32	4/245	2.13	0.72-6.30	0.17
≥ 3	74	18/487			
Vascular invasion*					
No	94	18/657	1.91	0.56-6.50	0.30
Yes	9	3/54			
Perineural invasion*					
No	90	15/652	3.85	1.49-9.96	0.006
Yes	13	6/59			
Grading					
G1/2	83	14/591	2.24	0.94-5.34	0.07
G3	23	8/141			
Margins					
No	89	16/645	2.38	0.93-6.11	0.07
Yes	17	6/86			

** 3 patients with missing information. CI: confidence interval; HR: hazard ratio; ENE: extra-nodal extension; PY: per-year.*

cations [31]. However, these latter studies were not focused on OTSCC, but included patients with tumours at different head and neck sites. Therefore, the impact of age on OTSCC prognosis has not been well defined and further studies that address this issue are warranted.

In our population, 5-year DFS and OS rates were 87.4% and 91.3%, respectively. These encouraging survival outcomes could be attributed to the post-operative strategies adopted, such as neck dissection and RT or CRT for patients displaying major risk factors. As previously described, patients with tumour depth greater than 3 mm were referred to elective neck dissection [20] as well as those with positive surgical margins, who received surgical re-intervention or, if technically not feasible, adjuvant CRT. In addition, the presence of ENE was a further absolute indication to adjuvant CRT. Patients with minor risk factors such as pT3 or pT4 primary, N2 or N3 nodal disease, nodal disease in levels IV or V, PNI, vascular embolism or lymphatic invasion underwent adjuvant RTX [18 21]. We did not find any difference in terms of DFS when considering smoking status, tumour size, nodal involvement, tumour depth, vascular invasion, positive surgical margins and cell differentiation.

Moreover, our study did not demonstrate a link between p16 expression and survival, confirming that the prognostic role of human papilloma virus (HPV) infection in OTSCC is not yet clear [32 33]. In addition, p53 expression did not impact on survival. Thus, our study is in good

agreement with the recent meta-analysis by Almangush et al., suggesting that p16 and p53 expression have no role as prognostic factors in OTSCC [34], while their pathogenetic role is unanimously recognised in oropharyngeal cancer [35 36]. To date, no clear prognostic biomarker has been established for OTSCC patients treated with radical surgery. Ongoing research on new biomarkers and genomic determinants might allow better understanding of the factors involved in OTSCC pathogenesis and progression [37 38].

Notably, tumours presenting with PNI had a higher risk of disease recurrence. PNI has a well-recognised prognostic role and is associated with dismal prognosis in head and neck tumours [39 40]. The presence of ENE also indicates an increased risk of tumour relapse, confirming its role as an independent poor prognostic factor [41].

Nowadays, high-quality surgery, eventually followed by RTX or CRT according to the presence of risk factors, represents the cornerstone on which long survival of early stage OTSCC is based. As previously described, in our population tumours with PNI and ENE presented a higher risk of disease relapse, underlining their significant role as prognostic factors. Moreover, their presence in tissue samples highlights the need of a careful multidisciplinary evaluation in order to plan the best postoperative therapeutic strategies.

Conclusions

Our study, with the limitation of a retrospective analysis, highlights the possibility to achieve high cure rates in OTSCC. PNI and ENE were independently associated with reduced DFS in our population. Survival rates of around 90% can be achieved by strict cooperation of a multidisciplinary team of experts that manages the patient from the first diagnostic approach to completion of treatment and definition of proper follow-up.

Conflict of interest statement

None declared.

References

1. Bello IO, Soini Y, Salo T. *Prognostic evaluation of oral tongue cancer: means, markers and perspectives (I)*. Oral Oncol 2010;46:630-5.
2. Siegel RL, Miller KD, Jemal A. *Cancer statistics, 2018*. CA Cancer J Clin 2018;68:7-30.
3. Patel SC, Carpenter WR, Tyree S, et al. *Increasing incidence of oral tongue squamous cell carcinoma in young white women, age 18 to 44 years*. J Clin Oncol 2011;29:1488-94.
4. Ng JH, Iyer NG, Tan MH, et al. *Changing epidemiology of oral squamous cell carcinoma of the tongue: a global study*. Head Neck 2017;39:297-304.
5. van Dijk BA, Brands MT, Geurts SM, et al. *Trends in oral cavity cancer incidence, mortality, survival and treatment in the Netherlands*. Int J Cancer 2016;139:574-83.
6. Ram H, Sarkar J, Kumar H, et al. *Oral cancer: risk factors and molecular pathogenesis.* J Maxillofac Oral Surg 2011;10:132-7.
7. Han G, Xu C, Yu D. *Mechanisms correlated with chemotherapy resistance in tongue cancers*. J Cancer Res Ther 2018;14:1-5.
8. Asakage T, Yokose T, Mukai K, et al. *Tumor thickness predicts cervical metastasis in patients with stage I/II carcinoma of the tongue*. Cancer 1998;82:1443-8.
9. Po Wing Yuen A, Lam KY, Lam LK, et al. *Prognostic factors of clinically stage I and II oral tongue carcinoma-A comparative study of stage, thickness, shape, growth pattern, invasive front malignancy grading, Martinez-Gimeno score, and pathologic features*. Head Neck 2002;24:513-20.
10. Brown B, Barnes L, Mazariegos J, et al. *Prognostic factors in mobile tongue and floor of mouth carcinoma*. Cancer 1989;64:1195-202.
11. Bonnardot L, Bardet E, Steichen O, et al. *Prognostic factors for T1-T2 squamous cell carcinomas of the mobile tongue: a retrospective cohort study*. Head Neck 2011;33:928-34.
12. Huang SH, Hwang D, Lockwood G, et al. *Predictive value of tumor thickness for cervical lymph-node involvement in squamous cell carcinoma of the oral cavity: a meta-analysis of reported studies*. Cancer 2009;115:1489-97.
13. Sakata J, Yamana K, Yoshida R, et al. *Tumor budding as a novel predictor of occult metastasis in cT2N0 tongue squamous cell carcinoma*. Hum Pathol 2018;76:1-8.
14. Bello IO, Soini Y, Salo T. *Prognostic evaluation of oral tongue cancer: means, markers and perspectives (II)*. Oral Oncol 2010;46:636-43.
15. Cracchiolo JR, Xu B, Migliacci JC, et al. *Patterns of recurrence in oral tongue cancer with perineural invasion*. Head Neck 2018;40:1287-95.
16. Maddox WA, Sherlock EC, Evans WB. *Cancer of the tongue: review of thirteen-year experience - 1955-1968*. Am Surg 1971;37:624-50.
17. Zelefsky MJ, Harrison LB, Fass DE, et al. *Postoperative radiotherapy for oral cavity cancers: impact of anatomic subsite on treatment outcome*. Head Neck 1990;12:470-5.
18. Gregoire V, Lefebvre JL, Licitra L, et al. *Squamous cell carcinoma of the head and neck: EHNS-ESMO-ESTRO Clinical Practice Guidelines for diagnosis, treatment and follow-up*. Ann Oncol 2010;21(Suppl 5):v184-6.
19. D'Cruz AK, Vaish R, Kapre N, et al. *Elective versus therapeutic neck dissection in node-negative oral cancer.* N Engl J Med 2015;373:521-9.
20. Civantos FJ, Zitsch RP, Schuller DE, et al. *Sentinel lymph node biopsy accurately stages the regional lymph nodes for T1-T2 oral squamous cell carcinomas: results of a prospective multi-institutional trial*. J Clin Oncol 2010;28:1395-400.
21. Network NCC. *Head and Neck Cancers, Version 2.2018*. Available at: https://www.nccn.org/professionals/physician_gls/pdf/head-and-neck.pdf. Accessed 16 August, 2018.
22. Lim AM, Do H, Young RJ, et al. *Differential mechanisms of CDKN2A (p16) alteration in oral tongue squamous cell carcinomas and correlation with patient outcome*. Int J Cancer 2014;135:887-95.
23. Xie X, Clausen OP, De Angelis P, et al. *The prognostic value of spontaneous apoptosis, Bax, Bcl-2, and p53 in oral squamous cell carcinoma of the tongue*. Cancer 1999;86:913-20.
24. Rusthoven K, Ballonoff A, Raben D, et al. *Poor prognosis in pa-*

tients with stage I and II oral tongue squamous cell carcinoma. Cancer 2008;112:345-51.

25 Jeon JH, Kim MG, Park JY, et al. *Analysis of the outcome of young age tongue squamous cell carcinoma*. Maxillofac Plast Reconstr Surg 2017;39:41.

26 Zhang YY, Wang DC, Su JZ, et al. *Clinicopathological characteristics and outcomes of squamous cell carcinoma of the tongue in different age groups*. Head Neck 2017;39:2276-82.

27 Hilly O, Shkedy Y, Hod R, et al. *Carcinoma of the oral tongue in patients younger than 30 years: comparison with patients older than 60 years*. Oral Oncol 2013;49:987-90.

28 Park JO, Sun DI, Cho KJ, et al. *Clinical outcome of squamous cell carcinoma of the tongue in young patients: a stage-matched comparative analysis*. Clin Exp Otorhinolaryngol 2010;3:161-5.

29 Tsai MS, Lai CH, Lee CP, et al. *Mortality in tongue cancer patients treated by curative surgery: a retrospective cohort study from CGRD*. Peer J 2016;4:e2794.

30 Cadoni G, Giraldi L, Petrelli L, et al. *Prognostic factors in head and neck cancer: a 10-year retrospective analysis in a single-institution in Italy.* Acta Otorhinolaryngol Ital 2017;37:458-66.

31 Molteni G, Valerini S, Alicandri-Ciufelli M, et al. *Unravelling the risk factors that underlie oral and oropharyngeal surgery in elderly.* Acta Otorhinolaryngol Ital 2018;38:409-16.

32 Minami K, Kogashiwa Y, Ebihara Y, et al. *Human papillomavirus and p16 protein expression as prognostic biomarkers in mobile tongue cancer*. Acta Otolaryngol 2017;137:1121-6.

33 Liang XH, Lewis J, Foote R, et al. *Prevalence and significance of human papillomavirus in oral tongue cancer: the Mayo Clinic experience*. J Oral Maxillofac Surg 2008;66:1875-80.

34 Almangush A, Heikkinen I, Makitie AA, et al. *Prognostic biomarkers for oral tongue squamous cell carcinoma: a systematic review and meta-analysis*. Br J Cancer 2017;117:856-66.

35 Elrefaey S, Massaro MA, Chiocca S, et al. *HPV in oropharyngeal cancer: the basics to know in clinical practice*. Acta Otorhinolaryngol Ital 2014;34:299-309.

36 Ang KK, Harris J, Wheeler R, et al. *Human papillomavirus and survival of patients with oropharyngeal cancer*. N Engl J Med 2010;363:24-35.

37 Kang H, Kiess A, Chung CH. *Emerging biomarkers in head and neck cancer in the era of genomics.* Nat Rev Clin Oncol 2015;12:11-26.

38 Arantes L, De Carvalho AC, Melendez ME, et al. *Serum, plasma and saliva biomarkers for head and neck cancer*. Expert Rev Mol Diagn 2018;18:85-112.

39 Tai SK, Li WY, Yang MH, et al. *Perineural invasion as a major determinant for the aggressiveness associated with increased tumor thickness in t1-2 oral tongue and buccal squamous cell carcinoma*. Ann Surg Oncol 2013;20:3568-74.

40 Liu SA, Wang CC, Jiang RS, et al. *Pathological features and their prognostic impacts on oral cavity cancer patients among different subsites - A singe institute's experience in Taiwan*. Sci Rep 2017;7:7451.

41 Matsumoto F, Mori T, Matsumura S, et al. *Prognostic significance of surgical extranodal extension in head and neck squamous cell carcinoma patients*. Jpn J Clin Oncol 2017;47:699-704.

Received: September 17, 2018 - Accepted: November 29, 2018

How to cite this article: Marra A, Violati M, Broggio F, et al. *Long-term disease-free survival in surgically-resected oral tongue cancer: a 10-year retrospective study*. Acta Otorhinolaryngol Ital 2019;39:84-91. https://doi.org/10.14639/0392-100X-2336

Address for correspondence: Daris Ferrari, Medical Oncology Unit, ASST Santi Paolo e Carlo, University of Milan, via Antonio di Rudinì 8, 20142 Milan, Italy. Tel. +39 02 81844493. E-mail: daris.ferrari@asst.santipaolocarlo.it

OPEN ACCESS

RHINOLOGY

Lateral osteotomy plus hump resection vs hump re-modeling without lateral osteotomy: impact on frontal nasal view

Confronto tra osteotomia laterale più gibbectomia e rimodellamento del gibbo senza osteotomia laterale: effetti sulla visione frontale

P.G. GIACOMINI[1], A. BOCCIERI[2], E. FUCCILLO[1], R. DI MAURO[1], S. DI GIROLAMO[1]

[1] Department of Clinical Sciences and Translation Medicine, Institute of Otorhinolaryngology University of Rome "Tor Vergata", Italy; [2] Private Practice, CdC Mercede Hospital, Rome, Italy

SUMMARY

This article reviews the personal experience and evolution of osteotomy approach in the last years of practice to obtain a natural appearance of the nasal pyramid in the frontal view. The aim is to analyse the long-term results after rhinoplasty on nasal width in two different cohorts of patients subjected to lateral osteotomy plus hump resection vs. hump re-modeling without lateral osteotomy considering the impact on frontal nasal view and how this relates to changes observed over time in the nasal width and contour. The study was carried out between January 2010 and December 2013, considering 42 patients undergoing primary rhinoplasty. Comparisons were made between the change in the dorsal width of the nasal pyramid at the level of the medial canthi, at the level of the inferior margin of the orbital rim, of ventral width of the nasal pyramid at the level of the medial canthi and at the level of the inferior margin of the orbital rim. In the first group, we found significant postoperative mean widening of the intercanthal dorsal width and narrowing of the ventral, while in the second group there was significant postoperative mean narrowing of the dorsal width both at level of the medial canthi and the anterior junction of the nasal bones. Our analysis seems to point out that dorsal grafting is useful for re-shaping the nasal profile with a persistent and harmonious correction of the dorsal frontal dimension of the nose. Simple hump removal/repositioning may be considered in selected instances to avoid lateral osteotomies. It also seems of paramount importance to tailor osteotomies according to nasal bone anatomy: large, strong and curved bones deserve aggressive narrowing by lateral and medial continuous osteotomies without periosteal elevation, although this approach may be insufficient to narrow the upper dorsal aspect of the nose.

KEY WORDS: Rhinoplasty • Nasal dorsum • Frontal view • Nasal width • Osteotomies

RIASSUNTO

Questo articolo presenta la nostra esperienza clinica degli ultimi anni nell'approccio alla correzione del gibbo nasale mediante il confronto tra osteotomia laterale più gibbectomia e rimodellamento del gibbo senza osteotomia laterale e valutando i risultati ottenuti nel tempo in termini di modificazione della larghezza e del contorno del dorso nasale, in visione frontale. Per la realizzazione del lavoro sono state considerate due diverse coorti di pazienti sottoposte a rinoplastica primaria, rispettivamente con o senza ricorso ad osteotomie laterali. Lo studio è stato condotto nel periodo compreso tra il 1 Gennaio 2010 ed il 31 Dicembre 2013, esaminando 42 pazienti sottoposti a rinoplastica primaria e considerando le modificazioni della larghezza dorsale della piramide nasale, misurata a livello del canto mediale ed a livello del margine inferiore del bordo orbitale e della larghezza ventrale della piramide nasale, misurata a livello del canto mediale e del margine inferiore del bordo orbitale. Nel primo gruppo di soggetti è stato osservato un significativo incremento postoperatorio della larghezza dorsale e del restringimento di quella ventrale, mentre nel secondo gruppo di pazienti è stato riscontrato un restringimento significativo della larghezza dorsale postoperatoria, misurata sia a livello del canto mediale, che della giunzione anteriore delle ossa nasali. La nostra analisi ha mostrato che il ricorso ad innesti dorsali può essere utile per una correzione persistente ed armonica del profilo nasale in visione frontale e che la rimozione semplice del gibbo sia da considerare in casi selezionati, evitando così osteotomie laterali. Il nostro lavoro ha inoltre evidenziato l'importanza delle caratteristiche anatomiche dell'osso nasale nella valutazione dell'approccio chirurgico: ossa grandi, forti e curve meritano un restringimento aggressivo con osteotomie continue laterali e mediali senza elevazione periostale, tuttavia questo approccio può essere in alcuni casi insufficiente per ridurre le dimensioni della regione superiore del dorso nasale.

PAROLE CHIAVE: *Rinoplastica • Dorso nasale • Visione frontale • Larghezza nasale • Osteotomie*

© Società Italiana di Otorinolaringoiatria e Chirurgia Cervico-Facciale

Introduction

Rhinoplasty encompasses the aim of reshaping the nasal pyramid, and modification of the bony nasal vault is very frequently addressed to mobilise the bony pyramid for infracture, outfracture, or realignment. Osteotomies of the bony pyramid composing the upper nasal third are needed to reshape the nasal dorsum and sidewalls. Analysis of the nasal bone length and width is strategical to plan appropriate surgical measures [1 2].

Reshaping of the bony vault may be simple, but requires both skill and experience to gain narrowing, straightening and reduction in nasal height. Various types of osteotomies have been devised to achieve this task: medial, transverse oblique, low to low lateral, low to high lateral and intermediate osteotomies. A peculiar problem is the correction of the wide pyramid: lateral osteotomies are needed for this issue [3]. Two basic techniques have been developed to date; the internal (endonasal) continuous technique and the external (percutaneous) perforating method, each with pros and cons [4-9]. A persistent problem with nasal bone osteotomies is inadequate reduction of the width of the nasal dorsum. In addition, an algorithm as to which osteotomy to use has not been fully explored [10 11].

This article reviews the personal experience and evolution of osteotomy approach in the last years of practice in order to obtain a natural appearance of the nasal pyramid in the frontal view. The aim is to analyse the long-term results after rhinoplasty on nasal width in two different cohorts of patients subjected to lateral osteotomy plus hump resection vs. hump re-modeling without lateral osteotomy and how this relates to the changes observed overtime in the nasal width and contour.

Materials and methods

From a series of patients subjected to rhinoplasty from January 1, 2010, through December 31, 2013, 42 unselected patients receiving primary reduction rhinoplasty were retrospectively analysed in this study. Oral and written informed consent for participation in this study was obtained from each subject.

Two different cohorts were analysed (Table I).

Group 1: treated uniformly by subperiosteal hump removal and paramedian + lateral osteotomy by the method of high-low-high lateral osteotomies as described by Webster et al. and Kortbus et al. [12 13] and infracture without periosteal elevation: briefly, in the presented series, we performed internal trans-vestibular, continuous, high-to-low-to-high lateral osteotomies by 3 mm laterally guided chisel, infracture followed, in all cases of group 1. Paramedian-oblique osteotomies were performed in 4 cases when needed for incomplete infracture obtained, a wedge excision of thick nasion bone was accomplished in 3 cases of group 1.

Group 2: was treated by subperiosteal hump removal and remodeling-repositioning of the hump as onlay graft without lateral osteotomy. After removal of the cartilagineous-bony hump in one block by chisel, re-shaping of it was accomplished: the needed size to precisely cover the "open roof" deformity was obtained by trimming the margins, and correction of the autograft convex profile was obtained by gentle crushing of the residual bony component to flatten it to the desired shape. Repositioning of the graft via intercartilagineous incision was guided and successively secured to soft tissues of the dorsum by two (one cephalically and one caudally positioned) stitches placed in the midline of graft and dorsal skin to prevent displacement. Ultra-sharp, thin chisels and rasp were used. The follow-up ranged from 12 to 60 months (mean: 18 + 4 months). Preoperative and postoperative photographs were taken with a digital camera with a 100-mm Ultrasonic lens (Canon model EOS D30 camera; Canon, USA, Inc, Lake Success, NY). Flash lighting was used for all pictures. By using preoperative and postoperative photographs dimension-adjusted (interpupillary distance = 3.7 mm), the postoperative dorsal width and ventral width were directly measured to the closest mm. The preoperative photographs were rescaled to the exact size of the postoperative photographs, using the interpupillary distance as reference. Analysis of the frontal view of the nose was carried out: comparisons were made in the change in dorsal width of the nasal pyramid (d) (where the nasal bones meet each-other) at the level of the medial canthi and at the level of the inferior margin of the orbital rim, and of the ventral width of the nasal pyramid (v) (where the nasal processes of the maxilla meet the body of the maxilla) at the level of the medial canthi and at the level of the inferior margin of the orbital rim (Fig. 1). Postoperative views considered for final evaluation were taken at least 12 months after surgery and evaluations were carried out by a physician uninvolved in patient's care to avoid possible bias.

A comparison was made between groups. Statistical evaluation was carried out by computer-assisted (Microsoft-

Table I. Characteristics of groups studied.

	Group 1	Group 2
Number	24	18
Male/Female	4/20	7/11
Mean age ± sd	26.8 ± 3.4	35.1 ± 4.7

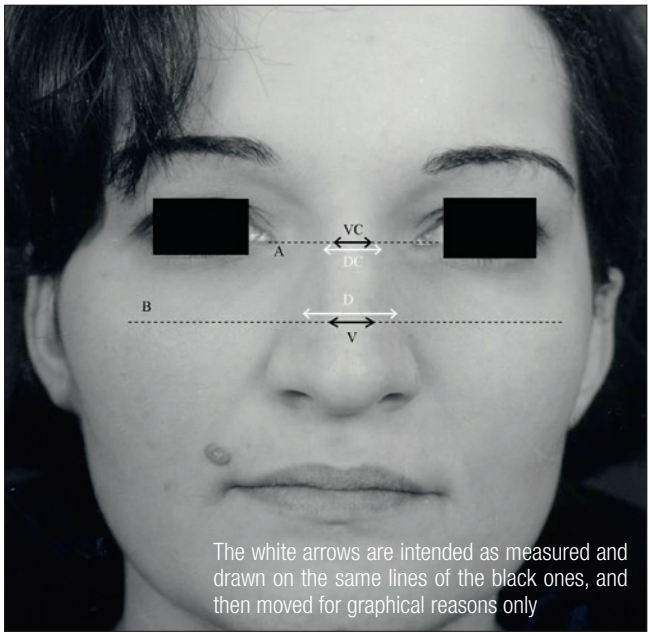

Fig. 1. Measurement of the nasal pyramid width. **A)** Intercanthal line level; **B)** inferior orbital rim level; **VC)** ventral intercanthal width; **V)** ventral infraorbital width; **DC)** dorsal intercanthal width; **D)** dorsal infraorbital width.

Excel. Usa) mean + sd comparisons by 2-tail/paired data Student's T-test ($p < 0.05$).

Results

Summary statistics of the population profile are displayed in Table I; the results of pre- and post-operative picture analysis for nasal width changes exhibited different outcomes according to groups (Tables II, III), (Figs. 2-5).

In group 1, there was significant postoperative mean widening of the intercanthal dorsal width (d) and narrowing of the ventral width (v) (where the nasal processes of the maxilla meet the body of the maxilla).

In group 2, there was significant postoperative mean narrowing of the dorsal width (d) both at level of the medial canthi and of the anterior junction of the nasal bones.

Complications linked to lateral osteotomy recorded were: one case of incomplete closure of the open roof due to insufficient reduction of the thick bone at the level of the nasion (4.16%).

Complications linked to dorsal graft positioned recorded was one case of slight residual convexity of the dorsal profile due to its insufficient flattening during re-shaping (5.55%).

Discussion

Osteotomy is one of the major aspects of a rhinoplasty operation. Different authors use different techniques to perform osteotomy. The external perforating approach and the internal continuous technique are the two main ways of performing osteotomy in rhinoplasty. The goals of the procedure are to: gain adequate reduction of the width of the nasal dorsum, minimise soft tissue reactions (oedema, bruising, scarring), avoid airway stenosis in the nasal valve area and obtain stable results.

A persistent problem with nasal bone osteotomies is inadequate reduction of the width of the nasal dorsum. In addition, an algorithm as to which osteotomy to use has not been fully explored [4 10 11].

Review of literature data in the last years seems to point out some issues: in a first attempt to quantify the amount of narrowing after nasal osteotomies, Kortbus et al. evaluated the long-term results after reduction rhinoplasty. Us-

Table II. Group 1 measurement data (M: mean, SD: standard deviation).

	Pre-ventral intercanthal	Post-ventral intercanthal	Pre-dorsal intercanthal	Post-dorsal intercanthal	Pre-ventral infraorbital	Post-ventral infraorbital	Pre-dorsal infraorbital	Post-dorsal infraorbital
M	1.25 cm	1.254167 cm	0.795843 cm	0.870833* cm	1.575 cm	1.520833* cm	0.966667	0.995833
SD	0.90453	0.143746	0.094046	0.101036	0.213733	0.221008	0.258785	0.157333

*: statistical significance: $p < 0.05$.

Table III. Group 2 measurement data (M: mean, SD: standard deviation).

	Pre-ventral intercanthal	Post-ventral intercanthal	Pre-dorsal intercanthal	Post-dorsal intercanthal	Pre-ventral infraorbital	Post-ventral infraorbital	Pre-dorsal infraorbital	Post-dorsal infraorbital
M	1.227778 cm	1.77778 cm	0.844444 cm	0.727778* cm	1.555556 cm	1.511111 cm	0.933333 cm	0.866667* cm
SD	0.122758	0.158333	0.130969	0.13255	0.212786	0.261937	0.152069	0.206155

*: statistical significance: $p < 0.05$.

Fig. 2. Group 1 case, pre-operative picture.

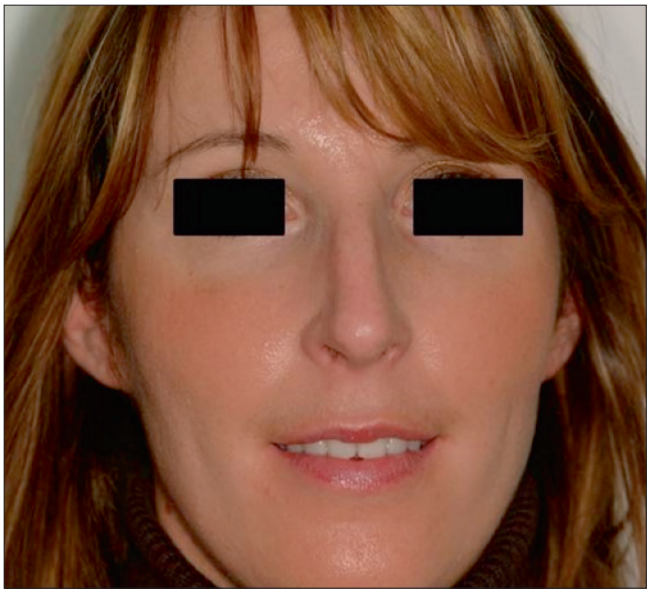

Fig. 4. Group 2 case, pre-operative picture.

Fig. 3. Group 1 case, post-operative picture. Patient treated with subperiosteal hump removal and paramedian + lateral osteotomy.

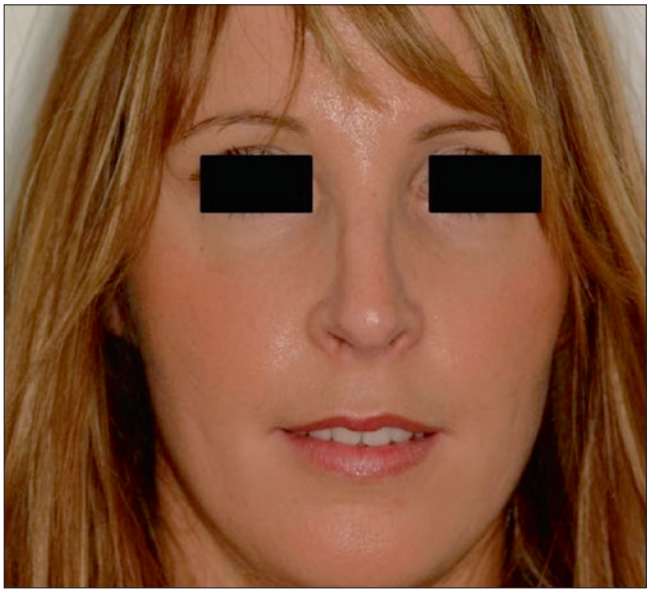

Fig. 5. Group 2 case, post-operative picture. Patient treated by subperiosteal hump-removal and remodeling-repositioning of the hump as onlay graft without lateral osteotomy.

ing preoperative and postoperative photographs, comparisons were made in the change in the dorsal width of the nose and the ventral width of the nose at the level of the middle third of the nasal pyramid in a frontal plane. A significant change in the ventral width of the nose was found after nasal bone osteotomy, but no significant change in the dorsal width of the nose. It was concluded that using this osteotomy, it is possible to narrow the ventral width of the nose with statistical significance. The dorsal width of the nose is maintained [13].

Differently from Kortbus et al., the present paper analysed changes in nasal width at two different levels of the nasal pyramid: the upper third (intercanthal level) and the middle third (inferior orbital rim level), while both dorsal and

ventral measurements are considered in a frontal plane. These measurements allow thorough evaluation of the upper 2/3 of the nose in the frontal view. A comparison is made between cases treated by hump resection and paramedian + lateral osteotomy vs hump resection+reshaped hump onlay grafting without lateral osteotomy. At long-term, follow-up hump removal+hump grafting allows significant narrowing of the dorsal aspect of the upper 2/3 of the nasal dorsum (Fig. 5). On the other hand, the use of hump resection and lateral osteotomy is effective in narrowing the ventral aspect of the middle third (in accordance with Kortbus MJ et al. results), leaving the dorsum unchanged at this level or even widened in the upper third (in around 45% of our patients). This seems to be a shared experience: Kortbus MJ et al. reported no changes in dorsal width after lateral osteotomy in the 20 cases analysed in that study, but noted that most surgeons counsel their patients preoperatively to mention that reducing the dorsum increases the dorsal width [13].

A possible bias in our study should be taken into account: the use of paramedian + lateral osteotomies in this series was favoured in cases of excessively broad or deviated noses, whereas avoidance of lateral osteotomies was favoured in noses with straight bones. Such results seem to suggest that different goals may be achieved in correction of nasal width in the upper 2/3 by selective use of different osteotomies [10-14].

Gruber R. et al. (2007) tried to establish an algorithm as to which osteotomy to use: they concluded that reduction of the nasal dorsal width is facilitated by a medial oblique osteotomy alone if it is placed at the lateral aspect of the apex of the open roof. Their classification of broad nasal bones emphasises nasal width based osteotomy: type I, broad nasal base (lateral osteotomy only); type II, broad nasal base and broad dorsum (lateral and medial oblique osteotomy); and type III, broad dorsum only (medial oblique osteotomy only) [8]. Other authors have proposed different procedures accordingly to pyramid width [3 15 16].

In our experience, a custom-made approach to the osteotomy seems most appropriate and no single technique seems clearly useful for all situations.

A valuable adjunct to the correction of the nasal dorsum is the use of nasal bone grafts as dorsal or spreader graft, which is a safe, effective, reliable and permanent method for correction of the open roof, dorsal irregularities and crooked nose [17 18]. Moreover, the onlay graft made of reshaped hump used in our (group 2) patients (without lateral osteotomies) seems to add definition to the orbitonasal lines. A better definition is therefore warranted giving the visual appearance of a narrowed nasal dorsum at postoperative evaluation and measurement, which is often missing in (group 1) cases treated by paramedian+lateral osteotomies and no grafting. We report herein one case of a complication linked to dorsal graft positioning: a slight residual convexity of the dorsal profile due to its insufficient flattening during re-shaping.

It must be taken into account that lateral nasal osteotomy is fraught with potential problems. These include nasal valve collapse, a displaced and floating or a collapsed bony segment, and nasal asymmetry. The dimensions of the nasal valve, and how it changes with osteotomies, have been measured in several studies [19 20]. In the present series, we observed one case of incomplete closure of the open roof due to insufficient reduction of the thick bone at the level of the nasion.

It therefore seems logical to develop appropriate surgical approaches that can be employed selectively by analysing the nasal bones and determining their length and width to minimize pitfalls and maximise outcomes [1].

Conclusions

The analysis of the long-term results after rhinoplasty on nasal width in two different cohorts of patients subjected to lateral osteotomy plus hump resection vs. hump re-modeling without lateral osteotomy and how this relates to the changes observed overtime in the nasal width and contour, seems to point out that dorsal grafting is useful for re-shaping the nasal width and profile with a persistent and harmonious correction of the dorsal frontal dimension of the nose. Simple hump removal/repositioning may be considered in selected instances thus avoiding lateral osteotomies. This allows maintaining the natural narrow nasal root with good aesthetics, good function and low local morbidity (Fig. 5). It also seems of paramount importance to tailor osteotomies to nasal bone anatomy (form, thickness, consistency and previous trauma must be considered): large, strong and curved bones warrant aggressive narrowing by lateral and medial continuous osteotomies without periosteal elevation. However, this approach may be insufficient to narrow the upper dorsal aspect of the nose. Care must be taken to cut a medial bone in a laterally oriented fashion to possibly reduce the thick bone at the nasion and avoid the eventual re-widening of nasal bones. A possible bias of our study is that lateral osteotomy was not performed in straight, thin noses, but preferred in broad and/or deviated nasal pyramids

Conflict of interest statement

None declared.

References

1. Shah AR, Constantinides M. *Aligning the bony nasal vault in rhinoplasty.* Facial Plast Surg 2006;22:3-8.
2. Tercan M, Yesiladali G, Ciloglu S, et al. *Topographic evaluation of the medial canthus-alar groove line in terms of determining the boundaries of lateral osteotomies.* Aesthetic Plast Surg 2013;37:34-8.
3. Westreich RW, Lawson W. *Perforating double lateral osteotomy.* Arch Facial Plast Surg 2005;7:257-60.
4. Taşkın Ü, Batmaz T, Erdil M, et al. *The comparison of edema and ecchymosis after piezoelectric and conventional osteotomy in rhinoplasty.* Eur Arch Otorhinolaryngol 2017;274:861-5.
5. Gruber RP, Garza RM, Cho GJ. *Nasal bone osteotomies with non-powered tools.* Clin Plast Surg 2016;43:73-83.
6. Ghanaatpisheh M, Sajjadian A, Daniel RK. *Superior rhinoplasty outcomes with precise nasal osteotomy: an individualized approach for maintaining function and achieving aesthetic goals.* Aesthet Surg J 2015;35:28-39.
7. Robiony M, Toro C, Costa F, et al. *Piezosurgery: a new method for osteotomies in rhinoplasty.* J Craniofac Surg 2007;18:1098-100.
8. Yücel OT. *Which type of osteotomy for edema and ecchymosis: external or internal?* Ann Plast Surg 2005;55:587-90.
9. Gryskiewicz JM. *Visible scars from percutaneous osteotomies.* Plast Reconstr Surg 2005;116:1771-5.
10. Hontanilla B, Cabello A, Olivas J. *A predictable approach for osteotomy in rhinoplasty: a new concept of open external osteotomy.* Plast Reconstr Surg Glob Open 2016;4:e764.
11. Gruber R, Chang TN, Kahn D, et al. *Broad nasal bone reduction: an algorithm for osteotomies.* Plast Reconstr Surg 2007;119:1044-53.
12. Webster RC, Davidson TM, Smith RC. *Curved lateral osteotomy for airway protection in rhinoplasty.* Arch Otolaryngol 1977;103:454-8.
13. Kortbus MJ, Ham J, Fechner F. *Quantitative analysis of lateral osteotomies in rhinoplasty.* Arch Facial Plast Surg 2006;8:369-73.
14. Lee YH, Lee SH, Hwang K. *Pentagonal hinge osteotomy for reduction of the wide nasal base of Asians.* J Craniofac Surg 2012;23:1442-3.
15. Jang YJ, Wang JH, Sinha V. *Percutaneous root osteotomy for correction of the deviated nose.* Am J Rhinol 2007;21:515-9.
16. Cochran CS, Ducic Y, Defatta RJ. *Rethinking nasal osteotomies: an anatomic approach.* Laryngoscope 2007;117:662-7.
17. Quatela VC, Leake DS, Sabini P. *Surgical management of concavities of the distal nose.* Facial Plast Surg Clin North Am 2004;12:133-56.
18. Emsen IM. *A different approach to the reconstruction of the stubborn crooked nose with a different spreader graft: nasal bone grafts harvested from the removed nasal hump.* Ann Plast Surg 2009;33:674.
19. Grymer LF, Gregers-Petersen C, Baymler Pedersen H. *Influence of lateral osteotomies in the dimensions of the nasal cavity.* Laryngoscope 1999;109:936-8.
20. Ousterhout DK, Vargervik K, Miller AJ. *Nasal airway function as it relates to the timing of mid and lower facial osteotomies.* Ann Plast Surg 1983;11:175-81.

Received: August 4, 2017 - Accepted: July 8, 2018

How to cite this article: Giacomini PG, Boccieri A, Fuccillo E, et al. *Lateral osteotomy plus hump resection vs hump re-modeling without lateral osteotomy: impact on frontal nasal view*. Acta Otorhinolaryngol Ital 2019;39:92-97. https://doi.org/10.14639/0392-100X-1897.

Address for correspondence: Pier Giorgio Giacomini, University of Rome "Tor Vergata", Department of Clinical Science and Translation Medicine, Institute of Otorhinolaryngology, "Tor Vergata" Hospital, via Orazio Raimondo 18, 00173 Rome, Italy. Tel. +39 06 20902925. Fax +39 06 20902930. E-mail: pggiacomini@tiscali.it

ACTA OTORHINOLARYNGOLOGICA ITALICA 2019;39:98-102; doi: 10.14639/0392-100X-2061 OPEN ACCESS

RHINOLOGY

Evaluation of nasal symptoms in septoplasty patients using SNOT-22

Valutazione dei sintomi nasali mediante SNOT-22 nei pazienti sottoposti a settoplastica

D. DIZDAR[1], A. BOZAN[2], S.K. DIZDAR[3], S. GÖDE[4], H.C. ALPAY[2]

[1] Istanbul Kemerburgaz University, Medical Faculty, Department of Otorhinolaryngology, Istanbul, Turkey; [2] Istanbul Kemerburgaz University, Medical Faculty, Department of Otorhinolaryngology, Tarsus, Turkey; [3] Hamidiye Sisli Etfal Education and Research Hospital, Istanbul, Turkey; [4] Ege University, Medical Faculty, Department of Otorhinolaryngology, Izmir,Turkey

SUMMARY

The aim of our study is to evaluate the nasal symptoms of patients with indications for septoplasty using the SNOT-22 questionnaire and to investigate the effects of variables such as concha surgery, age, obstructive sleep apnoea (OSA), smoking and asthma on these symptoms. A total of 100 patients were included in the study. Pre-operative and at postoperative month 3, patients were administered the Sinus Nasal Conduct Test (SNOT-22). Septoplasty operations were performed by two centres and two otolaryngologists and head and neck surgeons. The patients were divided into two groups according to the surgical procedure of the lower concha, concha shaver group and concha out fractures. The difference in total score between preop and postop was significant in both the shaver and outfracture groups with a difference in total score of 17.85 (46%). Improvement in symptoms of nasal obstruction was observed with a mean improvement of 0.81 points (2.79 points). In our study, there was no significant difference in preop and postop symptom scores in patients who had subcuneal shaved submucous resection with outfracture ($p = 0.861$). There was no significant difference between preop and postop total scores between asthma, smoking, OSA and non-asthmatics ($p > 0.05$). There was no correlation between scores and age in either group ($p > 0.05$). Before septoplasty, the most important symptom was nasal obstruction. Intervention at the inferior turbinate during surgery increases the benefits of septoplasty independently of the surgical technique. Factors such as asthma, OSA, smoking are significantly relevant to symptoms. In those with asthma and OSA, the scores were found to be high both before and after intervention.

KEY WORDS: Septoplasty • SNOT-22 • Concha • Out-fracture • Shaver

RIASSUNTO

Obiettivo del nostro studio è valutare i sintomi nasali dei pazienti con indicazione a settoplastica mediante il questionario SNOT-22 ed investigare gli effetti di alcune variabili, quali la chirurgia della conca, l'età, l'apnea ostruttiva del sonno (OSA), il fumo e l'asma, su questi sintomi. Un totale di 100 pazienti è stato incluso nello studio. Ai pazienti è stato sottoposto il questionario SNOT-22 (Sinus Nasal Conduct Test) preoperatoriamente e post-operatoriamente a distanza di 3 mesi. Gli interventi di settoplastica sono stati eseguiti in due centri e da due otorinolarinoiatri. I pazienti sono stati divisi in 2 gruppi a seconda della procedura chirurgica sul turbinato inferiore: shaving o outfracture. La differenza nel punteggio totale tra preoperatorio e post-operatorio è risultata signiticativa in entrambi i gruppi, con un valore di 17,85 (46%). Si è osservato un miglioramento dei sintomi da ostruzione nasale con valore medio di 0,81 punti (2,79 punti). Nel nostro studio non è stata riscontrata differenza significativa nei punteggi riguardanti i sintomi preoperatori e postoperatori dei pazienti sottoposti a resezione sottomucosa con outfracture ($p = 0,861$). Non abbiamo evidenziato differenza significativa tra i punteggi totali preoperatori e postoperatori per quanto riguarda asma, fumo, OSA e non-asmatici ($p > 0,05$). Non abbiamo evidenziato correlazione tra i punteggi e l'età in entrambi i gruppi ($p > 0,05$). Prima della settoplastica il sintomo principale era l'ostruzione nasale. L'intervento sul turbinato inferiore durante la chirurgia aumenta i benefici della settoplastica indipendentemente dalla tecnica chirurgica. Fattori quali asma, OSA, fumo sono significativamente correlati ai sintomi. Nei pazienti con asma e OSA, i punteggi sono risultati superiore sia prima sia dopo l'intervento.

PAROLE CHIAVE: *Settoplastica • SNOT-22 • Conca • Outfracture • Shaver*

Introduction

Nasal septum deviation is present in 19-65% of the population [1]. Dommerby and Tos reported that nasal trauma in childhood causes more septum deviations than in a control group [2]. Surgical treatment is required when septum deviation causes symptoms of nasal obstruction. However, the efficacy of septoplasty remains controversial. Many questionnaire-based studies have subjectively evaluated the effects of septoplasty on quality of life and nasal symptoms.

 © Società Italiana di Otorinolaringoiatria e Chirurgia Cervico-Facciale

The Nasal Obstruction Septoplasty Effectiveness scale (NOSE) [3], Sinonasal Outcome Test-20 (SNOT-20) [4], and Sinonasal Outcome Test-22 (SNOT-22) [5 6] are commonly used evaluation methods. Hytönen et al. reported a 55% improvement in the second postoperative year in patients undergoing septoplasty [7]. Another study that evaluated 200 patients at 6 weeks postoperatively reported improvement in nasal obstruction in 74% of patients [8]. However, there are also reports of long-term complaints [9]. Lower concha surgery methods are frequently performed with septoplasty, which most frequently affect surgical outcome and improves the symptoms of nasal obstruction [10]. In the literature, there is no single, optimal inferior turbinate surgical method [11]. However, radiofrequency coblation and microdebrider-assisted turbinoplasty are commonly used techniques [11 12].

The multiplicity of variables affecting the success of nasal septal surgery may be the cause of differences in outcomes. To evaluate the nasal symptoms of our septoplasty patients, we examined the effects of surgeon, patient age, obstructive sleep apnoea (OSA), smoking and asthma on symptoms using pre- and post-operative SNOT-22 scores.

Materials and methods

This study enrolled 118 adults treated between February 2015 and May 2017. Septoplasty was performed on those with nasal obstruction and other nasal symptoms in whom septum deviation and uni/bilateral inferior concha hypertropy was detected by nasal endoscopy. Informed consent was obtained from patients before the operation. All operations were performed under general anaesthesia. During septoplasty, submucosal shaver excision was performed for those with advanced hypertrophy in the lower conchae, and outfracture was performed for those with moderate hypertrophy. Patients were divided in two groups. Patients who underwent nasal septal correction and submucous shaver excision formed the shaver group, patients with outfracture formed outfracture group. Patients with a history of rhinoplasty; patients with prior conchal surgery or endoscopic sinus surgery with septoplasty were excluded from the study. Postoperatively, 19 of the patients were hospitalised for 1 day; the others were discharged the same day. The operations were performed in two centres, by two otolaryngologists and head and neck surgeons. A silicone splint was used in all patients. In addition, 95 patients were treated with Merocel buffer: Merocel-soaked tampons were left in 12 patients for 3 days, while the others were removed after 48 hours. The silicone splints were frequently removed on day 7 [13].

The SNOT-22 questionnaire, which has been validated in Turkish, was completed 3-9 days preoperatively and at the 3-month follow-up visit. Patients were asked to score the 22 symptoms on the questionnaire with 0-5 points (0 no problem, 5 worst case) and to identify the five symptoms most important to them. Patients who did not attend the follow-up examination were sent the questionnaire by mail.

Descriptive statistics of patients were summarised as means ± standard deviation and number. Demographic characteristics were assessed using the independent t-test, chi-squared test, or Fisher's test (Table I); there were no significant differences between the shaver and outfracture groups. Within groups, the significance of the change in responses to each question was assessed using the Stuart-Maxwell test; P values are given in Table II. The differences between the overall pre- and post-operative scores were assessed using paired t-tests and the difference between two values was assessed using independent t-tests (Table III). The differences between the pre- and post-operative averages according to gender, smokers versus non-smokers and groups with and without comorbidities were assessed using the same methods (Table IV). Statistical significance was set as $p < 0.05$. The analyses were

Table I. Demographic data of the groups and comparison with each other.

		Concha shaver (N = 45)	Concha outfracture (N = 55)	P
Age		35.6 ± 13.4	35.7 ± 12.9	0.990
Sex	M	24	33	0.503
	F	21	22	
Smoking	Yes	24	24	0.334
	No	21	31	
Asthma	Yes	8	7	0.577
	No	37	48	
OSA	Yes	6	6	0.764
	No	39	49	

OSA: obstructive sleep apnoea.

performed using STATA/MP11. The study was approved by Adana Numune Education and Research Hospital Ethics Committee (Ethics Committee No: 90).

Results

The study initially enrolled 118 patients. Eight patients were removed from the study because they did not undergo subconchal surgery and 10 patients were lost to follow-up. Consequently, 100 (91%) patients (57 men, 43 women) included in the study completed the pre- and postoperative SNOT-22. Of the patients, 15 had asthma, 48 smoked cigarettes and 12 had OSA. In the preoperative polysomnographic evaluation of OSA patients, five were moderate OSA (AHI from 15 to 30) and seven were mild OSA (AHI from 5-15). Fifty-five outfractures were performed with the submucosal resection, while 45 patients had a septoplasty with a lower conchal shaver.

The shaver group comprised 45 patients (24 men, 21 women; mean age 35.6 ± 13.4 years), while the outfracture group comprised 55 patients (33 men, 22 women; mean age 35.7 ± 12.9 years). Each group included 24 cigarette smokers and six patients with OSA; there were eight patients with asthma in the shaver group and seven in the outfracture group (Table I). The pre- and postoperative SNOT-22 score difference was 17.85 (46%). A mean improvement in symptoms of nasal obstruction of 0.81 points was observed, and the greatest improvement was 2.79 points. Age, gender, smoking, asthma and OSA did not differ between the two groups (all $p > 0.05$). There was a significant difference ($p < 0.001$) between the pre- and postoperative responses to the sadness and frustration questions. There was no significant difference between the pre- and post-operative responses to questions about solid nasal discharge, ear fullness, dizziness, ear pain, face pain or sensation of pressure ($p > 0.05$) (Table II).

In the outfracture group, there were significant differences between the pre- and postoperative responses to all questions, except ear fullness, nervousness, restlessness and aspiration (Table II). There was no significant difference in the pre- and post-operative total scores between the two groups ($p = 0.861$). Additionally, the differences between pre- and post-operative scores did not differ significantly between groups ($p = 0.723$) (Table III, Fig. 1).

The difference in the pre- and postoperative total scores was not affected by gender, smoking, or OSA within and between groups (all $p > 0.05$). In addition, there was no significant correlation between the pre- and post-operative score difference and age in either group ($p > 0.05$) (Table IV). When all patients were evaluated, there was no significant difference in pre- and post-operative scores between asthmatic and non-asthmatic patients ($p = 0.993$ and $p = 0.447$, respectively). No significant difference was found between OSA and non-OSA patients in terms of difference in the total score ($p = 0.143$ and $p = 0.466$, respectively).

Table II. Intra-group comparison of pre-operative and post-operative scores of each symptom.

Symptom	Group	
	Concha shaver (N = 45)	Concha outfracture (N = 55)
Hawking	0.0018	< 0.001
Obstruction	< 0.001	< 0.001
Sneezing	0.0019	0.0027
Discharge	0.0046	0.0268
Cough	0.0015	0.0021
Post-nasal drip	0.0083	0.0070
Solid nasal discharge	0.1219	0.0003
Ear stuffiness	0.1904	0.0759
Dizziness	0.5049	0.0051
Otalgia	0.1750	0.0098
Facial pain-pressure	0.2585	0.0162
Loss of smell-taste	0.0313	< 0.001
Sleepiness	0.0002	< 0.001
Wake up during night	0.0001	< 0.001
Good quality of sleep	< 0.001	< 0.001
Wake up tired	< 0.001	< 0.001
Fatigue	< 0.001	< 0.001
Poor work performance	< 0.001	0.0008
Concentration problems	0.0001	0.0016
Irritability-restlessness	0.0002	0.3391
Depression	0.0337	0.0012
Shyness	0.0018	0.0456

Table III. Comparison of pre-operative and post-operative scores between groups and intra-group.

	Concha shaver (N = 45)	Concha outfracture (N = 55)	P
Pre-operative	38.2 ± 7.4	38.4 ± 7,3	0.861
Post-operative	20.0 ± 3,509	20.9 ± 3,2	0.227
Difference	18.2 ± 7.8	17.6 ± 8.8	0.723
P	< 0.001	< 0.001	

Discussion

Of the patients participating in the study, 100 (91%) completed both the pre- and post-operative questionnaires. This rate is higher than that in other studies (60-76%) [5 10].

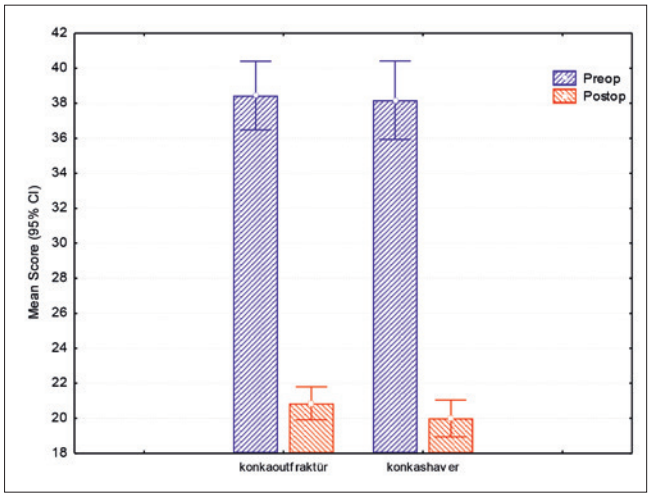

Fig. 1. Total score averages in both groups in pre-operative and post-operative period.

The SNOT-22 was first used to evaluate chronic sinusitis [13], and has also been used in sepsis [5 6]. Two septoplasty studies have used the SNOT-22 questionnaire: Buckland et al. [6] evaluated 40 patients and Maija et al. [5] evaluated 126 patients at 6 months post-operatively. In our study, the mean preoperative SNOT-22 score was 38.2 (range 21-57), which was higher than SNOT-22 scores in studies of other patients with septal deviation [5 6]. This may be due to the severe deviation in our patients. The mean postoperative SNOT-22 score was 20.47 (range 14-28), which is consistent with other studies. In SNOT-22 studies conducted in patients with chronic sinusitis and nasal polyps, the mean symptom score decreased by an average of 12.6 and 17.7 points, respectively. The pre- and post-operative total symptom score difference was 4.1 (19%) and 17 (47%) in SNOT-22 studies performed in the patients with septoplasty [6 14]. In 40 patients with septal deviation, Buckland et al. [6] observed the greatest improvement in symptoms of nasal obstruction (mean 2 points), while the other symptoms showed a median improvement of 0.8 points. The difference in our study was 17.85 (46%). While symptoms improved by 0.81 points on average, and symptomatic improvement in nasal obstruction was 2.79 points.

The mean SNOT-22 score in a healthy population was 9.3 and the lowest significant pre-/post-operative total score difference in a patient population was 8.9 [5 14]. In our study, the pre-/post-operative total score difference in 15 patients (15%) was less than 8.9, perhaps because the septal deviation was more moderate in these patients. In our study, two symptoms in the outfracture group and five symptoms in the shaver group did not change significantly postoperatively. There was no significant change in atrophy in either group. This is consistent with other septoplasty studies. In our study, there were no significant differences in the pre- and post-operative symptom scores of patients who underwent shaved submucosal resection and outfracture ($p = 0.861$).

A study that applied radiofrequency ablation reported that the SNOT scores were lower than those in patients who did not undergo radiofrequency ablation [5]. Another study reported that patients with concha hypertrophy who underwent septoplasty showed significantly improved postoperative nasal obstruction symptoms [11]. In conclusion, although there was improvement in the symptoms of patients who underwent septoplasty and lower concha surgery, there was no difference according to the surgical techniques used.

The symptoms of nasal obstruction are greater in asthmatics than in non-asthmatics [15]. Nasal obstruction can also

Table IV. Pre-operative and post-operative score difference in relation to gender, smoking and OSA.

		Concha shaver (N = 45)	Concha outfracture (N = 55)	P
Sex	M	19.0 ± 6.3	18,787 ± 7,983	0.914
	F	17.2 ± 9.3	15.772 ± 9.734	0.617
P		0.457	0.214	
Smoking	Yes	18.4 ± 6.0	17.9 ± 9.1	0.793
	No	17.9 ± 9.7	17.4 ± 8.7	0.845
P		0.800	0.829	
OSA	Yes	15.2 ± 5.3	13.3 ± 9.2	0.680
	No	18.6 ± 8.1	18.102 ± 8.7	0.766
P		0.316	0.211	
Age	Correlation	– 0.0861	– 0.0902	
P		0.5737	0.5126	

OSA: obstructive sleep apnaea

lead to worsening of asthma. In our study, 15 patients had asthma. As in another study using the SNOT-20 questionnaire [4], there was no significant difference in the pre- and post-operative symptom scores between asthmatic and non-asthmatic patients. However, asthmatics had more symptoms than non-asthmatics. Many studies have reported that young populations benefit more from septoplasty [16]. However, there was no correlation between the changes in postoperative symptoms and age in our study. Additionally, our study included 12 (12%) patients with OSA. There was no significant difference in SNOT-22 scores between OSA and non-OSA patients after septoplasty. However, as in asthmatics, the symptom scores were higher in the OSA patients than in the non-OSA patients. After surgery, three OSA patients reported using continuous positive airway pressure (CPAP). This may be due to their relatively low preoperative apnea hypopnea index (AHI) and the reduced oropharyngeal obstruction of patients who discontinued CPAP use. However, since there were no data to evaluate this and no postoperative polysomnography data, we cannot comment on OSA patients. Although both groups showed improvement in our study, there are reports that the outcome of successful septoplasty worsens in the long term [9]. Therefore, long-term follow-up is needed.

Conclusions

Before septoplasty, the most important symptom was nasal obstruction. Intervention involving the inferior turbinate during surgery increases the benefits of septoplasty independently of the surgical technique. Although factors such as asthma, OSA, smoking and age did not significantly affect symptom outcomes, pre- and postoperative scores were higher in those with asthma and OSA. Therefore, it is important to consider these diseases before septoplasty and inform patients accordingly.

Conflict of interest statement

None declared.

References

1. Hatipoglu HG, Cetin MA, Yuksel E. *Nasal septal deviation and concha bullosa coexistence: CT evaluation.* B-ENT 2008;4:227-32.
2. Zielnik-Jurkiewicz B, Olszewska-Sosinska O. *The nasal septum deformities in children and adolescents.* Int J Pediatr Otorhinolaryngol 2006;70:731-6.
3. Stewart MG, Witsell DL, Smith TL, et al. *Development and validation of the nasal obstruction symptom evaluation (NOSE) scale.* Otolaryngol Head Neck Surg 2004;130:157-63.
4. Bugten V, Nilsen AH, Thorstensen WM, et al. *Quality of life and symptoms before and after nasal septoplasty compared with healthy.* BMC Ear Nose Throat Disord 2016;16:13.
5. Hytönen ML, Lilja M, Mäkitie AA, et al. *Does septoplasty enhance the quality of life in patients?* Eur Arch Otorhinolaryngol 2012;269:2497-503.
6. Buckland JR, Thomas S, Harries PG. *Can the sino-nasal outcome test (SNOT-22) be used as a reliable outcome measure for successful septal surgery?* Clin Otolaryngol 2003;28:43-7.
7. Hytönen M, Blomgren K, Lilja M, et al. *How we do it: septoplasties under local anaesthetic are suitable for short stay surgery; the clinical outcomes.* Clin Otolaryngol 2006;31:64-8.
8. Arunachalam PS, Kıtcher E, Grayy J, et al. *Nasal septal surgery: evaluation of symptomatic and general health outcomes.* Clin Otolaryngol 2001;26:367-70.
9. Cantone E, Ricciardiello F, Oliva F, et al. *Septoplasty: is it possible to identify potential "predictors" of surgical success?* Acta Otorhinolaryngol Ital 2018;38:528-35.
10. Magliulo G, Iannella G, Ciofalo A, et al. *Nasal pathologies in patients with obstructive sleep apnoea.* Acta Otorhinolaryngol Ital 2019 Mar 25. doi: 10.14639/0392-100X-2173 [Epub ahead of print].
11. Acevedo JL, Camacho M, Brietzke SE. *Radiofrequency ablation turbinoplasty versus microdebrider-assisted turbinoplasty: a systematic review and meta-analysis.* Otolaryngol Head Neck Surg 2015;153:951-6.
12. Cingi C, Ure B, Cakli H, et al. *Microdebrider-assisted versus radiofrequency-assisted inferior turbinoplasty: a prospective study with objective and subjective outcome measures.* Acta Otorhinolaryngol Ital 2010;30:138-43.
13. Hancı D, Altun H, Sahin E, et al. *Turkish translation, cross-cultural adaptation and validation of the SinoNasal Outcome Test (SNOT)-22.* ENT Updates 2015;5:51-7.
14. Hopkins C, Gillett S, Slack R, et al. *Psychometric validity of the 22-item sinonasal outcome test.* Clin Otolaryngol 2009;34:447-54.
15. Fokkens WJ, Lund VJ, Mullol J, et al. *European position paper on rhinosinusitis and nasal polyps. A summary for otorhinolaryngologists.* Rhinology 2012;50:1-12.
16. Gandomi B, Bayat A, Kazemei T. *Outcomes of septoplasty in young adults, the nasal obstruction septoplasty effectiveness study.* Am J Otolaryngol 2010;31:189-92.

Received: March 27, 2018 - Accepted: May 27, 2018

How to cite this article: Dizdar D, Bozan A, Dizdar SK, et al. *Evaluation of nasal symptoms in septoplasty patients using SNOT-22*. Acta Otorhinolaryngol Ital 2019;39:98-102. https://doi.org/10.14639/0392-100X-2061

Address for correspondence: Denizhan Dizdar, Istanbul Kemerburgaz University, Medical Faculty, Department of Otorhinolaryngology, Istanbul, Turkey. Tel. +90 5555476856. Fax +90 0212 2893647. E-mail: denizhandizdar@hotmail.com

ACTA OTORHINOLARYNGOLOGICA ITALICA 2019;39:103-106; doi: 10.14639/0392-100X-1796 OPEN ACCESS

AUDIOLOGY

Right-to-left shunt and idiopathic sudden sensorineural hearing loss

Shunt destro-sinistro e ipoacusia neurosensoriale improvvisa idiopatica

L. CAPUANO[1], M. CAVALIERE[1], D. LOPARDO[2], G. PARENTE[1], A. DAMIANO[2], R. PERONE[2], A. MARINO[1], P. BOTTIGLIERI[3], M. IEMMA[1]

[1] Department of Otorhinolaryngology; [2] Department of Diving Medicine and Hyperbaric Therapy; [3] Department of Intensive Cardiac Therapy, University Hospital "San Giovanni di Dio e Ruggi d'Aragona", Salerno, Italy

SUMMARY

In the present retrospective cohort study, we investigated the association between idiopathic sudden sensorineural hearing loss (ISSNHL) and right-to-left shunt (RLS). For this study, we recruited 40 patients with ISSNHL treated in our department between January 2015 and January 2016. Inclusion criteria were: ≥ 18 years old, unilateral sensorineural hearing loss diagnosed within 2 weeks after onset, unknown cause, no previous surgery in the respective ear and no fluctuation in hearing loss. All patients underwent a pure-tone audiogram and a trans-cranial Doppler ultrasonography (TCD) with contrast saline (c-TCD) and received hyperbaric oxygen (HBO) and concomitant steroid therapy. C-TCD examination detected the RLS in 20 patients (50%). ISSNHL patients with RLS were younger than those without RLS (p = 0.007). Vertigo was present mainly in the RLS group, while hypercholesterolaemia, arterial hypertension and hyperglycaemia were mainly seen in the "no RLS" group. The proportion of complete recovery was highest in the "No RLS" Group (40%), although it was not statistically significant. In conclusion, RLS is frequent in ISSNHL, particularly in young patients without comorbidities and with associated dizziness, who should routinely undergo TCD to exclude the presence of RLS. Unfortunately, TCD can only detect the RLS, and not the location of the shunt. This would be possible through transesophageal echocardiography (TEE) or intracardiac echocardiography (ICE), which are much more invasive than TCD, and require further study.

KEY WORDS: Sudden sensorineural hearing loss • Right-to-left shunt • Hyperbaric oxygen therapy

RIASSUNTO

Nel presente studio retrospettivo di coorte, abbiamo esaminato l'associazione tra ipoacusia neurosensoriale improvvisa idiopatica (ISSNHL) e lo shunt destro-sinistro (RLS). Lo studio è stato condotto su 40 pazienti con ISSNHL trattati presso il nostro dipartimento tra gennaio 2015 e gennaio 2016. I criteri di inclusione sono stati: età ≥ 18 anni, ipoacusia neurosensoriale monolaterale diagnosticata entro 2 settimane dopo la sua comparsa, causa sconosciuta, anamnesi negativa per pregressi interventi chirurgici all'orecchio corrispondente, assenza di fluttuazioni dell'ipoacusia. Tutti i pazienti sono stati sottoposti ad audiometria tonale e ad esame ultrasonografico Doppler trans-cranico (TCD) con contrasto salino (c-TCD) e sono stati trattati con ossigenoterapia iperbarica (HBO) e concomitante terapia steroidea. L'esame C-TCD ha rilevato uno shunt destro-sinistro (RLS) in 20 pazienti (50%). I pazienti affetti da ISSNHL con RLS erano più giovani rispetto a quelli senza RLS (p = 0,007). La presenza di vertigini è stata osservata soprattutto nel gruppo con RLS, mentre l'ipercolesterolemia, l'ipertensione arteriosa e l'iperglicemia sono stati osservati soprattutto nel gruppo senza RLS. La percentuale di completa guarigione è stata più alta nel gruppo senza (40%), sebbene non statisticamente significativa. In conclusione, il riscontro di RLS è frequente nell'ISSNHL, particolarmente in giovani pazienti senza comorbidità e con associato disequilibrio, i quali dovrebbero essere regolarmente sottoposti ad esame ultrasonografico Doppler trans-cranico per escludere la presenza di RLS. Purtroppo, il TCD può solo rilevare l'RLS, non la posizione dello shunt. Ciò sarebbe possibile attraverso l'ecocardiografia transesofagea (TEE) o l'ecocardiografia intracardiaca (ICE), che sono molto più invasive del TCD, e richiede ulteriori studi.

PAROLE CHIAVE: *Ipoacusia neurosensoriale improvvisa • Shunt destro-sinistro • Ossigenoterapia iperbarica*

Introduction

Idiopathic sudden sensorineural hearing loss (ISSNHL) is a clinical emergency characterised by a 30 dB hearing loss over three contiguous frequencies occurring within 3 days [1]. Its aetio-pathogenesis is not well known. Researchers have suggested viral infection, vascular compromise, intracochlear membrane rupture and immune inner ear disease [2]. Right-to-left shunt (RLS) is one of the most important causes of ischaemic stroke in patients without vascular risk factors or other causes of embolism [3].

This study investigated the association between ISSNHL and the presence of RLS and derives from the observation of some authors who report a very high incidence of RLS (73-83%) in divers with "inner ear decompression sickness" vs 25-30% in control subjects [4 5].

© Società Italiana di Otorinolaringoiatria e Chirurgia Cervico-Facciale

Materials and methods

Study subjects included patients with ISSNHL treated in our department between January 2015 and January 2016. In this retrospective study, we evaluated the incidence of RLS and its influence on hearing loss severity and recovery. The ethics committee of our institution approved the present study.

Patients

Subjects met the following inclusion criteria: ≥ 18 years old, unilateral sensorineural hearing loss diagnosed within 2 weeks after onset; unknown cause of hearing loss (based on complete history review, clinical evaluation, blood tests, imaging exams - MRI, CT); no previous surgery in the respective ear; no fluctuation in hearing loss. We obtained all pure-tone audiograms at the time of initial presentation (day 0) and on days 30, 60, 90, and 180 after the initiation of treatment. We recorded hearing thresholds at 250; 500; 1,000; 2,000; 4,000 and 8,000 Hz.

Treatment

All patients received hyperbaric oxygen (HBO) and concomitant steroid therapy, i.e. the treatment which in the experience of us and others [6-8] has given the best results.
The steroid protocol included intravenous metilprednisolone at decreasing doses of 40 mg for 7 days, and 20 mg for other 3 days. HBO therapy was practiced daily from Monday through Friday for 16 sessions at 2.5 ATA with 90 min per session.

Evaluation criteria

All patients underwent a pure-tone audiogram from 250 Hz to 8 KHz. The audiometric tests conformed to the specification in ISO 8253 (Acoustic Audiometric test methods; basic pure tone and bone conduction audiometry, International Organization for Standardization, Geneva, Switzerland). We evaluated the pure-tone average (PTA) for each audiogram by calculating the mean of thresholds at 500; 1,000; 2,000 and 4,000 Hz. Hearing recovery was classified into three grades [3], as follows: I Good: hearing returned within 15 dB of the unaffected contralateral ear; II Fair: hearing level improved by more than 10 dB, but did not return to within 15 dB of the unaffected ear; III Poor: no change in hearing level, improved ≤ 10 dB or even deteriorated after treatment.
All patients also underwent a trans-cranial Doppler ultrasonography (TCD) with contrast saline (c-TCD), performed by a specialist cardiologist to detect RLS. The middle cerebral artery (MCA) was identified from the temporal window at a depth of 50-55 mm using a 2-MHz hand-held transducer (Pioneer TC 8080; Nicolet Vascular, Madison, Wisc, USA) continuously monitoring the flow signals. For the c-TCD study, we used a mixed saline (9 ml) and air (1 ml) solution, agitated between two 10-ml syringes connected via a 3-way stopcock. An indwelling catheter placed in the anterior cubital vein injected bubble-containing saline under 2 conditions: I no Valsalva manoeuvre; II Valsalva manoeuvre for 10 s, starting 5 s after the start of bubble containing saline introduction. We diagnosed RLS if one micro-bubble was noted in 1 vessel within 40 s after injection. The size of the shunt was classified as minor (from 1 to 10 micro-bubbles), moderate (more than 10 micro-bubbles, but without the drop-down effect) or severe (more than 10 micro-bubbles and with the drop-down effect).
Statistical analysis was conducted using the Pearson chi-squared test followed by Fisher's exact test as a post hoc test. We considered differences at $p < 0.05$ as significant.

Results

Our study included 40 patients (40 diseased ears) treated at our clinic (Table I).
C-TCD examination allowed us to detect RLS in 20 patients (50%). ISSNHL patients with RLS were younger than those without RLS and the right ear was mainly interested ($p = 0.007$ and 0.009 respectively).
Vertigo at onset was seen in 80% of patients with RLS and in 20% without RLS ($p = 0.07$).
Hypercholesterolaemia (> 240 mg/dL), arterial hypertension and hyperglycaemia were seen mainly in the "no RLS" group ($p = 0.004$, 0.07 and 0.2 respectively).
Mean gain in the "RLS" group was numerically worse than the "No RLS" group, although it was not statistically significant (Table II). We did not observe any relation between RLS severity and pre- or post-treatment PTA (Table III).

Discussion

This study, the first in the literature, examines the characteristics of patients with RLS and ISSNHL and the impact of the RLS on auditory recovery. ISSNHL, described by De Kleyn in 1944, is a hearing loss of at least 30 dB in three sequential frequencies in the standard pure-tone audiogram occurring within 3 days [4]. Incidence of ISSNHL is between 5 and 30 cases per 100,000 per year. A specific cause is generally found in about 10% of patients [9]. To explain mechanisms of sudden deafness, two common theories have been proposed: an inflammatory reaction and a circulatory disturbance.

Table I. Baseline characteristics of the study population.

	RLS	No RLS	P values
No. of patients	20	20	
Age (mean ± SD)	33 ± 8.23	45.20 ± 7.05	0.007
Gender (M/F)	12/8	8/12	0.579
Side (right/left)	16/4	0/20	0.009
Pre-treatment PTA (dB)	74 ± 10.84	74 ± 28.81	1
Vertigo (%)	80	20	0.07
Comorbidities (%)			
arterial hypertension	20	80	0.07
hyperglycaemia	20	60	0.24
hypercholesterolemia	0	80	0.004
dysthyroidism	0	0	1

Table II. Response to therapy.

	RLS	No RLS	P values
Pre-treatment PTA (dB)	74 ± 10.84	74 ± 28.81	1
Post-treatment PTA (dB)	51 ± 20.12	43 ± 27.52	0.55
good recovery	20%	40%	0.54
fair recovery	40%	40%	1
poor recovery	40%	20%	0.54

Table III. RLS severity and hearing loss.

	RLS minor	RLS severe	P values
Pre-treatment PTA (dB)	73.33 ± 2.89	75 ± 21.21	0.89
Post-treatment PTA (dB)	48.33 ± 27.54	55 ± 7.07	0.77

The higher prevalence of RLS in our patients (50%) compared with 25-30% in the control population suggests that sudden deafness may be attributable to a paradoxical embolism, i.e. emboli from venous circulation as a result of RLS [3 10].

Numerous studies have confirmed that patients with RLS have a risk of thrombo-embolic event that is four times higher than those without RLS and have an increased risk (3.4% annually) of recurrent stroke or transient ischaemic attack [11 12].

The paradoxical embolism might provoke transient occlusion of the internal auditory artery (labyrinthine artery) that supplies blood to both the cochlea and the vestibule. If thrombosis occludes the internal auditory artery, vertigo and hearing loss may occur [4]. In our series, in fact, 16 of 20 sudden deafness patients with RLS (80%) had vertigo at the onset of sudden deafness.

ISSNHL patients with RLS were younger than those without RLS in our series, in accordance with previous authors who reported that the incidence of RLS gradually declines with increasing age [3 13].

However, we did not find relationship between the degree of deafness and RLS severity, the presence of RLS or hearing recovery. Other authors [14] have shown that cardiovascular risk factors do not have any significant influence on threshold recovery in ISSNHL, although they are involved in its pathogenesis.

Conclusions

RLS is frequent in ISSNHL, particularly in young patients without comorbidities and with associated dizziness. However, in our initial study we did not find any significant association of hearing recovery in the RLS group. Furthermore, the TCD can only detect the RLS, not the location of the shunt. This would be possible through trans-oesophageal echocardiography (TEE) or intracardiac echocardiography (ICE), which are much more invasive than TCD.

Therefore, based on our current data, we cannot routinely recommend TCD to exclude the presence of RLS, but only in young patients without comorbidities.

Further studies on a larger group are necessary to confirm these results, to detect the location of the shunt and evaluate whether patients with RLS are more susceptible to sudden deafness recurrence as for stroke [15].

Conflict of interest statement

None declared.

References

1. Stachler RJ, Chandrasekhar SS, Archer SM, et al. *Clinical practice guideline: sudden hearing loss.* Otolaryngol Head Neck Surg 2012;146:S1-35.
2. Shaia FT, Sheehy JL. *Sudden sensori-neural hearing impairment: a report of 1,220 cases*. Laryngoscope 1976;86:389-98.
3. Iguchi Y, Kimura K, Kobayashi K, et al. *Sudden deafness and right-to-left shunts.* Cerebrovasc Dis 2008;26:409-12.
4. Schreiber BE, Agrup C, Haskard DO, et al. *Sudden sensorineural hearing loss.* Lancet 2010;375:1203-11.
5. Tremolizzo L, Malpieri M, Ferrarese C, et al. *Inner-ear decompression sickness: 'hubble-bubble' without brain trouble?* Diving Hyperb Med 2015;45:135-6.
6. Capuano L, Cavaliere M, Parente G, et al. *Hyperbaric oxygen for idiopathic sudden hearing loss: is the routine application helpful?* Acta Otolaryngol 2015;135:692-7.
7. Topuz E, Yigit O, Cinar U, et al. *Should hyperbaric oxygen be added to treatment in idiopathic sudden sensorineural hearing loss?* Eur Arch Otorhinolaryngol 2004;261:393-6.
8. Fujimura T, Suzuki H, Shiomori T, et al. *Hyperbaric oxygen and steroid therapy for idiopathic sudden sensorineural hearing loss.* Eur Arch Otorhinolaryngol 2007;264:861-6.
9. Rossini BAA, Penido NO, Munhoz MSL, et al. *Sudden sensorioneural hearing loss and autoimmune systemic diseases.* Int Arch Otorhinolaryngol 2017;21:213-23.

[10] Ignatescu M, Bryson P, Klingmann C. *Susceptibility of the inner ear structure to shunt-related decompression sickness.* Aviat Space Environ Med 2012;83:1145-51.

[11] Sun YP, Homma S. *Patent foramen ovale and stroke.* Circ J 2016;80:1665-73.

[12] Katsanos AH, Spence JD, Bogiatzi C, et al. *Recurrent stroke and patent foramen ovale: a systematic review and meta-analysis.* Stroke 2014;45:3352-9.

[13] Hagen PT, Scholz DG, Edwards WD. *Incidence and size of patent foramen ovale during the first 10 decades of life: an autopsy study of 965 normal hearts.* Mayo Clin Proc 1984;59:17-20.

[14] Ciorba A, Hatzopoulos S, Bianchini C, et al. *Idiopathic sudden sensorineural hearing loss: cardiovascular risk factors do not influence hearing threshold recovery.* Acta Otorhinolaryngol Ital 2015;35:103-9.

[15] Windecker S, Stortecky S, Meier B. *Paradoxical embolism.* J Am Coll Cardiol 2014;64:403-15.

Received: October 12, 2017 - Accepted: July 15, 2018

How to cite this article: Capuano L, Cavaliere M, LoPardo D, et al. *Right-to-left shunt and idiopathic sudden sensorineural hearing loss.* Acta Otorhinolaryngol Ital 2019;39:103-106. https://doi.org/10.14639/0392-100X-1796

Address for correspondence: Matteo Cavaliere, via Madonna di Fatima 53, 84084 Fisciano (SA), Italy. E-mail: matorl@inwind.it

ACTA OTORHINOLARYNGOLOGICA ITALICA 2019;39:107-116; doi: 10.14639/0392-100X-2144 OPEN ACCESS

AUDIOLOGY

Validation of the Chronic Tinnitus Acceptance Questionnaire (CTAQ-I): the Italian version

Validazione della versione italiana del Questionario sull'Accettazione dell'Acufene Cronico (CTAQ-I)

R. MOSCHEN[1], A. FIORETTI[2], A. EIBENSTEIN[2], E. NATALINI[2], G. CHIARELLA[3], P. VIOLA[3], D. CUDA[4], C. CASSANDRO[5], A. SCARPA[6], G. RUMPOLD[1], D. RIEDL[1]

[1] University Clinic of Medical Psychology, Medical University of Innsbruck, Austria; [2] Tinnitus Center, European Hospital, Rome, Italy: [3] Department of Experimental and Clinical Medicine, Unit of Audiology and Phoniatrics, University "Magna Graecia" of Catanzaro, Italy; [4] Department of Otorhinolaryngology, "Guglielmo da Saliceto" Hospital, Piacenza, Italy; [5] ENT Department, "San Giovanni Battista" Hospital, University of Torino, Italy; [6] UO Otorinolaringoiatria - AOU "San Giovanni di Dio e Ruggi d'Aragona" of Salerno, Italy

SUMMARY

Tinnitus is a widespread symptom that is chronically experienced by approximately 10% of the adult population. While the vast majority of individuals do not feel impaired by their ear noise, about 0.5-3% of the adult population develops severe distress and feels impaired in everyday life. The severity of the distress experienced can only partially be explained by the characteristics of the ear noise itself (e.g. objective tinnitus loudness or duration). Psychological variables such as tinnitus acceptance are being increasingly investigated by tinnitus research. The aim of this study was to analyse the psychometric quality of the Italian version of the "Chronic Tinnitus Acceptance Questionnaire" (CTAQ-I). The CTAQ-I is an adaption of the Italian "Chronic Pain Acceptance Questionnaire (CPAQ)" and altered for the study of tinnitus acceptance. This cross-sectional multicentre questionnaire study included 141 outpatients with chronic tinnitus. Sociodemographic and clinical data were assessed with the Tinnitus Sample Case History (TSCH), tinnitus acceptance with the Italian "Chronic Tinnitus Acceptance Questionnaire" (CTAQ-I), tinnitus distress with the Tinnitus Handicap Inventory (THI) and the Tinnitus Questionnaire Short Form (TQ 12-I). Furthermore, we assessed the patient's general psychological distress (Brief Symptom Inventory - BSI) and Health Related Quality of Life (SF-36). Psychometric and factorial evaluation of the CTAQ-I were carried out. To investigate the influence of sociodemographic and numerous clinical variables on tinnitus acceptance we calculated correlation coefficients, analysis of variance and independent sample-t-tests. The factor analysis revealed a two-factor solution ("activity engagement" and "tinnitus willingness"), accounting for 41.1% of the variance. Good internal consistency for the total score ($\alpha = 0.84$) and both factors ($\alpha = 0.80$-0.88) was found. Moderate negative correlations with tinnitus distress indicated good validity. Tinnitus acceptance was further correlated with lower psychological distress and subjective tinnitus loudness, as well as increased emotional well-being. Tinnitus acceptance is considered to be an important source of therapeutic change in behavioural-based treatments as well as in professional counselling for tinnitus. Our study shows that the CTAQ-I is a reliable and valid instrument to measure the acceptance of patients suffering from chronic tinnitus.

KEY WORDS: Chronic Tinnitus Acceptance Questionnaire • Acceptance • Tinnitus • Questionnaire • Italian • Validation

RIASSUNTO

L'acufene è un sintomo ampiamente diffuso, rappresenta una condizione cronica per circa il 10% della popolazione adulta. La maggioranza dei pazienti non si sente danneggiata dall'acufene, ma circa lo 0,5-3% della popolazione adulta sviluppa un grave disagio e si sente compromesso nella vita di tutti i giorni. Quanto grave sia il disagio provato può essere solo parzialmente spiegato dalle caratteristiche dell'acufene stesso (come intensità o durata). Le variabili psicologiche, come l'accettazione dell'acufene, sono sempre più indagate dalla ricerca. Lo scopo di questo studio è analizzare la qualità psicometrica della versione italiana del Chronic Tinnitus Acceptance Questionnaire, "Questionario sull'accettazione dell'acufene cronico" (CTAQ-I). Il CTAQ-I è un adattamento del questionario italiano sull' accettazione del dolore cronico (CPAQ), adattato per lo scopo dello studio dell'acufene cronico. Studio multicentrico trasversale mediante questionario su 141 pazienti ambulatoriali con acufene cronico. I dati sociodemografici e clinici sono stati valutati con la Tinnitus Sample Case History (TSCH), l'accettazione dell'acufene con il "Questionario sull'accettazione dell'acufene cronico" (CTAQ-I), il disagio dell'acufene con la Tinnitus Handicap Inventory (THI) e il mini Questionnaire (TQ 12-I). Inoltre abbiamo valutato il disagio psicologico generale del paziente (Brief Symptom Inventory - BSI) e la qualità della vita correlata alla salute (SF-36). Sono state condotte valutazioni psicometriche e fattoriali del CTAQ-I. Per studiare l'influenza delle variabili sociodemografiche e numerose variabili cliniche sull'accettazione dell'acufene, abbiamo calcolato i coefficienti di correlazione, l'analisi della varianza e il test T per campioni indipendenti. L'analisi fattoriale ha rivelato una soluzione a due fattori ('activity engagement' e 'tinnitus willingness'), che rappresentano il 41,1% della varianza. È stata trovata una buona coerenza interna per il punteggio totale ($\alpha = 0,84$) ed entrambi i fattori ($\alpha = 0,80$-$0,88$). Le moderate correlazioni negative con il disagio indicavano una buona validità. L'accettazione dell'acufene era ulteriormente correlata a un minore stress psicologico e minore volume dell'acufene soggettivo, oltre che ad un maggiore benessere emotivo. L'accettazione dell'acufene è considerata un'importante risorsa terapeutica di cambiamento nei trattamenti (comportamentali e di counseling professionale) per l'acufene. Il nostro studio mostra che il CTAQ-I è uno strumento affidabile e valido per misurare l'accettazione dell'acufene cronico da parte dei pazienti.

PAROLE CHIAVE: *Questionario di accettazione dell'acufene cronico • Accettazione • Acufene • Questionario • Italiano • Validazione*

© Società Italiana di Otorinolaringoiatria e Chirurgia Cervico-Facciale

Introduction

Tinnitus is defined as the perception of sound in the absence of a corresponding auditory source. Epidemiological studies report a prevalence of 10-16% for chronic tinnitus in the adult population, which increases with age [1 2]. While the vast majority of individuals are unaffected by tinnitus, 0.5-3% of the adult population report impairing tinnitus-associated symptoms of disturbed sleep and decreased cognitive functions, irritability, disruption of everyday activities as well as psychological problems such as anxiety and depressive symptoms [3 4]. Distressing tinnitus is often associated with audiological dysfunctions, noise sensitivity and impaired quality of life of patients and in many cases their relatives as well [5-7].

The subjectively experienced strain due to tinnitus can only partially be explained by psychoacoustic parameters such as objective tinnitus loudness or duration [8]. A large body of literature suggests that tinnitus related cognitions (e.g. catastrophic thinking), emotions (e.g. anxiety and depression) and personality traits as well as coping strategies play an important role in tinnitus perception and distress [9-12].

Since there is no specific pharmacological treatment available to cure chronic tinnitus [13], at present therapeutic strategies support the process of coping with tinnitus, building stress management and treating comorbid symptoms. Cognitive behavioural interventions are, in addition to multimodal therapies, the most widely used treatment strategies [13]. Independent meta-analyses and systematic reviews revealed convincing evidence for the efficacy of cognitive behavioural therapies to reduce tinnitus-related distress [14 15].

In the recent development of cognitive-behavioral treatments, acceptance- and mindfulness-based approaches, such as the "Acceptance and Commitment Therapy" or the "Mindfulness-Based Cognitive Therapy", have been integrated in the treatment of tinnitus [16-18]. These approaches are considered particularly relevant when dealing with a chronic problem, such as chronic tinnitus. There are a growing number of experiential, correlational and outcome studies showing that tinnitus related acceptance is related to better functioning and well-being [18-22].

The word "acceptance" takes its roots from the Latin word "accipere" which means "admit, let in, hear, learn". Psychological acceptance is also described as a mindful and non-evaluative approach to internal experiences such as emotions, physical sensations or thoughts. Acceptance has been further described as the openness to experience thoughts and emotions as they are, while refraining from attempting to direct and actively change these situations, feelings, and thoughts. Psychological acceptance does not equate to an attitude of resignation or "giving up", but is characterised by an active shaping of the situation in the presence of tinnitus. Currently, it is not entirely clear which specific individual coping strategies are useful or maladaptive for long-term adaptation to chronic tinnitus. A useful model for the understanding of the tinnitus adaptation process and the value of acceptance is provided by the "dual-process model of coping" by Brandtstädter and Renner [23]. It distinguishes between two complementary coping strategies: accommodative and assimilative coping. The assimilative coping mode is characterised by active attempts to change or control a stressful situation, like a chronic burden or health impairment. This persistent way of pursuing one's goal can include activities such as acquiring relevant knowledge and skills, or using compensatory means (e.g. using external support sources such as hearing aids and sound generators to solve the problem). When a problem remains unresolved and blocks life goals, the level of stress usually increases and a transition from assimilative to accommodative coping may be required. Accommodative coping is the flexible adjustment of individual goals and preferences to situational constraints or limitations. This can involve the devaluation or reevaluation of a particular goal (e.g. the elimination of tinnitus), as well as the consideration of alternative feasible goals. The acceptance of adverse consequences and uncontrollability of an insoluble problem is often considered as a key process in accommodative coping.

For many patients, the word acceptance has a bad overtone because it means to give up the expectation of getting rid of their tinnitus. Patients often maintain a high level of activity to avoid "giving up" or passive suffering from tinnitus or are constantly struggling against it. This may also include a constant search for new treatments and at considerable personal and financial costs. These constant strong assimilative efforts toward a blocked target (i.e. the extinction of tinnitus) can lead to the exhaustion of one's own action resources and increased psychological distress.

On a theoretical level, acceptance is closely related to its opposite psychological process - experiential avoidance (EA). EA is defined as the avoidance of internal sensations, thoughts etc. Avoidance behaviour may intensify negative thoughts [24] and is linked to more distressing tinnitus as well as increased anxiety and tinnitus-related distress. Patients suffering from chronic tinnitus often avoid specific situations, including silence as well as certain sounds that are perceived as annoying [25]. Some patients remove themselves from social relations to offer protect from noise pollution [26] or to avoid high (sometimes po-

tentially harmful) noise levels [27]. Another avoidance tactic used is to mask the tinnitus by persistently distracting oneself using background sounds like radio or TV-sets. Although EA is associated with short-term relief, in the long run it strongly impairs the patients' quality of life. While trying to protect oneself from a disabling tinnitus by avoiding its perception and associated emotions and thoughts, this may paradoxically lead to increased anxiety and tinnitus-related distress [28].

Acceptance refers to a process by which the tinnitus and associated thoughts and feelings lose their functional influence on overt behaviour, since the target of control is changed from uncontrollable factors (i.e. the tinnitus itself) to more controllable factors (i.e. changing behaviour to increase daily function despite tinnitus).

In order to evaluate the efficacy of acceptance-orientated treatment, specific and validated instruments to measure acceptance are necessary. In the treatment of chronic pain, acceptance-oriented instruments such as the "Chronic Pain Acceptance Questionnaire" (CPAQ) have already been developed and validated. Due to various similarities often described between chronic pain and chronic tinnitus – both groups suffer from intractable sensory symptoms and demonstrate problems with aspects of focus/attention, perceived lack of control over symptoms, catastrophic thinking and maladaptive coping strategie – the CPAQ has been adapted for tinnitus in English (Moreland 2009, unpublished thesis) as well as German [29]. To our knowledge no tinnitus acceptance questionnaire has been developed in Italian thus far.

Therefore, the aim of the present study was to evaluate the psychometric properties of the Italian CTAQ-I and to investigate its relationship to tinnitus distress, well-being and psychological distress.

Materials and methods

Sample and setting

The sample of this cross-sectional multicentre study consisted of 150 outpatients which were included from the following healthcare institutions: Tinnitus Centre, European Hospital (Rome), the Department of Otorhinolaryngology, "Guglielmo da Saliceto" Hospital (Piacenza), and the Department of Experimental and Clinical Medicine, Unit of Audiology and Phoniatrics, University "Magna Graecia" (Catanzaro). Patients were included in the study if they: (a) had tinnitus for at least 3 months, (b) were older than 18 years, (c) spoke Italian fluently and (d) had no apparent cognitive impairment. The patients completed the questionnaires as part of routine clinical practice.

All procedures performed in studies involving human participants were in accordance with the ethical standards of the institutional and/or national research committee and with the 1964 Helsinki declaration and its later amendments. The study was performed in three ENT centres in Italy, namely Rome, Catanzaro and Piacenza. Heads of these centres (MD Alberto Eibenstein, MD Giuseppe Chiarella and MD Domenico Cuda) agreed on the procedures and provided access to tinnitus patients. Participation was voluntary and each patient gave written consent before filling out the questionnaires.

Measures

Tinnitus Sample Case History (TSCH)

Sociodemographic and clinical data were assessed with the Italian version of the TSCH. It was developed by the Tinnitus Research Initiative as an attempt to standardise the assessment of sociodemographic and clinical data in tinnitus research [30]. The questionnaire consists of 35 items on background (i.e. age, gender), tinnitus history (i.e. loudness, pitch, percentage of awake time aware of tinnitus, hyperacusis) and related conditions (i.e. hearing impairment, noise annoyance, vertigo/dizziness).

Chronic Tinnitus Acceptance Questionnaire - Italian version (CTAQ-I)

The acceptance of chronic tinnitus was measured by the Italian version of the "Chronic Tinnitus Acceptance Questionnaire" (CTAQ-I). This is an adaption of the validated Italian version [31] of the "Chronic Pain Acceptance Questionnaire" (CPAQ) [32] for tinnitus, replacing the word "pain" with "tinnitus" or "ear noise". The CTAQ-I consists of 20 items, rated on a 7-point Likert scale (0 = never true, 6 = always true) for rating tinnitus acceptance. Eleven items measure the extent of participation in normal daily activities regardless of acknowledged tinnitus ("activity engagement", AE) and the remaining nine reverse-keyed items measure the willingness to have tinnitus present without trying to avoid or reduce it ("Tinnitus Willingness", TW). The CTAQ-I total score ranges from 0-120, with a higher score indicating higher acceptance of tinnitus. A validation of the German version of the CTAQ (CTAQ-G) has shown an internal consistency of $\alpha = 0.85$ [29].

Tinnitus Handicap Inventory (THI)

The Tinnitus Handicap Inventory (THI) is a self-administered tool, widely used in tinnitus research and in clinical contexts, to assess the impact of the tinnitus in daily life. It consists of 25 items that can be divided in a functional, emotional and catastrophic subscale. Based on the total score tinnitus severity can be graded from slight (grade 1)

to catastrophic (grade 5). Good reliability (α = 0.94) and validity was reported for the total score of the Italian THI version [33].

Tinnitus Questionnaire (TQ 12)
Tinnitus distress was also measured with the Italian 12 item short form of the Tinnitus Questionnaire (TQ 12-I) [34]. For the TQ 12-I, good reliability and validity were reported. The total score allows the classification of the patients as compensated (0-7), moderately distressed [8-12], severely distressed [13-18], and most severely distressed [19-24].

Brief Symptom Inventory (BSI)
Mental health symptoms and psychological distress were assessed with the Brief Symptom Inventory. The BSI consists of 53 items to capture global psychological distress. Good reliability and validity for the subscales and total score were reported [35].

Short Form (36) Health Survey
The health status was measured with the Short Form Health Survey (SF-36), a broadly used, well established instrument to assess the Health-Related Quality of Life (HRQOL). The SF-36 consists of 36 items which can be divided into a physical and psychological total score. The subscale's internal consistencies were tested in nine samples, showing a Cronbach's α between 0.77-0.93. Good validity has been reported in several studies [36].

Statistical analysis
Psychometric values (means, standard deviations, item-total correlations) of the items are presented. A factor analyses (maximum likelihood, direct oblimin) with a fixed number of factors was conducted to investigate the proposed two-factor solution [29]. Scree plots and Eigenvalues were used to determine the ideal number of factors. Reliability was evaluated by calculating Cronbach's α (internal consistency) and item-total correlations. Validity was evaluated by two-sided Pearson correlations with the THI, TQ 12-I, BSI and SF-36 scores. Statistical analyses were conducted using IBM SPSS (ver. 22).

Results

Of the initial 150 patients, 4 (2.6%) were excluded because their tinnitus lasted less than three months and another 5 patients (3.3%) because of fully missing CTAQ data. The remaining 141 patients were included in the study of which 47.5% were recruited in Piacenza, 37.6% in Rome and 14.9% in Catanzaro. Their mean age was 53.8 years and 55% were men. The mean tinnitus duration was 7.5 years and a large proportion of the sample reported tinnitus in both ears. More than half of the sample had subjective hearing problems and about a third reported physical discomfort because of surrounding sounds (hyperacusis). About a quarter of the sample had undergone several treatments due to their tinnitus. Overall, patients were aware of their tinnitus (75.4%) and were annoyed (48.9%) about their time spent awake over the last month. Based on the THI total score, tinnitus distress was graded as follows: 19.1% very mild, 25.5% mild, 31.9% moderate, 14.9% severe and 7.1% catastrophic. For details see Table I.

Psychometric values
The mean, standard deviation and item-total correlation of each item included are presented in Table II. The mean total score was 73.6 (SD: 20.1), the mean "activity engagement" score was 42.4 (SD: 14.4) and the mean "tinnitus willingness" score was 31.2 (SD: 11.8).
We tested the proposed factor solution [29] by factor analysis (maximum likelihood). Bartlett's test of sphericity (χ^2 (171) = 1096.34, $p < 0.001$) was significant and the Kaiser-Meyer-Olkin measure verified the sampling adequacy for the analysis (KMO = 0.82). Initial Eigenvalues indicated that the two factors explained 41.1% of the variance (factor 1: 27.7%, factor 2: 13.5%). The diagonals of the anti-image correlation matrix were between 0.78 and 0.92. We were able to reproduce the proposed two-factor solution using oblique rotation (oblimin). While the scree plot supported a two-factor-solution (Fig. 1), the Eigenvalues indicated a four-factor solution. An exploratory factor analysis (maximum likelihood) without a predefined number of factors resulted in a four-factor solution, explaining 50.5% of the variance. Yet, this solution contained multiple cross-loadings and an inconclusive factorial structure. In the further calculations, the two-factor solution was used. Table III shows the factor loadings for the two-factor solution after rotation.
Good internal consistency was found for the total score (α = 0.84) as well as for the factor "activity engagement" (α = 0.88) and the factor "tinnitus willingness" (α = 0.80). The exclusion of item 3 would slightly improve the Cronbach's α for factor 1 (α = 0.89), but not for the total score, while the exclusion of item 7 would improve the internal consistency of both factor 2 (α =0.81) and the total score (α = 0.86). The item-total correlations were acceptable for all items, except item 3, 7, 11 and 16.

Validity analysis
For the CTAQ-I total score high negative correlations with both the TQ 12-I and THI total scores and the respective subscales were found, which indicated good convergent validity. Furthermore, elevated tinnitus acceptance was correlated negatively with higher global psychological

Table I. Clinical properties of the sample.

TN loudness: 0-100 (SD)	54.2 (28.4)
Missing	10 (7.1%)
Duration: years (SD)	7.5 (10.4)
Family history of tinnitus complaints	34 (24.1%)
Missing	1 (0.7%)
Subjective hearing problem	82 (58.2%)
Missing	1 (0.7%)
Hearing aid	19 (13.6%)
Missing	1 (0.7%)
Hyperacusis	53 (37.6%)
Missing	1 (0.7%)
Tinnitus loudness varies during the day	
Yes	94 (66.7%)
No	45 (31.9%)
Missing	2 (1.4%)
Pulsatile tinnitus	36 (25.7%)
If yes: with heartbeat	15 (10.7%)
If yes: different from heartbeat	21 (14.9%)
Location	
Right ear	29 (20.6%)
Left ear	34 (24.1%)
Both ears	60 (42.6%)
Inside the head	11 (7.8%)
Missing	7 (5.0%)
Pitch	
Very high frequency	20 (14.2%)
High frequency	56 (39.7%)
Medium frequency	48 (34.0%)
Low frequency	12 (8.5%)
Missing	5 (3.5%)
Number of treatments for tinnitus	
None	76 (53.7%)
One	37 (26.2%)
Several	20 (14.2%)
Many	6 (4.3%)
Missing	2 (1.4%)

distress (BSI total score) and positively with emotional well-being (SF-36 emotional score). Only for the CTAQ-I subscale "activity engagement" significant positive correlations with physical well-being (SF-36) were found. The two subscales activity engagement and tinnitus willingness were weakly correlated to each other ($r = 0.17$, $p = 0.045$). Details are presented in Table IV.

Correlation with clinical data

Neither gender ($p = 0.62$) nor age ($p = 0.68$) correlated with the patients' acceptance levels. While no correlation between the CTAQ-I total score and the tinnitus duration ($p = 0.34$) was found, acceptance was negatively correlated to the subjective tinnitus loudness ($r = – 0.27$, $p = 0.002$) and the percentage of time patients were annoyed by their tinnitus ($r = – 0.57$, $p < 0.001$). Additionally, the time patients were aware of their tinnitus was not correlated to their level of acceptance ($p = 0.19$).

Patients with a subjective hearing problem did not report significantly different CTQA-I scores than patients without subjective hearing problems ($p = 0.69$). No differences were found across the different subjective pitch-level ($p = 0.82$), and patients who experienced tinnitus with variable loudness did not significantly differ from those without varying tinnitus loudness ($p = 0.86$). On the other hand, patients with hyperacusis reported lower acceptance scores than patients without hyperacusis (66.4 vs 80.2 points; $t = 3.9$, $p < 0.001$). Acceptance significantly predicted tinnitus distress ($R^2 = 0.48$, $b = – 0.64$, $p < 0.001$), even after including hyperacusis in the model.

Discussion

The process of acceptance is increasingly gaining interest in the treatment of chronic tinnitus. Reliable and valid tools are needed to evaluate tinnitus acceptance in clinical practise and outcome research. The aim of the present study was to investigate the psychometric properties of the Italian version of the "Chronic Tinnitus Acceptance Questionnaire" (CTAQ-I) in a multicentre study in which 141 patients with tinnitus complaints from three study centres participated. The results of our study showed that the CTAQ-I is a reliable and valid measure for assessing the acceptance of chronic tinnitus.

To investigate the factorial structure of the CTAQ-I, we replicated the proposed two factor solution, but also calculated factor analyses with a three- and four-factor solution. The two-factor solution showed the clearest factor solution and accounted for 42.1% of the total variance; the results show an ever better fit than for the German version of the CTAQ. Although the 3- and 4-factor solutions explained slightly more variance, they also had several cross loadings and an inconclusive overall structure. We therefore decided to retain the original 2-factor solution. In conclusion, the results of our factor analyses support the two-factor structure, which is in line with the original pain acceptance questionnaire (CPAQ) [32] and the two previous validations of the CTAQ in English and German, who also reported a two-factor solution [29] (Moreland 2009, unpublished thesis).

The items that load on the factor "activity engagement", for example, include the full engagement in life (item 9: "I lead a full life even though I have tinnitus") and the pursuit of valu-

Table II. Mean, standard deviations and variance of the CTAQ-I.

		Mean	SD	Item-total correlation	Missing
1.	I am getting on with the business of living no matter what my level of tinnitus is	4.9	1.6	0.44	-
2.	My life is going well, even though I have chronic tinnitus	4.2	1.7	0.68	1.4%
3.	It's OK to experience ear noise	2.3	2.2	0.24	2.8%
4.	I would gladly sacrifice important things in my life to control this tinnitus better*	3.0	2.1	0.30	2.1%
5.	It's not necessary for me to control my ear noise in order to handle my life well	3.0	2.2	0.45	0.7%
6.	Although things have changed, I am living a normal life despite my chronic tinnitus	4.0	2.0	0.65	2.1%
7.	I need to concentrate on getting rid of my tinnitus*	3.6	2.2	0.13	-
8.	There are many activities I do when I experience tinnitus	4.5	1.9	0.59	-
9.	I lead a full life even though I have tinnitus	4.3	1.8	0.57	0.7%
10.	Controlling tinnitus is less important than other goals in my life	3.2	2.1	0.50	-
11.	My thoughts and feelings about tinnitus must change before I can take important steps in my life*	4.0	2.1	0.25	0.7%
12.	Despite the tinnitus, I am now sticking to a certain course in my life	4.3	2.1	0.46	1.4%
13.	Keeping my tinnitus level under control takes first priority whenever I am doing something*	3.6	2.1	0.49	0.7%
14.	Before I can make any serious plans, I have to get some control over my tinnitus*	4.5	1.9	0.53	-
15.	When my tinnitus increases, I can still take care of my responsibilities	4.3	2.0	0.33	-
16.	I will have better control over my life if I can control my negative thoughts about tinnitus*	3.1	2.3	0.23	-
17.	I avoid putting myself in situations where tinnitus might increase*	3.0	2.4	0.44	0.7%
18.	My worries and fears about what tinnitus will do to me are true*	3.2	2.2	0.57	0.7%
19.	It's a relief to realise that I don't have to change my tinnitus to get on with my life	3.8	2.0	0.44	1.4%
19.	I have to struggle to do things when I have tinnitus*	3.4	2.1	0.52	-

** inversed item scores; Item-total correlations were corrected for the individual contribution of each item.*

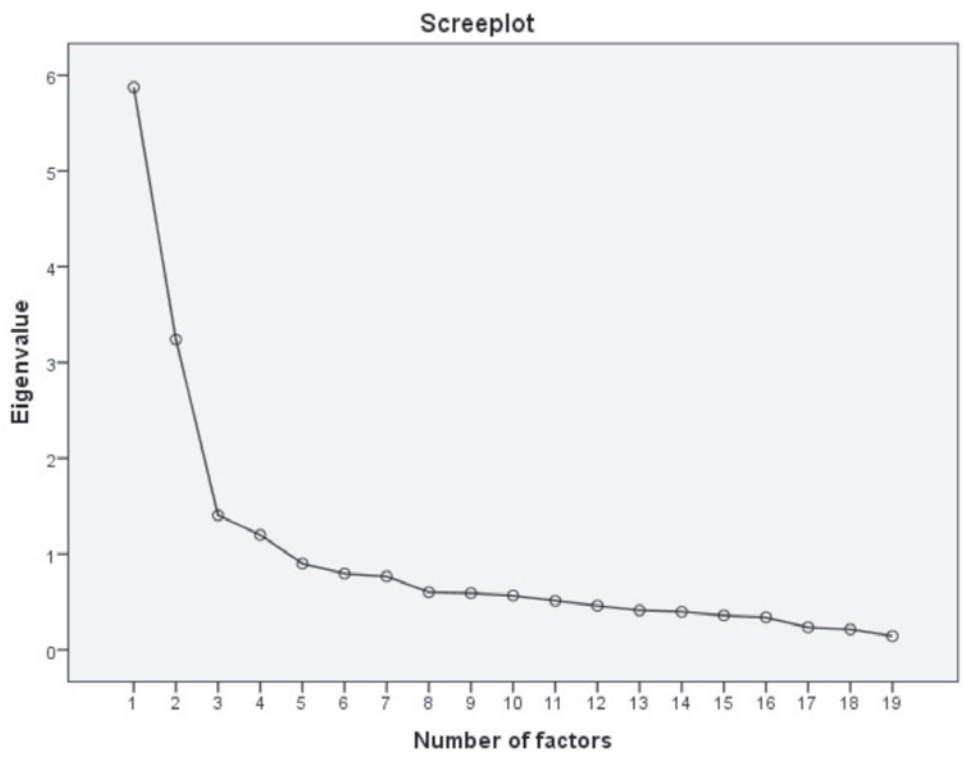

Fig. 1. Scree-Plot CTAQ-I.

able everyday activities even if the tinnitus is present (item 8: "There are many activities I do when I experience tinnitus"). Other items assess the performing life's demands regardless of the perceived tinnitus level (item 1: "I am getting on with the business of living no matter what my level of tinnitus is"). The factor "tinnitus willingness" includes questions addressing the attempt to gain control over the perception of tinnitus itself (item 13: "Keeping my tinnitus level under control takes first priority whenever I am doing something"; item 14: "Before I can make any serious plan I have to get some control over my tinnitus"). Item 4 ("I would gladly sacrifice important things in my life to control this tinnitus better") depicted the extent to which some patients feel defeated by their tinnitus and how much they value even partial personal influence. Other questions that influence this factor capture attitudes and behaviours, such as the avoidance of situations where, from the patient's point of view, tinnitus may be worsening (item 17: "I avoid putting myself in situations where tinnitus might increase"), or the experienced need of controlling tinnitus related thoughts and emotions. The items of the factor "tinnitus willingness" clarify the central importance of overcoming tinnitus for many patients, and how much they align or change their behaviour accordingly.

Our results support McCracken et al.'s [32] construction of acceptance as involving both the giving up of the struggle to control tinnitus and pursuing normal life activities despite tinnitus. Nevertheless, the relationship between acceptance and control strategies requires further study [20], as well as the potential benefits of control strategies and avoidance-based coping, by distinguishing between short- and long-term effects.

In our study the total score of the CTAQ-I as well as both subscales ("activity engagement" and "tinnitus willingness") showed good internal consistencies, which were comparable to the CTAQ-G [29]. Items 3 and 7 slightly lowered the internal consistency of the respective subscale. However, their exclusion would only result in mild improvement and the two items are profound parts of the theoretical concept of acceptance. Item 7 also showed the lowest item-total correlation of all items. In the previous validation of the German CTAQ-G item 7 showed an acceptable item-total correlation ($r = 0.44$) [29], while no specific details were presented in the English validation (Moreland 2009, unpublished thesis). We therefore decided to keep both items in the questionnaire. Nevertheless, further research should critically review these items in larger international samples.

Construct validity was analysed by comparing the CTAQ-I with measures of tinnitus distress, psychological distress and

Table III. Results of the factor analysis (pattern matrix).

		Factor	
		Activity engagement	Tinnitus willingness
1.	I am getting on with the business of living no matter what my level of tinnitus is	0.68	0.02
2.	My life is going well, even though I have chronic tinnitus	0.76	0.32
3.	It's OK to experience ear noise	0.29	0.18
4.	I would gladly sacrifice important things in my life to control this tinnitus better*	0.01	0.56
5.	It's not necessary for me to control my ear noise in order to handle my life well	0.55	0.15
6.	Although things have changed, I am living a normal life despite my chronic tinnitus	0.79	0.26
7.	I need to concentrate on getting rid of my tinnitus*	-0.35	0.25
8.	There are many activities I do when I experience tinnitus	0.81	0.18
9.	I lead a full life even though I have tinnitus	0.89	0.07
10.	Controlling tinnitus is less important than other goals in my life	0.59	0.21
11.	My thoughts and feelings about tinnitus must change before I can take important steps in my life*	0.03	0.44
12.	Despite the tinnitus, I am now sticking to a certain course in my life	0.63	0.11
13.	Keeping my tinnitus level under control takes first priority whenever I am doing something*	0.18	0.72
14.	Before I can make any serious plans, I have to get some control over my tinnitus*	0.25	0.73
15.	When my tinnitus increases, I can still take care of my responsibilities	0.51	-0.01
16.	I will have better control over my life if I can control my negative thoughts about tinnitus*	-0.08	0.51
17.	I avoid putting myself in situations where tinnitus might increase*	0.25	0.54
18.	My worries and fears about what tinnitus will do to me are true*	0.28	0.67
19.	It's a relief to realise that I don't have to change my tinnitus to get on with my life	0.57	0.09
20.	I have to struggle to do things when I have tinnitus*	0.27	0.61

Extraction Method: maximum likelihood; Rotation Method: oblimin with Kaiser normalisation; bold values indicate which factor the item was assigned to; inversed item scores.*

Table IV. Correlations between CTAQ-I, TQ 12-I, THI, BSI, and SF-36.

	CTAQ-I total Score	CTAQ-I activity engagement	CTAQ-I tinnitus willingness
TQ 12-I total score	-0.49***	-0.38***	-0.36***
TQ 12-I health anxiety	-0.41***	-0.32***	-0.30***
TQ 12-I cognitive distress	-0.41***	-0.32***	-0.31***
THI total score	-0.67***	-0.53***	-0.50***
THI functional subscale	-0.60***	-0.47***	-0.45***
THI emotional subscale	-0.66***	-0.53***	-0.47***
THI catastrophic subscale	-0.59***	-0.44***	-0.47***
BSI - Global Severity Index	-0.44***	-0.36***	-0.32***
SF-36 - physical health summary	0.15	0.22**	-0.01
SF-36 - mental health summary	0.51***	0.44***	0.35***

** $p < 0.05$, ** $p < 0.01$, *** $p < 0.001$, two-tailed.*

quality of life. Increased tinnitus acceptance was associated with less tinnitus distress and less psychological distress, which is in line with previous studies on tinnitus acceptance [16 20 22 37].

Furthermore, as indicated by previous research on tinnitus acceptance [22 37], higher levels of tinnitus acceptance were also related to an increased quality of life. While in our study emotional well-being was significantly correlated to the total score as well as both subscales, physical well-being seemed to be related only to activity engagement. This was not unexpected since the subscale 'activity engagement' includes a more physical aspect of acceptance, while tinnitus willingness may be understood as a more cognitive approach.

In our sample, the level of acceptance was neither correlated with gender or age, as also reported by Westin, Hayes [19]. Acceptance was negatively correlated with the subjective loudness of tinnitus, which is strongly related to the amount of tinnitus distress itself [38]. In a recent study, tinnitus acceptance fully mediated the relationship between the subjective tinnitus loudness and tinnitus distress, even when controlling for baseline depression and anxiety [20]. These results clearly indicate the role tinnitus acceptance may play in the understanding of subjective tinnitus distress.

We found no significant correlations between subjective hearing problems and tinnitus acceptance. As expected, patients with hyperacusis showed lower acceptance scores than patients without hyperacusis. This may be a fairly important finding, since hyperacusis is highly prevalent among patients with chronic tinnitus [39], and is strongly related to tinnitus distress [40], as well as to subjective tinnitus loudness and related comorbidities [41]. For clinical counselling, it might be highly relevant to assess the grade of acceptance or experiential avoidance, as symptom-related anxiety and protracted avoidance behaviour resulting from tinnitus and hyperacusis can both lead to disabling situations.

As shown in previous tinnitus studies [42], the process of acceptance may also be influenced in treatments, which do not include specific acceptance-oriented methods (e.g. tinnitus counselling, Tinnitus Retraining Therapy (TRT) or elements of psychoeducation). Future tinnitus research should therefore focus on the conceptualisation of acceptance and experiential avoidance to increase the understanding of which factors may boost tinnitus acceptance within different types of treatments. The appraisal of tinnitus as a harmless – albeit disturbing – experience, may pave the way to acceptance of ear noise. The sensory experience of tinnitus cannot be separated from the emotional experience, and involves the senses, emotions, thoughts, actions and behaviours. Tinnitus patients with a pronounced state of suffering have not only to accept the tinnitus, but also come to terms with the tinnitus-associated cognitions and emotions, which play an important role in the acceptance of tinnitus. Patients may benefit from developing greater acceptance of thoughts and feelings associated with tinnitus [18].

To capture such a wide concept as acceptance in future tinnitus research, it might be worth considering a combination of measures that reflect relevant features of acceptance, experiential avoidance and related variables. In addition to cognitive variables such as catastrophising, the inclusion of personality traits [43] and tinnitus-related emotions may deepen our understanding of how patients cope with distressing tinnitus [6]. We assume that tinnitus-associated prolonged anger, shame as well as self-blame [11], or the assignment of guilt to others, can also impair the development of an accepting attitude.

The CTAQ-I may be used as an assessment tool to evaluate the extent to which patients are able to adopt an accepting attitude towards tinnitus. Investigation of these aspects are worthwhile for better understanding helpful processes in tinnitus counselling, and is of practical use for further development of psychological therapies as well as for daily

clinical work for all the various disciplines involved in tinnitus treatment.

Limitations

There are some potential sources of bias. The data was self-reported, collected as part of routine clinical work. Since our sample is a population from clinical practice, we can cautiously assume generalisability for outpatients. The sample consists exclusively of patients with chronic tinnitus; the significance of the results found is therefore limited for acute patients. The investigation has a cross-sectional design, so that any statements about cause-effect relationships or about factors influencing acceptance are not possible. We are not able to investigate the relationship between tinnitus acceptance and audiological data, since only self-report questionnaires were used. Future work is needed to clarify this aspect, as well as to investigate the test-retest reliability of the CTAQ-I.

Conclusions

In contemporary theories on how patients adapt to chronic diseases, acceptance is emerging as a valuable concept. Tinnitus acceptance is considered to be an important source of therapeutic change in behavioural-based treatments as well as in professional counselling for tinnitus. Further research is needed to highlight the importance of acceptance for adjusting to a life with chronic tinnitus and to deeper examine the clinical implications for the treatment of tinnitus. Our results show that the CTAQ-I is a reliable and valid instrument to measure the acceptance of patients suffering from chronic tinnitus. The CTAQ-I can also be adopted as an evaluation instrument for therapy research with tinnitus patients.

Acknowledgements

We thank COST Action BM1306 “TINNET - better understanding the heterogeneity of tinnitus to improve and develop new treatments” for supporting this study with a Short Term Scientific Mission to the Tinnitus Center in Rome, Italy. We thank Ryan Lundstrom for proofreading and language editing.

Conflict of interest statement

None declared.

References

1 Gopinath B, McMahon CM, Rochtchina E, et al. *Incidence, persistence and progression of tinnitus symptoms in older adults: the Blue Mountains Hearing Study*. Ear Hear 2010;31:407-12.

2 McCormack A, Edmondson-Jones M, Fortnum H, et al. *The prevalence of tinnitus and the relationship with neuroticism in a middle-aged UK population*. J Psychosom Res 2014;76:56-60.

3 Milerová J, Anders M, Dvořák T, et al. *The influence of psychological factors on tinnitus severity*. Gen Hosp Psychiatry 2013;35:412-6.

4 Cronlein T, Langguth B, Pregler M, et al. *Insomnia in patients with chronic tinnitus: cognitive and emotional distress as moderator variables*. J Psychosom Res 2016;83:65-8.

5 Bartels H, Middel BL, van der Laan BF, et al. *The additive effect of co-occurring anxiety and depression on health status, quality of life and coping strategies in help-seeking tinnitus sufferers*. Ear Hear 2008;29:947-56.

6 Cima RF, Crombez G, Vlaeyen JW. *Catastrophizing and fear of tinnitus predict quality of life in patients with chronic tinnitus*. Ear Hear 2011;32:634-41.

7 Weidt S, Delsignore A, Meyer M, et al. *Which tinnitus-related characteristics affect current health-related quality of life and depression? A cross-sectional cohort study*. Psychiatry Res 2016;237:114-21.

8 Henry JA, Meikle MB. *Psychoacoustic measures of tinnitus*. J Am Acad Audiol 2000;11:138-55.

9 Ooms E, Vanheule S, Meganck R, et al. *Tinnitus severity and its association with cognitive and somatic anxiety: a critical study*. Eur Arch Otorhinolaryngol 2012;269:2327-33.

10 Durai M, Searchfield G. *Anxiety and depression, personality traits relevant to tinnitus: a scoping review*. Int J Audiol 2016;55:605-15.

11 Trevis KJ, McLachlan NM, Wilson SJ. *Psychological mediators of chronic tinnitus: the critical role of depression*. J Affect Disord 2016;204:234-40.

12 Ziai K, Moshtaghi O, Mahboubi H, et al. *Tinnitus patients suffering from anxiety and depression: a review*. Int Tinnitus J 2017;21:68-73.

13 Mazurek B, Szczepek AJ, Brüggemann P. *Tinnitus - clinical symptoms and therapy*. Laryngorhinootologie 2017;96:47-59.

14 Martinez-Devesa P, Perera R, Theodoulou M, et al. *Cognitive behavioural therapy for tinnitus*. Cochrane Database Syst Rev 2010:CD005233.

15 Hesser H, Weise C, Westin V, et al. *A systematic review and meta-analysis of randomized controlled trials of cognitive-behavioral therapy for tinnitus distress*. Clin Psychol Rev 2011;31:545-53.

16 Westin V, Schulin M, Hesser H, et al. *Acceptance and commitment therapy versus Tinnitus Retraining Therapy in the treatment of tinnitus: a randomised controlled trial*. Behav Res Ther 2011;49:737-47.

17 Philippot P, Nef F, Clauw L, et al. *A randomized controlled trial of mindfulness-based cognitive therapy for treating tinnitus*. Clin Psychol Psychother 2012;19:411-9.

18 McKenna L, Marks EM, Vogt F. *Mindfulness-based cognitive therapy for chronic Tinnitus: evaluation of benefits in a large sample of patients attending a Tinnitus clinic*. Ear Hear 2018;39:359-66.

19 Westin V, Hayes SC, Andersson G. *Is it the sound or your relationship to it? The role of acceptance in predicting tinnitus impact*. Behav Res Ther 2008;46:1259-65.

20 Hesser H, Bånkestad E, Andersson G. *Acceptance of Tinnitus as an independent correlate of Tinnitus severity*. Ear Hear 2015;36:e176-e82.

21 Moring J, Bowen A, Thomas J, et al. *Acceptance mediates the relationship between Tinnitus-related cognitions and anxiety sensitivity*. Am J Audiol 2015;24:235-42.

22 Hesser H, Gustafsson T, Lundén C, et al. *A randomized controlled trial of internet-delivered cognitive behavior therapy and acceptance and commitment therapy in the treatment of tinnitus*. J Consult Clin Psychol 2012;80:649-61.

[23] Brandtstädter J, Renner G. *Tenacious goal pursuit and flexible goal adjustment: explication and age-related analysis of assimilative and accommodative strategies of coping*. Psychol Aging 1990;5:58-67.

[24] Kleinstäuber M, Jasper K, Schweda I, et al. *The role of fear-avoidance cognitions and behaviors in patients with chronic tinnitus*. Cogn Behav Ther 2013;42:84-99.

[25] McKenna L, Irwin R. *Sound therapy for tinnitus - sacred cow or idol worship? An investigation of the evidence*. Audiol Med 2008;6:16-24.

[26] Dauman N, Erlandsson SI, Albarracin D, et al. *Exploring tinnitus-induced disablement by persistent frustration in aging individuals: A grounded theory study*. Front Aging Neurosci 2017;9:272.

[27] Andersson G, Westin V. *Understanding tinnitus distress: introducing the concepts of moderators and mediators*. Int J Audiol 2008;47(Suppl 2):S106-S11.

[28] Hesser H, Andersson G. *The role of anxiety sensitivity and behavioral avoidance in tinnitus disability*. Int J Audiol 2009;48:295-9.

[29] Riedl D, Rumpold G, Schmidt A, et al. *[Acceptance of tinnitus: Validation of the 'Akzeptanzfragebogen bei chronischem Tinnitus' (AFCT)] German*. Laryngo- Rhino- Otologie 2014;93:840-7.

[30] Langguth B, Goodey R, Azevedo A, et al. *Consensus for tinnitus patient assessment and treatment outcome measurement: Tinnitus Research Initiative meeting, Regensburg, July 2006*. Prog Brain Res 2007;166:525-36.

[31] Bernini O, Pennato T, Cosci F, et al. *The psychometric properties of the chronic pain acceptance questionnaire in Italian patients with chronic pain*. J Health Psychol 2010;15:1236-45.

[32] McCracken LM, Vowles KE, Eccleston C. *Acceptance of chronic pain: component analysis and a revised assessment method*. Pain 2004;107:159-66.

[33] Passi S, Ralli G, Capparelli E, et al. *The THI questionnaire: psychometric data for reliability and validity of the Italian version*. Int Tinnitus J 2008;14:26-33.

[34] Moschen R, Fioretti A, Eibenstein A, et al. *Validation of the Italian Tinnitus Questionnaire Short Form (TQ 12-I) as a Brief Test for the Assessment of Tinnitus-Related Distress: Results of a Cross-Sectional Multicenter-Study*. Front Psycho 2018;9:65

[35] De Leo D, Frisoni GB, Rozzini R, et al. *Italian community norms for the Brief Symptom Inventory in the elderly*. Br J Clin Psychol 1993;32 (Pt 2):209-13.

[36] Apolone G, Mosconi P. *The Italian SF-36 Health Survey: translation, validation and norming*. J Clin Epidemiol 1998;51:1025-36.

[37] Riedl D, Rumpold G, Schmidt A, et al. *The influence of tinnitus acceptance on the quality of life and psychological distress in patients with chronic tinnitus*. Noise Health 2015;17:374-81.

[38] Hoekstra CEL, Wesdorp FM, van Zanten GA. *Socio-demographic, health, and tinnitus related variables affecting tinnitus severity*. Ear Hear 2014;35:544-54.

[39] Landgrebe M, Zeman F, Koller M, et al. *The Tinnitus Research Initiative (TRI) database: a new approach for delineation of tinnitus subtypes and generation of predictors for treatment outcome*. BMC Med Inform Decis Mak 2010;10:42.

[40] Schecklmann M, Lehner A, Schlee W, et al. *Validation of screening questions for hyperacusis in chronic tinnitus*. Biomed Res Int 2015;2015:191479.

[41] Kojima T, Kanzaki S, Oishi N, et al. *Clinical characteristics of patients with tinnitus evaluated with the Tinnitus Sample Case History Questionnaire in Japan: a case series*. Plos One 2017;12:e0180609-e.

[42] Westin V, Östergren R, Andersson G. *The effects of acceptance versus thought suppression for dealing with the intrusiveness of tinnitus*. Int J Audiol 2008;47:112-8.

[43] Kleinstauber M, Weise C, Andersson G, et al. *Personality traits predict and moderate the outcome of Internet-based cognitive behavioural therapy for chronic tinnitus*. Int J Audiol 2018;57:538-44.

Received: March 8, 2018 - Accepted: September 4, 2018

How to cite this article: Moschen R, Fioretti A, Eibenstein A, et al. *Validation of the Chronic Tinnitus Acceptance Questionnaire (CTAQ-I): the Italian version*. Acta Otorhinolaryngol Ital 2019;39:107-116. https://doi.org/10.14639/0392-100X-2144

Address for correspondence: David Riedl, University Clinic of Medical Psychology, Medical University of Innsbruck, Speckbacherstraße 23/3, 6020 Innsbruck, Austria. Tel. +43 512 504-26 231. Fax +43 512 504-26 232. E-mail: david.riedl@tirol-kliniken.at

ACTA OTORHINOLARYNGOLOGICA ITALICA 2019;39:117-121; doi: 10.14639/0392-100X-2408 OPEN ACCESS

Maxillo facial and plastic surgery

Use of a CAD-CAM inferior alveolar nerve salvage template during mandibular resection for benign lesions

Utilizzo di una guida CAD-CAM per la preservazione del nervo alveolare inferiore durante le resezioni mandibolari nelle lesioni benigne

F. RICOTTA[1], S. BATTAGLIA[1], A. SANDI[2], A. PIZZIGALLO[1], C. MARCHETTI[1], A. TARSITANO[1]

[1] Maxillofacial Surgery Unit, Head and Neck Department, S. Orsola-Malpighi Hospital, Department of Biomedical and Neuromotor Sciences, Alma Mater Studiorum University of Bologna, Bologna, Italy; [2] Sintac Biomedical Engineering, Trento, Italy

SUMMARY

During surgical procedures involving the mandible, preserving the inferior alveolar nerve (IAN) may be preferable for benign tumours. In this prospective pilot study, we report our experience on the use of a Rapid Inferior Alveolar nerve Customised Salvage (RICS) template. Virtual surgical planning (VSP) of the template is based on a 3D model obtained from the elaboration of DICOM files of the preoperative CT scan. Five patients affected by benign mandibular pathology were included. A total of 7 IANs were exteriorised. The average time of exteriorisation was 23 minutes. All exteriorisations were performed successfully and no damage to the neuro-vascular bundle occurred. All patients showed complete recovery of sensitivity of the IAN within 7 weeks after surgical procedure. In conclusion, RICS template seems to allow faster and safer exteriorisation of the IAN.

KEY WORDS: Mandibular resection • Inferior alveolar nerve • Nerve exteriorisation • Computer-assisted surgery

RIASSUNTO

Durante le procedure chirurgiche di resezione mandibolare, la preservazione del nervo alveolare inferiore (NAI) è auspicabile nella patologia benigna. In questo studio pilota prospettico, riportiamo la nostra esperienza nell'uso di una dima di taglio customizzata per la rapida preservazione del nervo alveolare inferiore (RICS). La pianificazione chirurgica virtuale della guida di taglio è basata sul modello 3D ottenuto dall'elaborazione dei file DICOM della TC pre-operatoria. Sono stati inclusi nel nostro studio 5 pazienti affetti da patologia mandibolare benigna. Sono stati esteriorizzati in totale 7 NAI. Il tempo medio di esteriorizzazione è stato 23 minuti. Tutte le esteriorizzazioni sono state eseguite con successo e non è avvenuto alcun danneggiamento del fascio neuro-vascolare. Tutti i pazienti hanno mostrato il recupero completo della sensibilità del NAI entro 7 settimane dall'intervento chirurgico. In conclusione, la dima di esteriorizzazione RICS sembrerebbe permettere una più rapida e sicura preservazione del NAI.

PAROLE CHIAVE: *Resezione mandibolare • Nervo alveolare inferiore • Esteriorizzazione del nervo • Chirurgia computer-assistita*

Introduction

Inferior alveolar nerve (IAN) damage occurs often in patients with mandibular traumas, neoplasms, or iatrogenic injuries [1 2]; it is followed by hypoaesthesia, paraesthesia and hyperaesthesia in the area innervated by the nerve (the inferior lip and chin) [3].

In particular, in locally-advanced or relapsed lesions involving the mandible, although the nerve is not directly involved by the disease, it is often sacrificed when segmental mandibular resection is performed.

In order to preserve the IAN, nerve exteriorisation can be executed. The surgical steps are as follows:

- exposure of the mental nerve;
- starting from the mental foramen, a saw or rotating burr is used to perform osteoplasty of the outer cortex of the lower jaw, proceeding as distal as necessary from the mental foramen;
- Exteriorisation of the IAN using a blunt instrument (a free periosteal elevator).

These steps require great care as the surgeon can damage the nerve during exteriorisation [1].

Performing the surgical procedure as previously described, there is a considerable risk of iatrogenic nerve injury [4]. With the advent of computer-assisted surgery

© Società Italiana di Otorinolaringoiatria e Chirurgia Cervico-Facciale

(CAS), virtual surgical planning and CAD/CAM-fabrication of exteriorisation templated becomes possible.
The aim of this pilot study was to investigate if the use of CAD/CAM-fabricated exteriorisation templates is feasible and can contribute to reduce operation time and the incidence of nerve damage.

Materials and methods

The present study is a prospective single-centre pilot study. The study was approved by the S. Orsola Hospital Ethics Committee (approval no. 57/2011/O/Disp). Between November 2016 and January 2018, 5 patients affected by locally advanced or relapsed benign diseases, for a total of 7 IAN exteriorisations, were included. The inclusion criteria were:

- benign locally advanced lesion involving the mandible with need for segmental resection. (the indications to perform mandibular segmental resection are reported for each case in Table I);
- preoperative CT scan imaging;
- clinical and radiological signs of IAN integrity;
- absence of extra-mandibular vestibular extension.

Exclusion criteria were:

- malignancies of the mandible;
- clinical and radiological signs of IAN involvement;
- extra-mandibular vestibular extension.

All surgical and reconstructive procedures were virtually planned and performed according to our CAD-CAM protocol[5].
Virtual planning began with the acquisition of a high-resolution CT-scan of the craniofacial region and of the lower leg or ankle as a donor site. Digital Imaging and Communications in Medicine (DICOM) format data were processed using the simulation software. Using this software, it is possible to create 3D virtual models of the maxillofacial skeleton and donor site. The software allows the surgeon to plan mandibular and flap osteotomies.
Mandibular cutting guides were used to reproduce the osteotomy site, as virtually planned. Reconstructive plates were manufactured by a direct metal laser sintering method: a metal powder was fused into a solid component and melted locally using a focused laser beam. The solid-to-layer files of the guide and plate were then manufactured by direct metal laser sintering (SINTAC s.r.l., Biomedical Engineering, Trento, Italy) using an EOSINT M270 system (Electro-Optical Systems, GmbH, Munich, Germany).

Protocol for RICS computer-assisted design and manufacturing

DICOM files were processed using MIMICS software (Materialise, Leuven, Belgium) to obtain 3D virtual models, and the surgeons then engaged in virtual surgical planning (VSP). Cutting guides and Rapid Inferior alveolar nerve Customised Salvage (RICS) templates were designed using 3MATIC software (Materialise). The RICS template featured appropriate threshold of the IAN path in the mandibular canal (Fig. 1). The exteriorisation guide was planned based on the projection of the nerve on the outer surface of the mandible. All templates featured at least two stabilisation flanges. The virtual planning files were verified using MAGICS software (Materialise). The STL files of the cutting guides and the RICS template were additively printed

Table I. Characteristics of patients enrolled and pathologies for the test group; Indications to segmental mandibular resection; Time of sensory recovery and time of nerve exteriorisation using the RICS template.

Patient (sex)	Pathology	Indication to segmental resection	Side	Defect type	Free flap	Age	Time (minutes)	Sensory recovery time (weeks)
I (F)	Ameloblastoma	Second local relapse\extra-cortical lingual extension	Right	Body	Iliac crest	31	25	7
II (M)	Desmoplastic Fibroma	Extra-cortical lingual extension	Left	Body	Fibula	9	19	5
III (F)	Osteomyelitis	Relapse after conservative surgery	Right; Left	Ramus, Body, Symphysis, Body	Fibula	25	26; 20	4+6
IV (M)	BRONJ	Stage III according to AAOMS classification	Right; Left	Body, Symphysis, Body	Fibula	55	30; 22	5+7
V (F)	Osteomyelitis	Second relapse after conservative surgery	Left	Body	Fibula	24	20	1

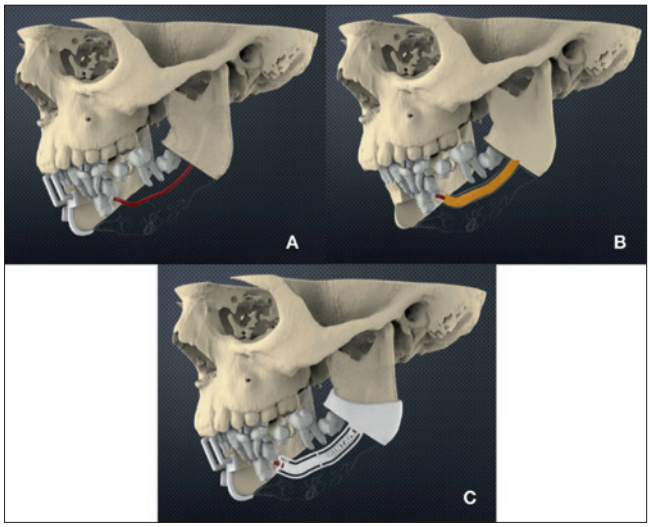

Fig. 1. Virtual planning of the RICS template for exteriorisation of the IAN. A: Appropriate thresholding to visualise the path of the IAN. B: Outlining of the IAN on the outer cortex of the mandibular canal. C: Design of the RICS template.

using the SLS FORMIGA P110 system (Electro-Optical Systems GmbH, Krailling, Germany) by SINTAC s.r.l., Biomedical Engineering (Trento, Italy).

Surgical procedure

The procedure featured the creation of a surgical access and the exposure of the mandible to an extent permitting template positioning. The mental foramen and its nerve were identified, and the RICS template was positioned (Fig. 2). Osteoplasty of the outer mandibular cortex then continued, following the guide to attain the bone marrow. Commencement of bleeding indicated that the depth at which osteotomy of the outer cortex should proceed, with exposure of the nerve canal, had been attained. Osteoplasty was usually performed with the aid of a piezoelectric saw (Piezosurgery, Mectron Spa, Carasco, Italy). When the osteotomy lines were traced, it was possible to finalise the procedure after template removal, which created more space for the saw. After osteoplasty was complete, we removed the outlined mandibular cortex and exposed the IAN along its entire path (Fig. 3). The IAN was completely removed from its canal via blunt dissection, taking care not to pull, compress, or strain the nerve to avoid ischaemic/iatrogenic damage. When exteriorisation was complete, safe mandibular resection proceeded as planned (Fig. 4).

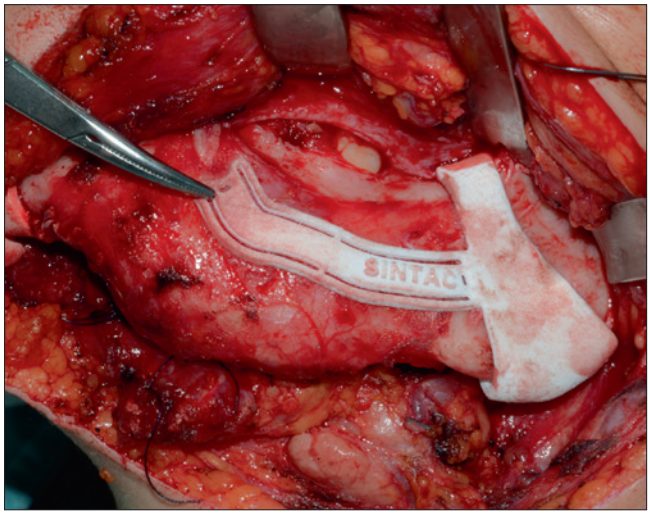

Fig. 2. Intra-operative positioning of the RICS template.

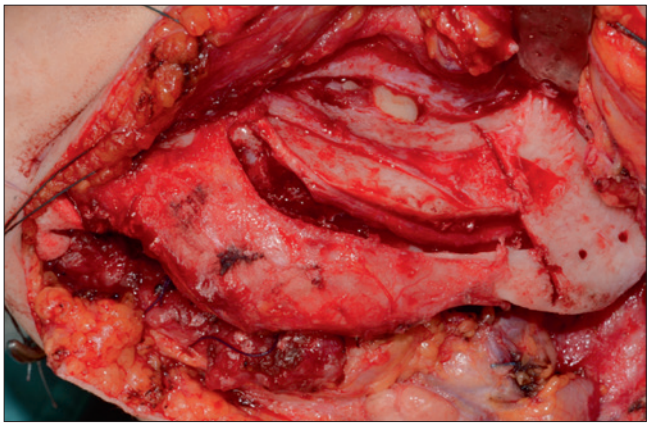

Fig. 3. The outer cortex of the mandible is removed. Complete visualisation and exteriorisation of the IAN.

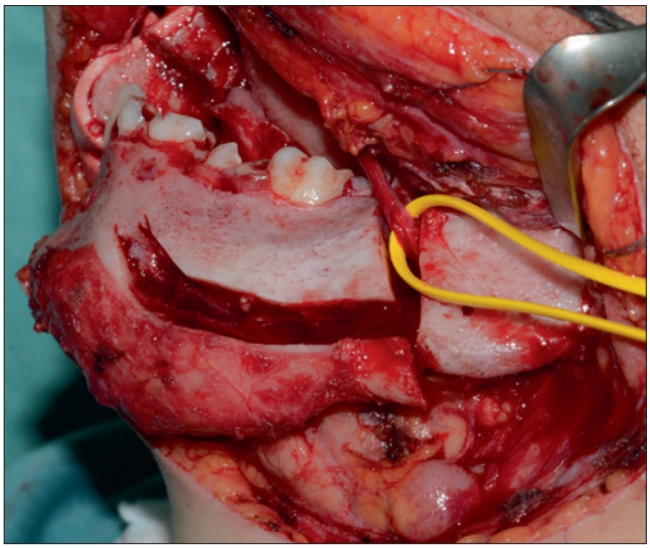

Fig. 4. The mandibular resection is performed with preservation of the IAN (yellow loop), as preoperatively planned.

Outcome evaluation

The exteriorisation time was recorded for each nerve, intended as from the positioning of the RICS template to the completion of the IAN exteriorisation from its canal.

Feasibility of the procedure was evaluated as the correspondence between VSP-related positioning of the RICS template and its real intra-operative reproducibility.

Success of the surgical procedure was considered as nerve bundle preservation.

The sensitivity status of each enrolled patient was clinically assessed.

The "two point discrimination test" [6 7] was performed after surgical procedure, as follows:

- Post-op - Day #1
- Post-op - Week #1
- Post-op - Week #3
- Post-op - Week #5
- Post-op - Week #7

Results obtained were registered on the patient's medical records.

A historical control group constituted of 5 patients (six IANs), treated without template, was considered to compare clinical outcomes.

Results

Seven IANs were exteriorised (two patients required bilateral exteriorisation) for the test group. The procedures were performed by three surgeons differing in age and experience.

All treated patients, but one, presented trophic alveolar bone (Cawood and Howell class I-II) [8] and were potentially eligible for implant-supported dental rehabilitation. One patient had class IV according to Cawood and Howell classification [8].

All patients underwent bony free flap reconstruction. Four patients had a fibula free flap; One patient had an iliac crest free flap (Table I).

In all cases treated, we found good correspondence between VSP and intra-operative positioning of the RICS template. Osteoplasty was successfully performed according to the template, allowing us to expose the IAN. All exteriorisations were successful, and the neuro-vascular bundle was not damaged.

The average exteriorisation time was 23 min (range 19-30 min) for the test group and 38 (range 29-48 min) min for the control group. In the immediate post-operative period, all patients exhibited hypoaesthesia, paraesthesia, or anaesthesia of the territory innervated by the IAN, as assessed using "two-point discrimination".

All patients treated using the RICS template exhibited complete recovery of IAN sensitivity within 7 weeks of surgery. The average recovery time was 5 weeks (range 1-7 weeks). Otherwise, the average recovery time was 8 weeks (range 6-10 weeks) for the control group.

The mean cost registered for each RICS template was 400 euro.

Discussion

The IAN exteriorisation an established procedure for the salvage of the mandibular neuro-vascular bundle.

Many reports have confirmed the utility of the procedure, especially during dental rehabilitation. Two exteriorisation techniques have been described: inferior alveolar nerve transposition (IANT) [9] and inferior alveolar nerve lateralisation (LIAN) [10].

In our experience, IAN exteriorisation is valuable, especially in those with benign pathologies that do not involve the mandibular canal. In such cases, when segmental mandibular resection is indicated for relapsed lesions or locally advanced disease, nerve salvage is possible, albeit associated with a longer operative time, allowing recovery of IAN sensitivity.

Traditional exteriorisation proceeds after evaluation of diagnostic images, either 2D OPG or 3D CT. The surgeon checks the position of the nerve and then performs outer cortical osteotomy. This places the nerve at risk. Therefore, a piezoelectric saw, which reduces the risk of bundle lesion, is generally employed at this stage [11 12]. However, during mandibular resection, the risk is particularly high because a full-thickness bone osteotomy is required.

In this pilot study, we propose a customised template to evaluate the feasibility of this kind of tool.

The use of patient-specific cutting guides during mandibular resection to treat benign pathologies and malignancies improves outcomes and reconstruction accuracy [13 14]. Huang described a mandibular cutting guide used to salvage the IAN in six patients with benign pathologies [15].

The guide was planned by reference to the inferior border of the mandibular canal; an osteotomy line was placed only on that border. Moreover, only one large cutting guide was used for both resection and nerve exteriorisation. Our RICS template is a dedicated exteriorisation guide and is thus distinct from the resection cutting guide. The RICS template is small and can be positioned via a minimal surgical access. Moreover, the template is a two-track guide outlining both the superior and inferior borders of the mandibular canal, allowing more precise osteotomy. Nerve exteriorisation is rapid, precise and delicate. All cases exhibited rapid recovery of sensitivity.

The mean cost for each RICS template was 400 euro. We

consider this cost adequate in relation to sparing of surgical time and improvement in terms of clinical outcomes. Finally, our pilot study showed that use of the RICS template provided adequate reproducibility. Although three surgeons differing in age and experience performed the procedure, the results (exteriorisation time and time to recovery of sensitivity) were similar.

Conclusions

In conclusion, we believe that the RICS template allows faster and safer exteriorisation of the IAN. Moreover, the use of a template renders the procedure reproducible and the time to recovery of sensation short. These preliminary results suggest that, although more studies and larger case series are needed to properly evaluate the feasibility of the technique, our template seems to be a good starting point for the fabrication of such devices.

Conflict of interest statement

None declared.

References

1. Mozsary PG, Syers CS. *Microsurgical correction of the injured inferior alveolar nerve.* J Oral Maxillofac Surg 1985;43:353-8.
2. Upton LG, Rajvanakarn M, Hayward JR. *Evaluation of the regenerative capacity of the inferior alveolar nerve following surgical trauma*. J Oral Maxillofac Surg 1987;45:212-6.
3. Sandstedt P, Sorensen S. *Neurosensory disturbances of the trigeminal nerve: a long-term follow-up of traumatic injuries*. J Oral Maxillofac Surg 1995;53:498-505.
4. Nocini PF, De Santis D, Fracasso E, et al. *Clinical and electrophysiological assessment of inferior alveolar nerve function after lateral nerve transposition.* Clin Oral Implants Res 1999;10:120-30.
5. Tarsitano A, Del Corso G, Ciocca L, et al. *Mandibular reconstructions using computer-aided design/computer-aided manufacturing: A systematic review of a defect-based reconstructive algorithm.* J Craniomaxillofac Surg 2015;43:1785-91.
6. Hirsch JM and Branemark PI. *Fixture stability and nerve function after transposition and lateralization of the inferior alveolar nerve and fixture installation.* Br J Oral Maxillofac Surg 1995;33:276-81.
7. Khajehahmadi S, Rahpeyma A, Bidar M, et al. *Vitality of intact teeth anterior to the mental foramen after inferior alveolar nerve repositioning: nerve transpositioning versus nerve lateralization.* Int J Oral Maxillofac Surg 2013;42:107-8.
8. Cawood JI, Howell RA. *A classification of the edentulous jaws.* Int J Oral Maxillofac Surg 1988;17:232-6.
9. Peleg M, Mazor Z, Chaushu G, et al. *Lateralization of the inferior alveolar nerve with simultaneous implant placement: a modified technique*. Int J Oral Maxillofac Implants 2002;17:101-6.
10. Friberg B, Ivanoff CJ, Lekholm U. *Inferior alveolar nerve transposition in combination with Brånemark implant treatment.* Int J Periodontics Restorative Dent 1992;12:440-9.
11. Proussaefs P. *Vertical alveolar ridge augmentation prior to inferior alveolar nerve repositioning: a patient report.* Int J Oral Maxillofac Implants 2005;20:296-301.
12. Bovi M, Manni A, Mavriqi L, et al. *The use of piezosurgery to mobilize the mandibular alveolar nerve followed immediately by implant insertion: a case series evaluating neurosensory disturbance.* Int J Periodontics Restorative Dent 2010;30:73-81.
13. Tarsitano A, Mazzoni S, Cipriani R, et al. *The CAD-CAM technique for mandibular reconstruction: an 18 patients oncological case-series.* J Craniomaxillofac Surg 2014;42:1460-4.
14. Tarsitano A, Ciocca L, Cipriani R. *Mandibular reconstruction using fibula free flap harvested using a customised cutting guide: how we do it.* Acta Otorhinolaryngol Ital 2015;35:198-201.
15. Huang D, Chen M, He D, et al. *Preservation of the inferior alveolar neurovascular bundle in the osteotomy of benign lesions of the mandible using a digital template.* Br J Oral Maxillofac Surg 2015;53:637-41.

Received: November 5, 2018 - Accepted: November 27, 2018

How to cite this article: Ricotta F, Battaglia S, Sandi A, et al. *Use of a CAD-CAM inferior alveolar nerve salvage template during mandibular resection for benign lesions.* Acta Otorhinolaryngol Ital 2019;39:117-121. https://doi.org/10.14639/0392-100X-2408

Address for correspondence: Achille Tarsitano, Maxillofacial Surgery Unit, S. Orsola-Malpighi Hospital, Department of Biomedical and Neuromotor Sciences, Alma Mater Studiorum University of Bologna, via G. Massarenti 9, 40100 Bologna, Italy. Tel. +39 051 2144205. E-mail: achille.tarsitano2@unibo.it

 OPEN ACCESS

OTOLOGY

Canal wall down approach for tympano-mastoid cholesteatoma: long-term results and prognostic factors

La timpanoplastica aperta per il trattamento dei colesteatomi timpanomastoidei: risultati a lungo termine e fattori prognostici

R. PARESCHI, D. LEPERA, R. NUCCI
Department of Otorhinolaryngology, Ospedale Nuovo di Legnano, Milan, Italy

SUMMARY

The aim of this study is to analyse the long-term anatomical and functional outcomes and prognostic factors of the canal wall down (CWD) tympanoplasty for the treatment of tympano-mastoid cholesteatoma. A total of 895 patients treated for tympano-mastoid cholesteatoma with follow-up longer than 10 years were included. Recidivism (recurrent and residual) cholesteatoma rates and functional results were analysed. The rate of recidivism was 7.7% (6.7% persistence and 1% recurrent disease). Recidivism was higher in paediatric patients (10.1% versus 5.0% of adults). Pathological middle ear mucosa and pars tensa was associated with increased rates of recidivism. Postoperatively, air pure-tone-average (aPTA) ≤ 30 dB was achieved in 36.4% of patients. Of 895 patients, a revision CWD tympanoplasty for chronic otorrhoea was performed in 14 cases (1.5%) with complete recovery in all cases. Nine of those patients had a recurrence of cholesteatoma and five had cavity problems related to granulation, de-epithelisation or recurrent infection. Paediatric patients and absence of stapes superstructure were associated with the worst auditory outcomes. Six-month results were always better than long-term results. A CWD approach was demonstrated to be effective, achieving the goals of cholesteatoma treatment.

KEY WORDS: Cholesteatoma • Chronic otitis media (COM) • Canal Wall Down (CWD) • Open mastoid cavity

RIASSUNTO

Lo scopo di questo studio è di analizzare i risultati anatomici e funzionali e i fattori prognostici a lungo termine della timpanoplastica aperta per il trattamento del colesteatoma timpano-mastoideo. Sono stati inclusi 895 pazienti consecutivi con un follow up superiore a 10 anni. Il tasso di recidiva complessivo è risultato 7,7% (6,7% di persistenza e 1% di malattia ricorrente). Il tasso di recidiva è stato più elevato nei pazienti pediatrici (10,1% rispetto al 5,0% degli adulti). La presenza di mucosa dell'orecchio medio patologica e le alterazioni della pars tensa della membrana timpanica sono state correlate con un aumento dei tassi di recidiva. Al follow up a lungo termine, nel 36,4% dei pazienti è stata ottenuta una "pure tone average" sulla via aerea (aPTA) ≤ 30 dB e i risultati a sei mesi erano sempre migliori dei risultati a lungo termine. L'età pediatrica e l'assenza della sovrastruttura della staffa sono stati associati ad un peggioramento dei risultati uditivi. Una timpanoplastica aperta di revisione per otorrea cronica è stata eseguita in 14 pazienti (1,5%) con un recupero completo in tutti i casi. Nove di questi pazienti erano affetti da recidiva di colesteatoma mentre cinque pazienti hanno avuto problemi di cavità correlati a granulazioni, disepitelizzazione o infezione ricorrente. La tecnica aperta per il trattamento del colesteatoma timpano-mastoideo si è dimostrata essere efficace, raggiungendo gli obiettivi del trattamento del colesteatoma che includono l'asportazione del colesteatoma con un basso tasso di recidiva in termini sia del colesteatoma residuo che ricorrente, preservare o recuperare l'udito e creare un orecchio asciutto.

PAROLE CHIAVE: *Colesteatoma • Otite media cronica • Timpanoplastica aperta • Mastoidectomia aperta*

Introduction

Cholesteatoma is a mass in the tympanic cavity and/or mastoid cavity, formed by keratinising squamous epithelium, subepithelial connective tissue and the progressive accumulation of keratin debris with or without a surrounding inflammatory reaction [1]. Surgery is the treatment of choice and its objectives are the complete removal of the disease, creation of a safe, dry, and disease-free ear, and preservation or restoration of hearing as far as possible [2]. The surgical approaches are classically divided into open approaches (or canal wall down - CWD) and closed approaches (or canal wall up – CWU) [3 4]. There has been a lengthy debate on the merits of the CWU versus CWD technique as is the optimal surgical strategy [5].

The aim of this study is to analyse the long-term anatomical and functional outcomes of CWD tympanoplasty

 © Società Italiana di Otorinolaringoiatria e Chirurgia Cervico-Facciale

for treatment of tympano-mastoid cholesteatoma in 895 patients with follow-up between 10 and 24 years, and to evaluate the prognostic factors that influence outcomes.

Materials and methods

The present study is a retrospective evaluation of patients treated for tympano-mastoid cholesteatoma at the Otorhinolaryngology Department of the Ospedale di Legnano (Milano, Italy) between January 1992 and March 2016. Patients with incomplete medical records and less than 10 years of follow-up were excluded. Patients with residual or recurrent cholesteatoma previously treated elsewhere were excluded. The presence and extent of the cholesteatoma and status of the tympanic membrane were assessed preoperatively by otomicroscopy and/or otoendoscopy, with radiological examinations (CT scan without enhancement), and a pure-tone and speech audiometry within 3 months before scheduled surgery. Patients affected by tympano-mastoid cholesteatoma were treated only with a CWD tympanoplasty, which was performed by the same surgeon (R.P.) with the same technique, thus avoiding selection biases.

After surgery, the patients were evaluated by otomicroscopy and audiometric examinations at the 1st, 6th and 12th month in the first postoperative year and then every 1 or 2 years.

The incidence of recidivism, residual and recurrent cholesteatoma was obtained. The anatomical recidivism rate was evaluated according to the extent of cholesteatoma (with or without involvement of the tympanic cavity). Patients were divided into two groups according to the condition of the pars tensa and middle ear mucosa. Group A included patients with normal or slightly inflammatory middle ear mucosa, and normal or slightly retracted pars tensa. Group B included patients with hyperplastic polypoid, and/or keratinizing middle ear mucosa and perforated part tensa or with severe atelectasis. The anatomical results in terms of rates of recidivism, persistent and recurrent cholesteatoma were obtained and compared between the two groups.

The functional results were evaluated with the pure-tone average air conduction thresholds (aPTA) at 500, 1000, 2000 and 4000 Hz after 6 months and more than 10 years. Patients with postoperative aPTA ≤ 30 dB-HL were considered to have serviceable hearing with no need for hearing aids. The variables evaluated were: length of follow-up, clinical condition of the middle ear mucosa and pars tensa (group A and B as previously described) and the presence of the stapes superstructure. Functional and anatomical results were also evaluated according to the age (< 18 years; ≥ 18 years).

All data were collected and processed using a commercially available software package (SPSS for Windows, version 19, 2010; SPSS, Chicago, IL, USA). Statistical analysis used Chi-squared or Fisher's tests (p values < 0.05 were considered statistically significant).

Surgical technique

Local or general anaesthesia was used according to the general status and preferences of patients. The temporalis fascia was harvested as grafting material using a postauricular skin incision 1 cm behind the postauricular sulcus. The anteriorly based postauricular periosteal flap was elevated, until the mastoid process was adequately exposed. The posterior skin of the external auditory canal (EAC) was progressively detached from the bone, from 6 to 12 o'clock, proceeding medially until the fibrous annulus was exposed and detached. The posterior skin of the EAC was elevated intact and, if possible, in continuity with the annulus and the pars tensa. The posterior mesotympanum was exposed. A CWD mastoidectomy was performed (Fig. 1). The cavity was always saucerised, the posterior wall of the EAC was lowered and the bony overhangs were removed in order to obtain a round-shaped cavity. The mastoid tip was usually preserved (Fig. 2). Accordingly, it was not necessary to expose the mastoid tract of the facial nerve apart from in the case of invasive cholesteatoma of the posterior mesotympanum, with deep erosion of the tympanic sinus. The matrix of the cholesteatoma located in the mastoid was completely removed (Fig. 3) unless a lateral semicircular canal fistula

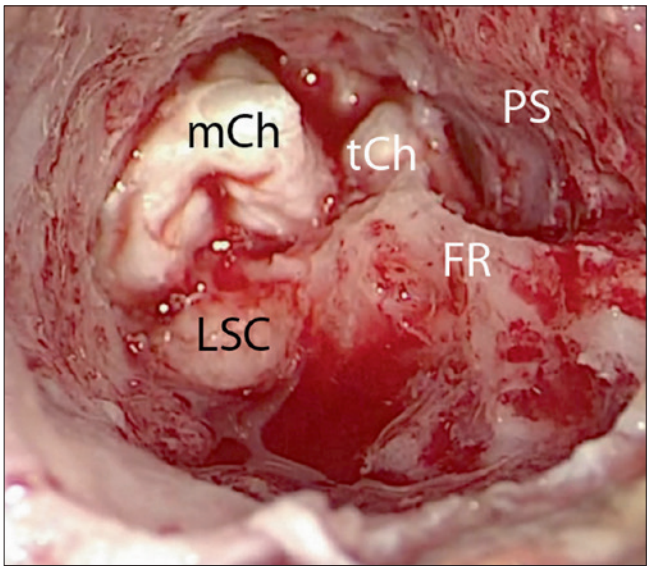

Fig. 1. A canal wall down (CWD) mastoidectomy. The lateral semicircular canal is evident (LSC) and a large amount of bone has been preserved over the mastoid segment of the facial nerve, the so-called facial ridge (FR). The cholesteatoma extends into the mastoid (mCh) and into the tympanic cavity (tCh). The skin of the postero-supero-inferior walls of the external auditory canal (PS) has been preserved.

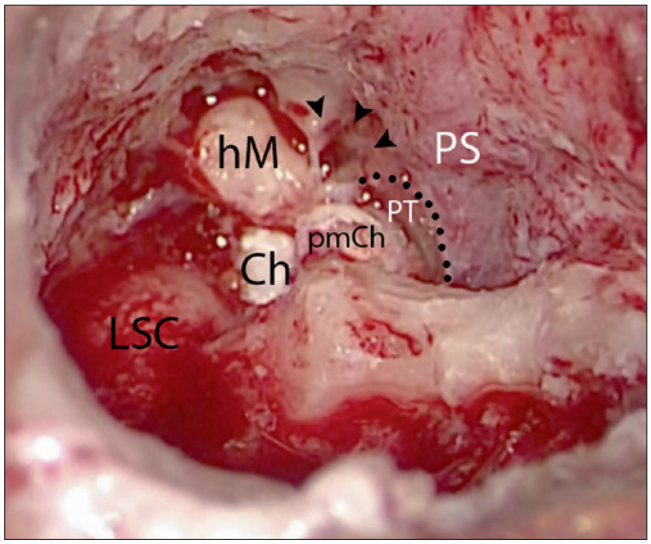

Fig. 2. Picture after the removal of the mastoid part of the cholesteatoma. The incus was completely eroded and the head of the mallus (hM) was present into the epitympanum. The cholesteatoma (Ch) extends medially to the ossicular chain and moves downward into the posterior mesotympanus (pmCh), thus eroding the stapes and infiltrating the posterior recesses. The pars tensa (PT) and the fibrous annulus (black dotted line) have been preserved and were not involved by the cholesteatoma; the lateral semicircular canal (LSC) is indicated.

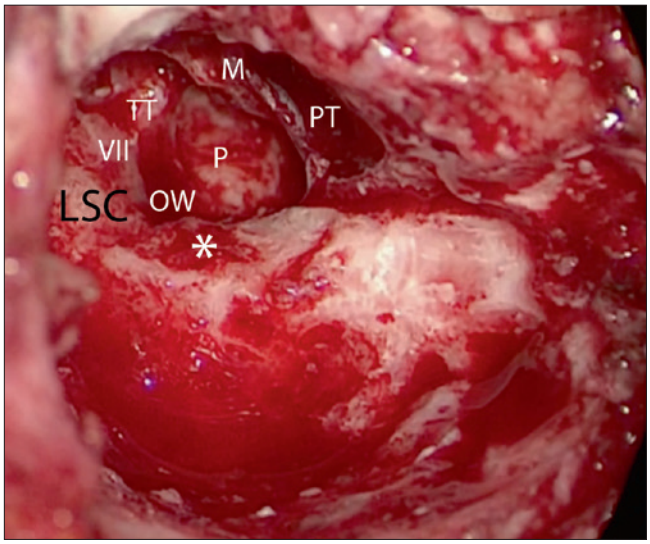

Fig. 3. The cavity after the complete removal of the cholesteatoma. After the facial ridge has been drilled (*) also the posterior mesotympanic recesses have been cleaned. The oval window (OW) is explored and the superstructure of the stapes has been eroded by the cholesteatoma. The tympanic part of the facial nerve (VII), the lateral semicircular canal (LSC), the pars tensa (PT), the handle of the malleus (M) and the tensor tympani (TT) are indicated.

was evident. In this case, the matrix was removed only if the endostium of the canal is preserved; contrariwise a layer of matrix was preserved to protect the labyrinth. A complete atticotomy was performed. The incus and the head of the malleus were removed in order to completely expose the anterior and medial epitympanum. The tendon of the malleus was sharply cut to lateralise and preserve the pars tensa of the tympanic membrane and to explore the anterior mesotympanum. The ossicular chain was left intact in rare cases where the cholesteatoma was located only in the lateral epitympanum. At the end of the procedure, the result was a round cavity with the entire tympano-mastoid compartments well exteriorised and well evident postoperatively. The cavity was mostly covered with an enlarged pedicled tympano-meatal skin flap. This flap, formed by the superior-posterior-inferior skin of the EAC, was mobilised through two incisions: a transversal incision at the level of the concha from 6 o'clock to 12 o'clock and a second longitudinal incision at 12 o'clock from the previous incision as far as the remaining pars tensa (Figs. 4, 5). The thick and vascularised tympano-meatal skin flap was positioned over the cavity to promote healing and reduce the volume of the cavity. Thus, it prevented tissue granulation and otorrhoea, and accumulation of debris.

A meatoplasty was performed in all cases.

The perforations of the pars tensa were reconstructed preferably with the temporalis fascia underlay technique. The ossiculoplasty was performed with the remodeled autologous incus or with an alloplastic prosthesis if the incus was eroded.

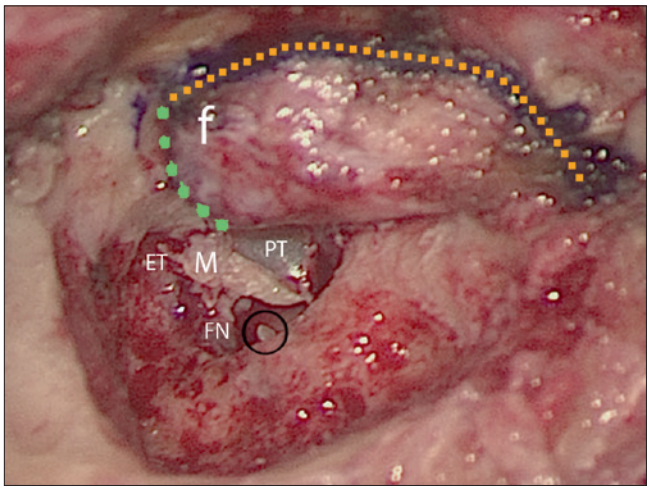

Fig. 4. The cavity after the complete removal of the cholesteatoma. The pars tensa (PT) has been removed in its posterior part. The epitympanum (ET) has been exposed after the resection of the incus and the head of the malleus. The flap (f), composed by the postero-supero-inferior skin of the external auditory canal, will be harvested with two incisions: a transversal incision (orange small-dotted line) at the level of the concha from 6 o'clock to 12 o'clock and a second longitudinal incision at 12 o'clock from the previous incision until the remaining pars tensa (green big-dotted line). The stapes super structure was intact (black circle) FN: facial nerve; M: malleus.

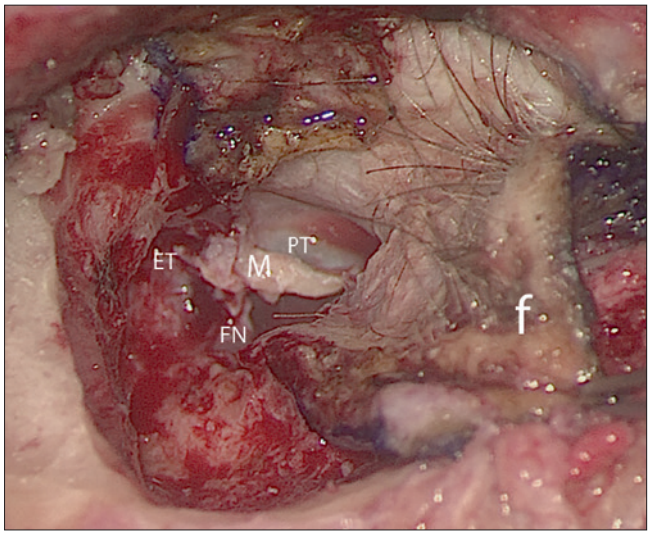

Fig. 5. The tympano-meatal pedicled skin flap (f) is harvested and positioned to cover the cavity. M: malleus, ET: epitimpanum, PT: part tensa, FN: facial nerve.

Results

Between January 1992 and March 2016, 1445 patients were treated for tympano-mastoid cholesteatoma at the Otolaryngology Department of the Ospedale di Legnano (Milan, Italy). According to the inclusion criteria, 895 patients were enrolled in this survey.

All of the patients were treated with CWD mastoidectomy. Single stage surgery was performed in 673 patients (75.2%), whereas two-stage surgery was performed in 222 cases (24.8%). There were no major complications such as facial nerve palsy, central nervous system complication (fistula, infection, or haemorrhage), or cophosis. Of 895 patients, a revision CWD tympanoplasty for chronic otorrhea was performed in 14 cases (1.5%) with a complete recovery in all cases. Nine of those patients had a recurrence of cholesteatoma and five had cavity problems related to granulation, de-epithelisation, or recurrent infection.

In total, 591 patients had a normal or slightly pathological middle ear mucosa and pars tensa and were included in group A, while 304 patients were classified into group B. In group A, 225 patients (38.1%) were adult and 366 (61.9%) were paediatric whereas in group B, there were 207 (68.1%) adult and 97 (31.9%) paediatric patients.

Recidivism of disease was reported in 69 patients (7.7%) with between 10 and 24 years of follow-up. There was persistence of disease in 60 cases (6.7%); in 52 cases, disease was located in the posterior mesotympanum, in 5 cases in the anterior mesotympanum, and in 3 cases, in the hypotympanum. Recurrent disease occurred in 9 patients (1%). A significant difference was evident between the rates of recidivism, residual and recurrent cholesteatoma between group A (5.4%, 4.9% and 0.5%, respectively) and group B (12.2%, 10.2% and 2.0%, respectively) (Table I).

There were no significant differences in recidivism, persistence, or recurrence according to the extent of the cholesteatoma.

Recidivism was significantly lower in adults compared to paediatric patients (5% and 10.1%, respectively, $p<0.05$) and similar results were obtained for residual disease (4.6% and 8.6%, respectively, $p < 0.05$). Concerning recurrences, a difference between adult and paediatric patients was still present (0.4% and 1.5%, respectively, $p = 0.120$) that was not statistically significant. This is probably related to the low rate of recurrent disease obtained with the open approach (Table II).

Considering the long-term hearing outcomes, 36.4% of all patients had useful ear function with pure-tone average air conduction thresholds (aPTA) ≤ 30dB at 500, 1000, 2000 and 4000 Hz. Concerning group A, the stapes superstructure was present in 443 cases (75.0%) and in this subgroup, aPTA was ≤ 30 dB in 60.3% of adults and 40.2% of paediatric patients. When the stapes superstructure was absent, long-term auditory outcomes deteriorated in 43.3% of adult patients and 30.2% of paediatric patients reporting aPTA ≤ 30 dB. Postoperatively, in group A, the tympanic membrane was atelectasic in 79.5% of the children and 32.3% of the adults, which could be related to the poorer hearing results in children.

Table I. Distribution of the enrolled patients into group A and B according to age and recidivism rate (residual and recurrent cholesteatoma).

	Total	Group A	Group B	Univariate
Patients enrolled	895 (100%)	591 (66.0%)	304 (34.0%)	
Adults	432 (48.3%)	225 (38.1%)	207 (68.1%)	
Paediatrics	463 (51.7%)	366 (61.9%)	97 (38.9%)	< 0.05
Recidivism	69 (7.7%)	31 (5.4%)	37 (12.2%)	< 0.05
Residual cholesteatoma	60 (6.7%)	29 (4.9%)	31 (10.2%)	< 0.05
Recurrent cholesteatoma	9 (1.0%)	3 (0.5%)	6 (2.0%)	< 0.05

Table II. Analysis of recidivism, residual and recurrent cholesteatoma according to age.

	Total	Adult (%)	Paediatric (%)	Univariate
Recidivism	69	22/432 (5.0)	47/463 (10.1)	< 0.05
Residual cholesteatoma	60	20/432 (4.6)	40/463 (8.6)	< 0.05
Recurrent cholesteatoma	9	2/432 (0.4)	7/463 (1.5)	0.120

Group B showed impaired hearing results with 40.2% and 30.2% of patients with aPTA ≤ 30 dB when the stapes superstructure was, respectively, present or absent. The presence of the stapes superstructure was associated with a significant improvement in hearing in group A, whereas in group B the pathological condition of the mucosa of the middle ear or the pathology of the tympanic membrane was related to poorer hearing results, and the absence of the stapes superstructure was associated with poorer outcomes even though the difference was not statistically significant (Table III).

A longer follow-up was associated with worsening of hearing outcomes. Six-month results were always better than the long term results in group A. Patients in group B with the stapes also showed significant deterioration of hearing outcomes over time, whereas in patients in group B without stapes, hearing results deteriorated over time even though there were no significant differences between the 6-month and longer term results. These data are detailed in Table III.

Discussion

The canal wall up (CWU) versus the canal wall down (CWD) approach has been extensively debated during the last few decades and controversies still exist. The goal of the present paper was not to revisit this discussion, but rather to report on long-term outcomes and prognostic factors of the CWD approach for tympano-mastoid cholesteatoma in a large and homogenous cohort of patients. Regardless of the approach, the goals of cholesteatoma surgery are to: eradicate the disease reducing the rate of recidivism, preserve or restore hearing and create a dry ear. In our hands, the CWD approach is an effective approach, achieving the goals of cholesteatoma treatment, with single-stage surgery in more than 75% of cases and without contraindications.

Table III. Functional results. S+ presence of the stapes; S- absence of the stapes.

	TOT	PTA ≤ 30dB	PTA > 30dB	Univariate
Total	**895**	**326 (36.4%)**	**569 (63.6%)**	
Group A	591	246 (41.6%)	345 (58.4%)	
Group B	304	80 (26.3%)	224 (73.7%)	< 0.05
Group A				
Adults	225	118 (52.4%)	107 (47.6%)	
Paediatrics	366	128 (35.0%)	238 (65.0)	< 0.05
Adults S+	121	73 (60.3%)	48 (39.7%)	
Adults S-	104	45 (43.3%)	59 (56.7%)	< 0.05
Paediatrics S+	174	70 (40.2%)	104 (59.8%)	
Paediatrics S-	192	58 (30.2%)	134 (69.8%)	< 0.05
S+ (6 months)	295	234 (79.3%)	61 (20.7%)	
S+	295	143 (48.5%)	152 (51.5%)	< 0.05
S- (6 months)	296	163 (55.1%)	133 (44.9%)	
S-	296	103 (34.8%)	193 (65.2%)	< 0.05
GROUP B				
S+	207	61 0 (29.5%)	146 (70.5%)	
S-	97	19 (19.5%)	78 (80.5%)	.07
S+ (6 months)	207	93 (44.9%)	114 (55.1%)	< 0.05*
S- (6 months)	97	29 (29.9%)	68 (70.1%)	0.096** < 0.05***

** Comparison of the results at 6 months of follow up with the long term results in patients with the stapes in the group B. ** Comparison of the results at 6 months of follow up with the long term results in patients without the stapes in the group B. ***Comparison of the results at 6 months of follow up between patients with and without stapes in the group B.*

In this study, the recidivism rate for the CWD approach was 7.7%, which is comparable to the 2-18% reported in the literature [2 6 7]. Two different kinds of recidivism must be considered. Residual cholesteatoma is defined as non-radically removed epidermoid cells [8], whereas a recurrence is a new retraction pocket containing keratin that has evolved into a cholesteatoma [9]. The CWD approach has been demonstrated to minimise the rates of both residual and recurrent disease [10 11]. The wide exposure created by the CWD technique guarantees the complete removal of the matrix from the mastoid, the epitympanum and from the recesses of the tympanic cavity, thus reducing the rates of residual cholesteatoma. Residual cholesteatoma rates were estimated at between 0% and 7%[(8)] in a recent review. In our analysis, residual cholesteatoma was evident in 6.7% of cases and was mainly located in the posterior mesotympanum, the most common site of persistence [12]. Most of the recurrences after a CWD approach should be considered to be technical errors; their incidence is estimated in the literature at between 0 and 15% [8], and in our hands affected 1% of cases. The two principal causes of recurrence in the CWD approach are insufficient lowering of the facial ridge and inadequate meatoplasty [13]. The lowering of the facial ridge reduces the volume of the middle ear thus avoiding the creation of retraction pockets. In fact, in the case of tube dysfunction, the tympanic membrane will become atelectasic instead of creating pockets. Furthermore, a round cavity with smooth margins with adequate meatoplasty will provide a dry and self-cleaning cavity.

The CWU approach presents a recidivism rate that is 2.87 times higher, ranging between 9% and 70% [4]. It preserves both the normal anatomy of the ear canal and the normal volume of the middle ear, but is commonly accepted to have limited surgical exposure [14] thus leading to an increased rate of persistence, ranging between 3.1% and 20% [8]. Neither second surgery nor adequate follow-up are able to reduce the rate of evolving retraction pockets after a CWU approach[19 20]. These are related to the persistence of a large air-filled cavity behind the tympanic membrane and the posterior canal wall together with the intratympanic negative pressure. In such cases, the surgery proposed is usually a CWD approach, in order to avoid further failures due to recurrence of retraction pockets.

The prognostic factors for recidivism after a CWD approach are pathological condition of the tympanic membrane and middle ear mucosa, age of the patient and length of follow-up.

Extent of disease was not a prognostic factor because the open approach always gives the possibility to expose and remove the cholesteatoma from the mastoid and middle ear[(15)] and, during follow-up, to identify and remove pearls in the mastoid cavity or epitympanum; these pearls were not deemed to be persistent [16] because their removal under local anaesthesia is part of regular follow-up. Thus, the mesotympanum, and rarely the hypotympanum, are the only sites at risk for persistence, in particular, when the presence of pathological middle ear mucosa and atelectasic or perforated pars tensa makes it difficult to identify and remove the cholesteatoma completely [10 13 24]. As demonstrated by our results, group B reported more than double the rate of recidivism, recurrence and persistence than group A.

The rate of cholesteatoma recidivism in children was higher than in adults (5.0% versus 10.1%, respectively, $p < 0.05$). Most otologists have assumed that cholesteatoma in children is more aggressive than in adults and tends to form bud-like extensions into surrounding tissues making total removal of the disease difficult [15 17].

The length of follow-up is a well-recognised prognostic factor for both anatomical and functional results [15]. When reporting results after cholesteatoma surgery, an adequate follow-up period is required considering that cholesteatoma recurrences can develop even after 12 years of follow-up [18]. Consequently, in our study, a minimum of 10 years of follow-up was considered adequate for reporting definitive anatomical and functional results, and only a few papers in the literature have presented such long-term results.

Concerning functional outcomes, there are different opinions concerning the different approaches and techniques. According to several papers [19-22], the CWD approach is related to a poorer hearing outcome compared to the CWU approach because of the anatomical alteration of the external and middle ear and the increased risk of adhesion and fibrosis of the prosthesis to the promontory or to the facial nerve. On the other hand, several studies reported similar functional results between the open and closed approaches [6 10 11 23 24]. In this regard, the end point adopted and the length of follow-up dramatically influence the functional results. The most frequently used end point in the literature is the air-bone gap (ABG), but gives no information on the real hearing status. The end point we adopted was the pure-tone average air conduction threshold (aPTA) after 6 months and after more than 10 years. We considered hearing to be serviceable when the aPTA was lower than 30 dB, and the frequencies evaluated were 500 Hz, 1000 Hz, 2000 Hz and 4000 Hz in order to completely analyse the range of the speaking human voice. In particular, we included 4000 Hz because this frequency region is often damaged

by chronic otitis [25 26] and is the most challenging to recover with ossiculoplasty [27]; the choice of this end point could be related to deterioration of the results.

The other important factor is length of follow-up. The healing process takes several years and leads to a progressive deterioration of hearing, as shown by our results where 6-month functional outcomes were significantly better than the long-term results.

In our analysis, 36.4% of all patients enrolled reported an aPTA lower than 30 dB. The results in the literature are similar to the data reported in our study. Vartiainen[(17)] reported a postoperative PTA lower than 40 dB in 38.8% of patients treated with a CWD approach for cholesteatoma after 10 years, but the author does not account for the 4000 Hz region. Other authors reported a mean postoperative PTA ranging from 31.2 to 42.4 dB [2 28 29], but with a follow-up shorter than 5 years and the 4000 Hz region was not always included.

According to our data, the preoperative factors that influence the functional results are: pathological factors (mucosa of the middle ear and/or pathological condition of the pars tensa of the tympanic membrane), anatomical factors (presence of the stapes superstructure), age of patients and length of follow-up. The presence of pathological middle ear mucosa and atelectasic or perforated pars tensa was associated with a deterioration of the long-term hearing outcomes. In our analysis, 41.6% of patients in group A reported serviceable hearing, which was significantly better than the 26.3% reported in group B. Similar results are reported in the literature [2 19 20 30-32]. The role of the stapes superstructure has been widely discussed in the literature with contrasting results. Some authors pointed out the importance of the handle of the malleus [1 20 40] speculating that the stapes superstructure promotes postoperative fibrosis and adhesion leading to poorer hearing outcomes. On the other hand, several studies have reported that the presence of the stapes suprastructure is a positive predicting factor for functional outcome [33-35]. Supporting this statement, our long-term data for group A showed that adults with the stapes superstructure reported an aPTA < 30 dB in 60.3% of cases compared with 43.3% without the stapes superstructure ($p < 0.05$). Similar results were reported in group B, but without reaching a significant difference. Paediatric patients reported poorer hearing outcomes probably related to the increased rate of postoperative atelectasis of the tympanic membrane (79.5% vs 32.3% in the adults in group A). Once the tympanic membrane has become atelectasic, there is little or no chance to reconstruct an air-filled middle ear cavity. Thus, the most important factor for a serviceable hearing function in these patients is the presence of a monolateral lesion.

The major advantage of the CWU approach is the creation of a dry ear postoperatively [4 36], whereas the CWD approach has been associated with prolonged healing, debris accumulation, chronic otorrhea, water intolerance and vertigo. In the literature, the incidence of infection of the cavity and/or chronic otorrhoea is estimated to be as high as 33% [37] with the CWD approach. In the vast majority of cases, these results are probably related to technical errors such as a high facial ridge, irregular cavity, or a stenotic meatotomy since a correctly performed CWD approach has been demonstrated to achieve a dry and water tolerant ear in more than 95% of cases [9]. In agreement with this, in the present paper, otorrhoea was evident in 14 patients (1.5%). The cause of otorrhoea was a recurrence in 9 patients, whereas five patients underwent revision surgery for cavity problems (recurrent infections, granulations, or stenotic meatotomy).

Conclusions

This retrospective study on a large and uniform cohort of patients showed that the CWD approach is a cornerstone in the management of tympano-mastoid cholesteatoma. The open approach was associated with a very low rate of recidivism (7.7%) after a follow-up between 10 and 24 years. Recurrences of cholesteatoma were related to technical errors and, theoretically, should be absent if the surgery was performed strictly according to the principles of the CWD technique. Residual diseases were located in the mesotympanum and hypotympanum since the epitympanum and mastoid cavity were exteriorised by the surgical procedure and examined during regular follow-up. The prognostic factors associated with an increased rate of recidivism for the open approach were the pathological condition of the mucosa of the middle ear and the pars tensa, paediatric age and length of follow-up. The extent of the cholesteatoma was not a prognostic factor. The long-term functional results were unsatisfactory since only 36.4% of all of patients reported an aPTA ≤ 30 dB. Long-term follow-up was associated with a deterioration of hearing. The pathological condition of the mucosa of the middle ear and pars tensa was the main negative prognostic factor. The presence of stapes was associated with better functional outcomes. Paediatric patients were associated with poorer hearing, and this could be related to the increased rate of postoperative atelectasis reported in this group.

Conflict of interest statement

None declared.

References

1. Yung M, Tono T, Olszewska E, et al. *EAONO/JOS Joint Consensus Statements on the definitions, classification and staging of middle ear cholesteatoma*. J Int Adv Otol 2017;3:1-8.
2. Aslan Felek S, Islam A, Celik H, et al. *The functional and anatomical results of the canal wall down tympanoplasty in extensive cholesteatoma*. Acta Otolaryngol 2009;129:1388-94.
3. Nikolopoulos TP, Gerbesiotis P. *Surgical management of cholesteatoma: the two main options and the third way-atticotomy/limited mastoidectomy*. Int J Pediatr Otorhinolaryngol 2009;73:1222-7.
4. Tomlin J, Chang D, McCutcheon B, et al. *Surgical technique and recurrence in cholesteatoma: a meta-analysis*. Audiol Neurootol 2013;18:135-42.
5. Nyrop M, Bonding P. *Extensive cholesteatoma: long-term results of three surgical techniques*. J Laryngol Otol 1997;111:521-6.
6. Ajalloueyan M. *Experience with surgical management of cholesteatomas*. Arch Otolaryngol Head Neck Surg 2006;132:931-3.
7. Cho YS, Hong SD, Chung KW, et al. *Revision surgery for chronic otitis media: characteristics and outcomes in comparison with primary surgery*. Auris Nasus Larynx 2010;37:18-22.
8. Kerckhoffs KG, Kommer MB, van Strien TH, et al. *The disease recurrence rate after the canal wall up or canal wall down technique in adults*. Laryngoscope 2016;126:980-7.
9. Kos MI, Castrillon R, Montandon P, et al. *Anatomic and functional long-term results of canal wall-down mastoidectomy*. Ann Otol Rhinol Laryngol 2004;113:872-6.
10. Roden D, Honrubia VF, Wiet R. *Outcome of residual cholesteatoma and hearing in mastoid surgery*. J Otolaryngol 1996;25:178-81.
11. Declerck T. *Resultaten na cholesteatoomchirurgie: Een retrospectieve analyse*. Master in de Geneeskunde, Gent Universiteit (Be). 05/05/2010.
12. Smyth GD. *Cholesteatoma surgery: the influence of the canal wall*. Laryngoscope 1985;95:92-6.
13. Bhatia S, Karmarkar S, DeDonato G, et al. *Canal wall down mastoidectomy: causes of failure, pitfalls and their management*. J Laryngol Otol 1995;109:583-9.
14. Hulka GF, McElveen JT, Jr. *A randomized, blinded study of canal wall up versus canal wall down mastoidectomy determining the differences in viewing middle ear anatomy and pathology*. Am J Otol 1998;19:574-8.
15. Britze A, Moller ML, Ovesen T. *Incidence, 10-year recidivism rate and prognostic factors for cholesteatoma*. J Laryngol Otol 2017;131:319-28.
16. de Zinis LO, Tonni D, Barezzani MG. *Single-stage canal wall-down tympanoplasty: long-term results and prognostic factors*. Ann Otol Rhinol Laryngol 2010;119:304-12.
17. Vartiainen E. *Ten-year results of canal wall down mastoidectomy for acquired cholesteatoma*. Auris Nasus Larynx 2000;27:227-9.
18. Vartiainen E. *Factors associated with recurrence of cholesteatoma*. J Laryngol Otol 1995;109:590-2.
19. Albu S, Babighian G, Trabalzini F. *Prognostic factors in tympanoplasty*. Am J Otol 1998;19:136-40.
20. Dornhoffer JL, Gardner E. *Prognostic factors in ossiculoplasty: a statistical staging system*. Otol Neurotol 2001;22:299-304.
21. Schraff SA, Strasnick B. *Pediatric cholesteatoma: a retrospective review*. Int J Pediatr Otorhinolaryngol 2006;70:385-93.
22. Shirazi MA, Muzaffar K, Leonetti JP, et al. *Surgical treatment of pediatric cholesteatomas*. Laryngoscope 2006;116:1603-7.
23. Gocmen H, Kilic R, Ozdek A, et al. *Surgical treatment of cholesteatoma in children*. Int J Pediatr Otorhinolaryngol 2003;67:867-72.
24. Kim MB, Choi J, Lee JK, et al. *Hearing outcomes according to the types of mastoidectomy: a comparison between canal wall up and canal wall down mastoidectomy*. Clin Exp Otorhinolaryngol 2010;3:203-6.
25. Carrillo RJ, Yang NW, Abes GT. *Probabilities of ossicular discontinuity in chronic suppurative otitis media using pure-tone audiometry*. Otol Neurotol 2007;28:1034-7.
26. Amali A, Hosseinzadeh N, Samadi S, et al. *Sensorineural hearing loss in patients with chronic suppurative otitis media: is there a significant correlation?* Electron Physician 2017;9:3823-7.
27. Sevik Elicora S, Erdem D, Dinc AE, et al. *The effects of surgery type and different ossiculoplasty materials on the hearing results in cholesteatoma surgery*. Eur Arch Otorhinolaryngol 2017;274:773-80.
28. Umit T, Ozgur Y, Bilgehan G, et al. *Results of primary ossiculoplasty and prognostic factors in canal wall-down tympanoplasty*. J Craniofac Surg 2010;21:407-10.
29. Goyal R, Mourya A, Qureshi S, et al. *Modified radical mastoidectomy with type III tympanoplasty: revisited*. Indian J Otolaryngol Head Neck Surg 2016;68:52-5.
30. Vartiainen E, Nuutinen J. *Long-term results of surgical treatment in different cholesteatoma types*. Am J Otol 1993;14:507-11.
31. Black B. *Reporting results in ossiculoplasty*. Otol Neurotol 2003;24:534-42.
32. Silverstein H, McDaniel AB, Lichtenstein R. *A comparison of PORP, TORP, and incus homograft for ossicular reconstruction in chronic ear surgery*. Laryngoscope 1986;96:159-65.
33. Bared A, Angeli SI. *Malleus handle: determinant of success in ossiculoplasty*. Am J Otolaryngol 2010;31:235-40.
34. Mardassi A, Deveze A, Sanjuan M, et al. *Titanium ossicular chain replacement prostheses: prognostic factors and preliminary functional results*. Eur Ann Otorhinolaryngol Head Neck Dis 2011;128:53-8.
35. Wilson KF, Hoggan RN, Shelton C. *Tympanoplasty with intact canal wall mastoidectomy for cholesteatoma: long-term surgical outcomes*. Otolaryngol Head Neck Surg 2013;149:292-5.
36. Dodson EE, Hashisaki GT, Hobgood TC, et al. *Intact canal wall mastoidectomy with tympanoplasty for cholesteatoma in children*. Laryngoscope 1998;108:977-83.
37. Goldenberg RA. *Sink-trap effect as a cause of failure in mastoidectomy*. Laryngoscope 1988;98:1143-4.

Received: June 18, 2018 - Accepted: November 19, 2018

How to cite this article: Pareschi R, Lepera D, Nucci R. *Canal wall down approach for tympano-mastoid cholesteatoma: long-term results and prognostic factors.* Acta Otorhinolaryngol Ital 2019;39:122-129. https://doi.org/10.14639/0392-100X-2237

Address for correspondence: Davide Lepera, Department of Otorhinolaryngology, Ospedale Nuovo di Legnano, via Papa Giovanni Paolo II, 20025 Milano, Italy. Tel. +39 0331 449707. E-mail: davide.lepera86@gmail.com

 OPEN ACCESS

Case series and reports

Internal carotid artery injury during endonasal sinus surgery: our experience and review of the literature

Rottura dell'arteria carotide interna durante la chirurgia nasale endoscopica: nostra esperienza e review della letteratura

S.G. LUM[1], B.S. GENDEH[1], S. HUSAIN[1], H.S. GENDEH[1], M.R. ISMAIL[2], C.J. TOH[3], A. IZAHAM[4], H.J. TAN[5]

[1] Department of Otorhinolaryngology, Head and Neck Surgery, Universiti Kebangsaan Malaysia Medical Centre (UKMMC), Kuala Lumpur, Malaysia; [2] Department of Radiology, UKMMC, Kuala Lumpur, Malaysia; [3] Neurosurgery Unit, Department of Surgery, UKMMC, Kuala Lumpur, Malaysia; [4] Department of Anaesthesiology, UKMMC, Kuala Lumpur, Malaysia; [5] Neurology Unit, Department of Medicine, UKMMC, Kuala Lumpur, Malaysia

SUMMMARY

Iatrogenic internal carotid artery injury is a catastrophic but uncommon complication of endonasal sinus surgery. We present our experience in managing this emergency situation. A 52-year-old man underwent revision endoscopic repair of recurrent cerebrospinal fluid leak that was complicated with profuse haemorrhage during removal of the anterior wall of sphenoid sinus using a Hajek sphenoid punch forceps. Immediate packing of the sphenoid sinus controlled the haemorrhage. Urgent angiography revealed injury at the paraclival segment of the left internal carotid artery. An endovascular stent was initially placed but thrombosed; it was subsequently converted to coil embolisation. The patient had watershed cerebral infarct with hemiparesis post procedure but made full recovery within 6 weeks. Immediate nasal packing followed by urgent angiography and endovascular stent placement is the least invasive definitive treatment. If stenting is unsuccessful, endovascular balloon occlusion or coil embolisation is the next preferred treatment, if there is adequate cross-cerebral circulation. The success of treatment relies on its immediate management by a multidisciplinary team.

KEY WORDS: Internal carotid artery injuries • Endoscopy sphenoid sinus • Endovascular procedures • Angiography

RIASSUNTO

La rottura iatrogena dell'arteria carotide interna è una complicanza catastrofica, sebbene non frequente, della chirurgia endoscopica nasale. In questo lavoro presentiamo la nostra esperienza nella gestione di questa emergenza. Un uomo di 52 anni è stato sottoposto ad intervento di chiusura di fistola rinoliquorale, e durante l'intervento si è verificata una copiosa emorragia durante l'apertura, mediante pinza sfenoidale di Hajek, della parete anteriore del seno sfenoidale. L'immediato tamponamento del seno sfenoidale ha controllato l'emorragia. Mediante l'esecuzione di un'angiografia urgente, è stato individuato un punto di rottura della carotide interna sinistra a livello del segmento paraclivale. Quindi inizialmente è stato posizionato uno stent, ma si è trombizzato; successivamente è stata utilizzata una spirale endovascolare. Il paziente è andato incontro ad ischemia cerebrale con emiparesi post-procedura, che si è risolta del tutto nel giro di 6 settimane. Il tamponamento nasale seguito da un'angiografia in urgenza e il posizionamento di uno stent endovascolare possono rappresentare il trattamento definitivo meno invasivo. Se lo stent non dovesse avere successo, l'occlusione mediante balloon endovascolare o l'embolizzazione mediante spirale dovrebbero essere i trattamenti di scelta quando la rivascolarizzazione dai distretti controlaterali è garantita. Il successo del trattamento si basa soprattutto sull'immediatezza della gestione da parte di un team multidisciplinare.

PAROLE CHIAVE: *Rottura dell'arteria carotide interna • Endoscopia seno sfenoidale • Procedure endovascolari • Angiografia*

Introduction

An endoscopic approach to the paranasal sinuses has become standard surgical practice compared to traditional external approaches over the past three decades. It is generally a safe procedure, but severe complications may occur. Injury to the internal carotid artery (ICA) is one of the most feared and dreadful situations faced by the otorhinolaryngologist and skull base surgeons. Internal carotid artery injury during endonasal sinus surgery (ESS) is rare with an incidence that varies from 0% to 0.1% [1]. May et al. reviewed a total of 4,691 patients and found only one case of intraoperative ICA injury [2]. Weidenbecher et al. experienced four cases of ICA injury following sphenoidectomy out of 16,000 endoscopic sinus procedures performed over 30 years period [3]. Despite the low reported incidence, the increasing prevalence of patients undergoing ESS makes understanding of the management of ICA

 © Società Italiana di Otorinolaringoiatria e Chirurgia Cervico-Facciale

injury essential for otorhinolaryngologists. In the event of occurrence of ICA injury, well-preparedness and immediate management may reduce morbidity, thus preventing mortality. Close collaboration of a multidisciplinary team comprising of otorhinolaryngologist, neurosurgeon, interventional radiologist, anaesthesiologist, ophthalmologist, neurologist and rehabilitation team is of utmost importance in the management of ICA injury. However, current literature review revealed no concise standard guidelines on the emergency management of ICA injury during ESS. We report an uncommon case of injury to paraclival segment of ICA during revision endoscopic repair of cerebrospinal fluid (CSF) leak and share our experience in its emergency management.

Case report

A 52-year-old man of Chinese ethnicity, who had endoscopic repair for right CSF fistula due to encephalocele eight years prior, presented with recurrent CSF leak on the ipsilateral side (Fig. 1) and underwent revision endoscopic repair under general anaesthesia. Leak was observed from previous site at lateral recess of right sphenoid sinus. A left Hadad's flap was raised and postero-superior septectomy was performed. While removing the anterior wall of sphenoid sinus using Hajek sphenoid punch forceps, it jerked posteriorly and impacted on the left intersinus septum that was attached to the left ICA canal, resulting in major haemorrhage. The surgical field was cleared of one litre of blood with large bore suction catheter followed by immediate packing of sphenoid sinus with ribbon gauze, which controlled the bleeding.

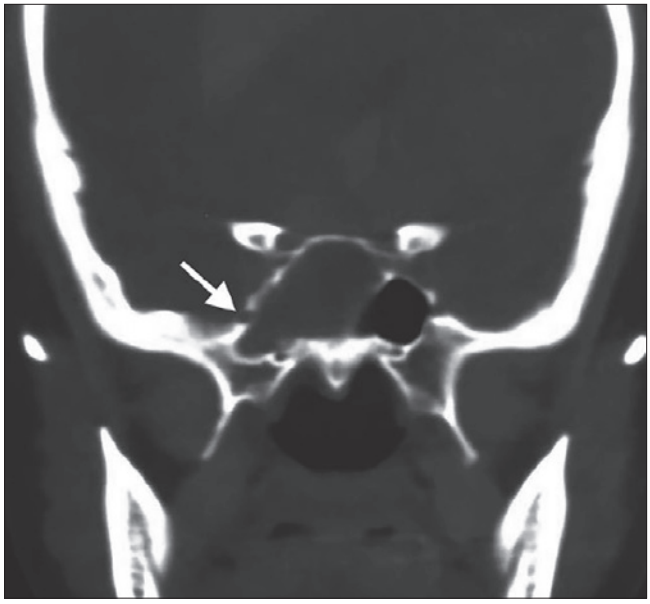

Fig. 1. Coronal CT image showing a bony defect at the lateral recess of right sphenoid sinus with soft tissue density in the right sphenoid sinus.

Upon discussion with the neurosurgeon and interventional neuroradiologist, the patient was immediately sent to the angiography suite on suspicion of ICA injury. Carotid angiography revealed injury to paraclival portion of left ICA with significant flow limitation to the left middle cerebral artery (MCA). There was no evidence of pseudo-aneurysm or carotid-cavernous fistula (Fig. 2a). Endovascular placement of a detachable stent (*Solitaire* 6 mm x 30 mm) was performed (Fig. 2b) and blood flow to left MCA improved post-stenting, but unfortunately thrombosed within 15 minutes (Fig. 2c) and was thus removed. Control run angiography showed significant bleeding from the injured segment. After multidisciplinary discussion, the decision was made to sacrifice the left ICA. Balloon occlusion test (BOT) showed satisfactory cross flow from the contralateral right ICA and vertebral arteries to left cerebral hemisphere (Fig. 2d). Twelve coils (size ranging 3-8 mm) were deployed endoscopically proximal and distal to the ICA laceration site, preserving the posterior communicating artery and ophthalmic artery. Angiography post coiling showed complete occlusion of the left ICA and leakage sealed from the injured site (Fig. 2e). There was reconstitution of the left ophthalmic arterial flow from the collateral facial artery (Fig. 2f).

Throughout the procedure, the airway was secured by endotracheal intubation. The anaesthesiologist resuscitated and closely monitored haemodynamic status to maintain optimal cerebral circulation by keeping the blood pressure normotensive with mean arterial pressure (MAP) of 60 mmHg. The systolic blood pressure postsurgery was kept between 140-160 mmHg with MAP of 90-100 mmHg to ensure adequate cerebral perfusion. Haemoglobin dropped to 11.2 g/dL post-surgery from baseline of 14.7 g/dL and two units of packed erythrocytes were transfused to replace blood loss.

Cerebral MRI 12 hours postsurgery revealed multifocal infarcts along the watershed area involving the cortical and internal border zones of anterior and middle cerebral arteries. On the second day postsurgery, right hemiparesis with expressive dysphasia was observed. He was co-managed by neurologist and commenced oral aspirin 150 mg daily. There was no visual impairment or evidence of ischaemic optic neuropathy. He underwent intensive rehabilitation and subsequently recovered with minimal residual right-sided weakness upon discharge at day 12, which completely resolved at 6 weeks follow-up. He remained asymptomatic at 15 months follow-up, with no evidence of recurrent CSF leak or epistaxis.

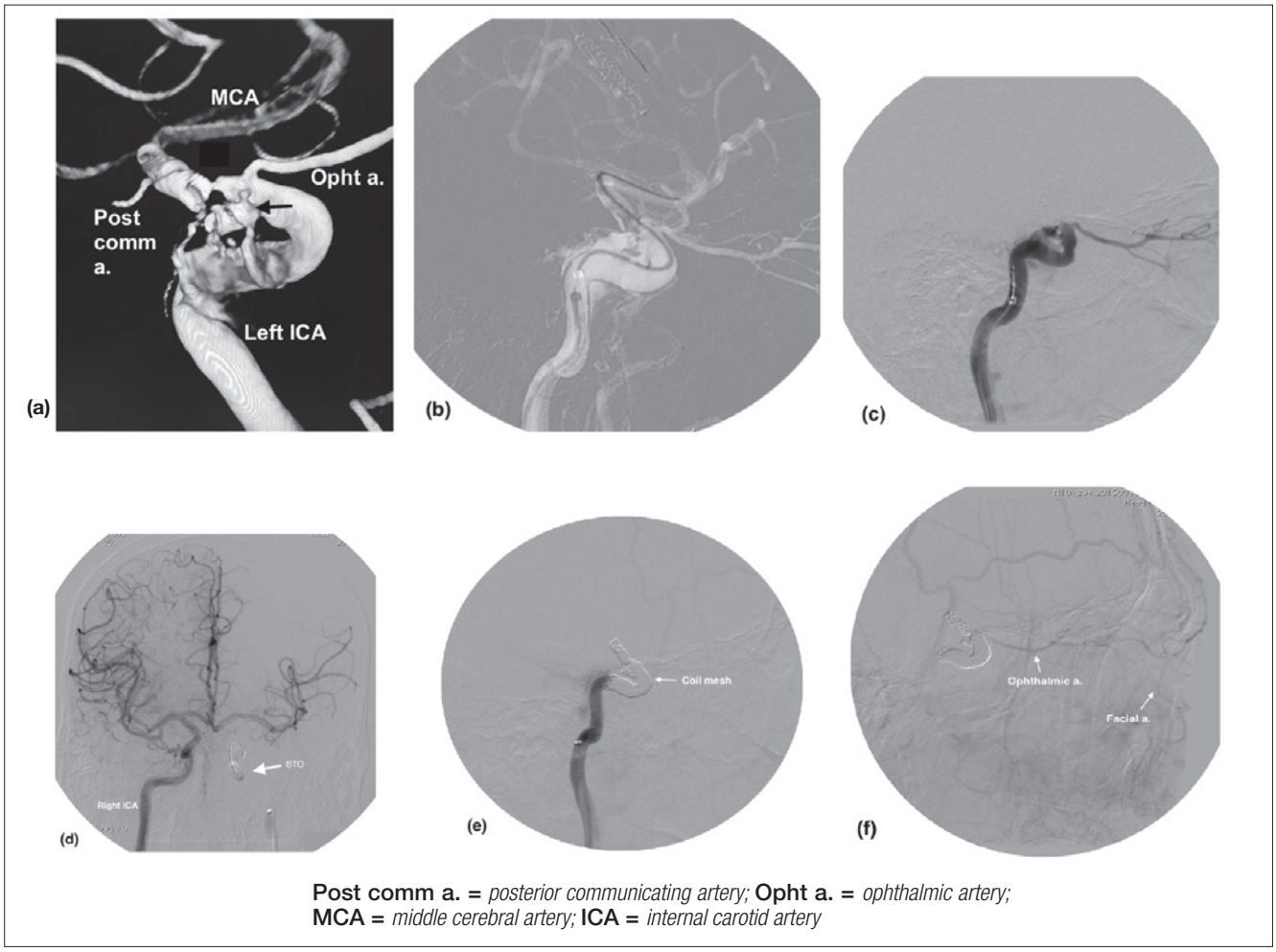

Fig. 2. a) 3D rotational angiogram reveals irregular outline at the posterior border of the left ICA (black arrow), with active extravasation of contrast media, and flow limitation to middle cerebral artery (MCA); **b)** micro-catheter crossing the injured portion of ICA before stenting; **c)** complete obliteration of the left ICA distal to the ophthalmic artery post endovascular stenting due to stent thrombosis; **d)** balloon occlusion test (BOT) of left ICA reveals satisfactory cross flow from right ICA to the left cerebral hemisphere, via anterior communicating artery and left posterior communicating artery; **e)** coil mesh in the injured portion of left ICA with complete obliteration of distal ICA. No extravasation of contrast media; **f)** reconstitution of left ophthalmic artery from facial artery collateral.

Discussion

Reported major complication rates of ESS have reduced significantly from 1.3-9.3% in 1980's to 0.3-0.9% since the early 1990's due to improvement in nasal endoscopy and introduction of powered instruments [4]. Revision ESS is often considered to have an increased risk of complications due to altered anatomy and scarring. We experienced only one case of intraoperative ICA injury out of 4,507 patients who underwent ESS at our tertiary referral centre at UKM Medical Centre, Kuala Lumpur. This is consistent with the incidence reported in the literature [2 3].

Injury to the ICA most frequently occurs during sphenoid sinus surgery, as the ICA lies directly adjacent to its lateral wall. Thus, understanding the anatomy of the ICA in relation to sphenoid sinus reduces the risk for operative complications during sphenoidotomy. Cadaveric studies discovered that 88% of the lateral sphenoid wall overlying the ICA is less than 0.5 mm thick, and dehiscent in 4-8% of cases; 71% of the ICA bulges into the sphenoid sinus, up to 4 mm from the midline in 10% of cases [5]. Some authors observed that the bony inter-sphenoidal septum inserts onto the ICA canal wall in 16.3% of occasions [6]. Grasping and twisting the intersinus septum can therefore cause forced transmission to the attachment on the carotid canal, resulting in carotid artery avulsion or development of pseudo-aneurysm. Risk is reduced if removal of inter-sphenoidal septum is done using a cutting instrument or diamond drill. In our patient, it is likely that the Hajek sphenoid punch jerked and impacted posteriorly on the

left intersinus septum (which attaches to the ipsilateral ICA canal) resulting in massive haemorrhage.

Most complications during ESS, e.g. orbital injury or CSF leak, occur more frequently on the right side. However, ICA injuries were reported more commonly on the left (ratio 1.3:1) [7]. The cavernous segment was the most commonly injured due to its anatomic proximity with the sphenoid sinus. Other factors that have been suggested to increase the likelihood of injuring the ICA during ESS include surgeon's right hand dominance, involvement of vascular structures, type of instrumentation, revision surgeries and preoperative vascular malformations.

Intra-operative ICA laceration is an emergency, with high flow and high pressure haemorrhage obscuring the surgical field, which may rapidly result in exsanguination of the patient. It is essential to be well prepared prior to the surgery to prevent delay in immediate management. The traditional method of emergency surgical ligation of carotid artery is often associated with a high incidence of complications such as death and stroke, which will also block endovascular access to the site of injury [8]. With increasing accessibility of endovascular intervention, surgical ligation should be considered as last resort to secure bleeding.

With adaptation of the protocols suggested by Pepper et al., we proposed a modified algorithm for emergency management of intraoperative ICA injury (Fig. 3) [9]. Any torrential bleeding especially during sphenoid sinus exploration should be suspected to originate from the ICA. However, controlling the high pressure haemorrhage from ICA within the confine of the nasal cavity can be extremely difficult. The first step to control the haemorrhage is adequate nasal packing. Various packing agents have been described in the literature, but gauze is the most frequently used due to its availability and ease of use [1]. In our case, the haemorrhage was successfully controlled with packing of sphenoid sinus with ribbon gauze, allowing the patient to be immediately transferred to the angiography suite for further investigation and treatment. While potentially life-saving, nasal packing can also cause harm. Packing materials should ideally be placed with just enough force to control the haemorrhage, but not to occlude vascular flow. Raymond et al. reported cases of ICA occlusion and carotid stenosis secondary to over-packing [10]. It is still controversial whether concomitant carotid artery compression is beneficial. Few authors recommended ipsilateral common carotid artery compression to reduce bleeding, but the effect is limited because of good collateralisation and contralateral compensation [8 11]. Weidenbecher et al. advocated bilateral carotid artery compression, limited to two minutes, to facilitate packing of sphenoid sinus [3].

The surgeon should work in close collaboration with the anaesthesiologist during the event of ICA injury. Where the surgeon attempts to control the intraoperative haemorrhage, the latter stabilises the patient's haemodynamic status simultaneously. The airway should be secured by endotracheal intubation if not already done. Blood grouping and cross match should be performed instantly and transfused if necessary. Lippert et al. suggested that head elevation and controlled hypotension reduces the haemorrhage, but is unnecessary given the significant hypotension that will result from massive bleeding [11]. Moreover, patients undergoing ESS are positioned in a reverse Trendelenburg and head tilt position before commencing surgery. It is now widely recommended that normo-tension be maintained through resuscitative measures to preserve adequate cerebral circulation [1].

Once the patient has been stabilised and the haemorrhage is controlled, urgent transfer to angiography suite is essential to localise the site of haemorrhage and subsequent neuro-radiological endovascular intervention. If an endovascular facility is not available, transportation to a neuro-interventional centre has to be organised immediately. It is important to recognise that arterial injury may not be apparent in early angiography due to tight nasal packing. In a case reported by Koitschev et al., the initial angiography was normal but massive epistaxis recurred four days later upon removal of nasal packing. Repeated angiography revealed ICA laceration at infra-ophthalmic segment with traumatic carotid-cavernous fistula formation [8]. Therefore, we suggest that if no vessel abnormality is identified during angiography with tight nasal packing, it should be carefully loosened followed by repeat angiography, which may enable a tamponed bleeding source to be identified.

A variety of therapeutic options are now available to the interventional radiologist to treat ICA injury, including balloon occlusion, coil embolisation and stent placement. Endovascular stenting has the advantage of closing the arterial leakage while maintaining lumen patency. However, it also has limitations as reported in two cases by Koitschev et al., in which endovascular repair with preservation of ICA were not possible due to extended laceration of the vessel wall and a direct communication to sphenoid sinus [8]. There is currently lack of international consensus on the preferred method of endovascular treatment.

Sufficient collateral arterial supply from the contralateral ICA must be confirmed by BOT if vessel occlusion is planned. Several authors have suggested that all patients should have a trial of stent placement, and only undergo embolisation if stenting fails. In the case that ICA occlu-

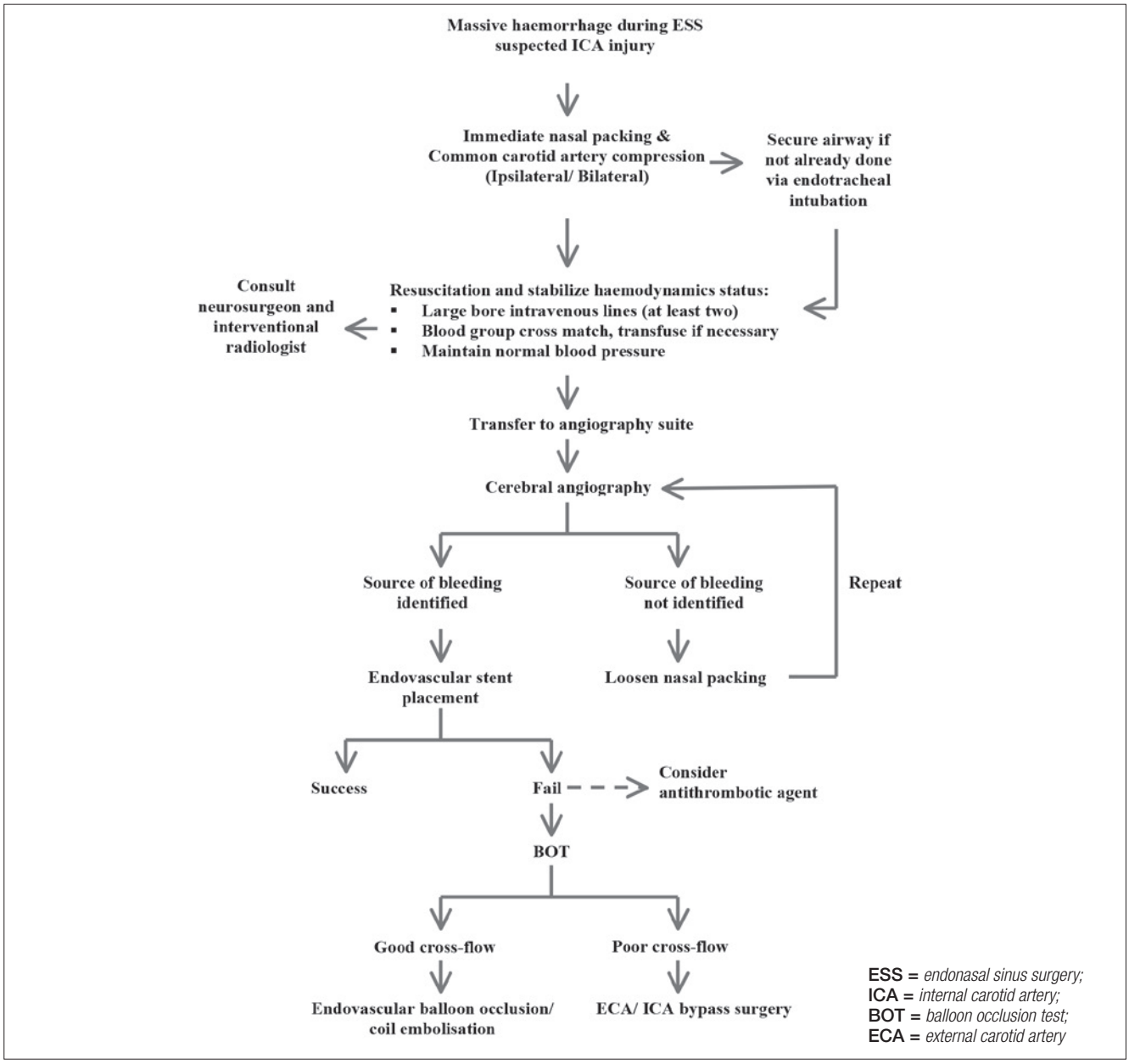

Fig. 3. Algorithm for emergency management of ICA injury during ESS.

sion is not tolerated, bypass surgery is required [12]. Other authors recommended endovascular balloon occlusion or coil embolisation as first line options in all patients with adequate collateral blood flow. However, even with a normal BOT there is still a 5-10% risk of delayed infarction after therapeutic carotid artery occlusion, 4.7% of whom developed a permanent stroke [13]. It is commonly accepted that cerebral artery bypass surgery by an external approach is associated with a high complication rate and has no longer been described in the recent literature. Our case was special in terms of a complication (ICA stent thrombosis) that occurred within another complication (ICA injury), and we eventually had to sacrifice the patency of the ICA. The patient had watershed cerebral infarct post-procedure but made full recovery following intensive rehabilitation.

Besides endovascular intervention, several authors advocated endonasal closure of the carotid defect in sphenoid sinus with the use of autologous muscle-fascia patch or allogenous dura [3 14]. Animal model studies demonstrated

that a muscle patch was effective at achieving haemostasis with ICA injuries less than 3-4 mm, but incomplete with continuous bleeding in larger lacerations [15]. According to past reports, three of four cases treated with muscle-fascia patch as first line emergency treatment were complicated with delayed pseudo-aneurysm formation, which required either a return to the operating theatre for trans-cranial clipping of pseudo-aneurysm, endovascular coiling of pseudo-aneurysm or balloon occlusion of ICA [3 16]. It must be recognised that not all injuries at the carotid arterial wall lie in direct contact with lateral sphenoid sinus wall, and a potential space may present in between. Thus, packing the sphenoid sinus may reduce the bleeding into sphenoid sinus giving a false impression to the surgeon that the haemorrhage has been controlled, but the bleeding from lacerated carotid artery may continue intra-cranially. One patient who was treated with bone wax and allegenous dura packing of sphenoid sinus died due to unrecognised subarachnoid haemorrhage with intra-ventricular extension [14].

There is risk of thromboembolic events or stent thrombosis following endovascular occlusion or stenting, and a 4.4% risk of stroke within the first 30 days following carotid stent placement has been reported [17]. Antiplatelet and anticoagulant treatment is recommended before endovascular intervention, especially stenting, but there is no international consensus on the drug regime, time to initiate and duration of therapy. The rate of thromboembolic complications decreases significantly from 20% to 1.9% if antiplatelet therapy was initiated three days prior to stenting [18]. This prophylaxis, however, may not be an ideal option in an emergency situation of ICA injury on top of a haemodynamically compromised patient. There is a report of total vessel occlusion upon ICA stent insertion, but the thrombosis was completely resolved upon administrating intravenous heparin and glycoprotein IIb/IIIa receptor antagonist [19]. Retrospectively, our patient whom had no antiplatelet therapy or heparin prior or during procedure could have his initial ICA stent salvaged upon administration of intravenous heparin and appropriate antiplatelet therapy, thus avoiding subsequent ICA coiling.

Conclusions

This case report highlights several learning points in the emergency management of ICA injury. Nasal packing with concurrent rapid resuscitation is often the first step to achieve haemostasis, followed by immediate cerebral angiography for diagnosis and treatment. Endovascular intervention is the first line definitive treatment, ideally preserving the ICA patency. Assessment of collateral cerebral blood flow must be performed and confirmed if the carotid artery is to be sacrificed. We describe a complicated case in which the endovascular stent was placed but thrombosed, and subsequently converted to coil embolisation. Post-operative care and subsequent intensive rehabilitation is important to expedite the recovery if the patient develops neurologic complications. The success of effective treatment of iatrogenic ICA injury depends on its prompt multidisciplinary management.

Acknowledgements

We thank Professor Dr. Srijit Das, from the Faculty of Medicine, University Kebangsaan Malaysia (UKM), Kuala Lumpur for his insightful suggestions and proofreading.

Conflict of interest statement

None declared.

References

1 Valentine R, Wormald PJ. *Carotid artery injury after endonasal surgery.* Otolaryngol Clin North Am 2011;44:1059-79.

2 May M, Levine HL, Mester SJ, et al. *Complications of endoscopic sinus surgery: Analysis of 2108 patients – incidence and prevention.* Laryngoscope 1994;104:1080-3.

3 Weidenbecher M, Huk WJ, Iro H. *Internal carotid artery injury during functional endoscopic sinus surgery and its management.* Eur Arch Otorhinolaryngol 2005;262:640-5.

4 Suzuki S, Yasunaga H, Matsui H, et al. *Complication rates after functional endoscopic sinus surgery: analysis of 50,734 Japanese patients.* Laryngoscope 2015;125:1785-91.

5 Fujii K, Chambers SM, Rhoton AL Jr. *Neurovascular relationships of the sphenoid sinus. A microsurgical study.* J Neurosurg 1979;50:31-9.

6 Park AH, Stankiewicz JA, Chow J, et al. *A protocol for management of a catastrophic complication of functional endoscopic sinus surgery: internal carotid artery injury.* Am J Rhinol 1998;12:153-8.

7 Chin OY, Ghosh R, Fang CH, et al. *Internal carotid artery injury in endoscopic endonasal surgery: a systemic review.* Laryngoscope 2016;126:582-90.

8 Koitschev A, Simon C, Lowenheim H, et al. *Management and outcome after internal carotid artery laceration during surgery of the paranasal sinuses.* Acta Otolaryngol 2006;126:730-8.

9 Pepper JP, Wadhwa AK, Tsai F, et al. *Cavernous carotid injury during functional endoscopic sinus surgery: case presentations and guidelines for optimal management.* Am J Rhinol 2007;21:105-9.

10 Raymond J, Hardy J, Czepko R, et al. *Arterial injuries in transsphenoidal surgery for pituitary adenoma; the role of angiography and endovascular treatment.* Am J Neuroradiol 1997;18:655-65.

11 Lippert BM, Ringel K, Stoeter P, et al. *Stentgraft-implantation for treatment of internal carotid artery injury during endonasal sinus surgery.* Am J Rhinol 2007;21:520-4.

12 Kassam A, Snyderman CH, Carrau RL, et al. *Endoneurosurgical*

hemostasis techniques: lessons learned from 400 cases. Neurosurg Focus 2005;19:E7.

13 Mathis JM, Barr JD, Jungreis CA, et al. *Temporary balloon test occlusion of the internal carotid artery: experience in 500 cases.* Am J Neuroradiol 1995;16:749-54.

14 Weber R, Draf W, Keerl R, et al. *Endonasal microendoscopic pansinus-operation in chronic sinusitis II. Results and complications.* Am J Otolaryngol 1997;18:247-53.

15 Valentine R, Wormald PJ. *Controlling the surgical field during a large endoscopic vascular injury.* Laryngoscope 2011;121:562-6.

16 Buerke B, Tombach B, Stoll W, et al. *Magnetic resonance angiography follow-up examinations to detect iatrogenic pseudoaneurysms following otorhinolaryngological surgery.* J Laryngol Otol 2007;121:698-701.

17 Wholey MH, Jarmolowski CR, Eles G, et al. *Endovascular stents for carotid artery occlusive disease.* J Endovasc Surg 1997;4:326-38.

18 Lehmann P, Saliou G, Page C, et al. *Epistaxis revealing the rupture of a carotid aneurysm of the cavernous sinus extending into the sphenoid: treatment using an uncovered stent and coils. Review of literature.* Eur Arch Otorhinolaryngol 2009;266:767-72.

19 Tong FC, Cloft HJ, Joseph GJ, et al. *Abciximab rescue in acute carotid stent thrombosis.* Am J Neuroradiol 2000;21:1750-2.

Received: July 17, 2016 - Accepted: October 5, 2017

How to cite this article: Lum SG, Gendeh BS, Husain S, et al. *Internal carotid artery injury during endonasal sinus surgery: our experience and review of the literature.* Acta Otorhinolaryngol Ital 2019;39:130-136. https://doi.org/10.14639/0392-100X-1312

Address for correspondence: Balwant Singh Gendeh, Department of Otorhinolaryngology Head and Neck Surgery, Universiti Kebangsaan Malaysia Medical Centre, Jalan Yaacob Latiff, Bandar Tun Razak, 56000 Cheras, Kuala Lumpur, Malaysia. Tel. +60 391456047. Fax +60 391456675. E-mail: bsgendeh@gmail.com

 OPEN ACCESS

Errata

ACTA OTORHINOLARYNGOLOGICA ITALICA 2018;38:409-416; doi: 10.14639/0392-100X-1507

Head and neck

Unravelling the risk factors that underlie oral and oropharyngeal surgery in elderly

Chiarire i fattori di rischio che sottendono la chirurgia del cavo orale e dell'orofaringe negli anziani

G. MOLTENI[1], S. VALERINI[1], M. ALICANDRI-CIUFELLI[1], A.E. SPRIO[2], E. CROSETTI[3], G.N. BERTA[2], L. PRESUTTI[1], G. SUCCO[3]

[1] Otorhinolaryngology Service, AOUI Verona Hospital, University of Verona, Department of Head and Neck Surgery, Verona, Italy; [2] Department of Clinical and Biological Sciences, University of Turin, Italy; [3] Head and Neck Oncology Service, Oncology Department, University of Turin, IRCCS FPO Candiolo Cancer Institute, Italy

Corrige

ACTA OTORHINOLARYNGOLOGICA ITALICA 2018;38:409-416; doi: 10.14639/0392-100X-1507

Head and neck

Unravelling the risk factors that underlie oral and oropharyngeal surgery in elderly

Chiarire i fattori di rischio che sottendono la chirurgia del cavo orale e dell'orofaringe negli anziani

G. MOLTENI[1*], S. VALERINI[1], M. ALICANDRI-CIUFELLI[1], A.E. SPRIO[2], E. CROSETTI[3], G.N. BERTA[2], L. PRESUTTI[1], G. SUCCO[3, 4]

[1] Otorhinolaryngology Service, Policlinico di Modena Hospital, University of Modena, Department of Head and Neck Surgery, Modena, Italy; [2] Department of Clinical and Biological Sciences, University of Turin, Italy; [3] Head and Neck Oncology Service, Candiolo Cancer Institute - FPO, IRCCS, Candiolo (TO), Italy; [4] Department of Oncology, University of Turin, Italy

[*] Present address: Otolaryngology Head and Neck Surgery, University Hospital of Verona, Borgo Trento, Italy; Department of Surgery, Odontostomatology and Paediatrics, University of Verona, Italy

© Società Italiana di Otorinolaringoiatria e Chirurgia Cervico-Facciale

Otorhinolaryngologica Italica

Official Journal of the Italian Society of Otorhinolaryngology Head and Neck Surgery

What's new?

Single platform

New on-line submission

New web site

www.actaitalica.it

Available on Google Scholar

Cited in Index Medicus, MEDLINE, PubMed Central, Science Citation Index Expanded, Scopus, DOAJ, Open-J Gate, Free Medical Journals, Index Copernicus, Socolar

Journal Citation Reports:
Impact Factor 1.196

Editor-in-Chief: M. Ansarin

PACINI EDITORE MEDICINA