POSTE ITALIANE SPA - Spedizione in Abbonamento Postale - D.L. 353/2003 conv. in L. 27/02/2004 n° 46 art. 1, comma 1, DCB PISA - Iscrizione al tribunale di Pisa al n. 10 del 30-07-93 - Finito di stampare presso IGP, Pisa - Dicembre 2020 - ISSN: 0392-100X (Print) - ISSN: 1827-675X (Online).

ACTA Otorhinolaryngologica Italica

Official Journal of the Italian Society of Otorhinolaryngology Head and Neck Surgery

Organo Ufficiale della Società Italiana di Otorinolaringoiatria e Chirurgia Cervico-Facciale

COVID-19

ENT surgical emergencies during the COVID-19 outbreak

Head and neck

Results of a survey on elderly head and neck cancer patients on behalf of the Italian Association of Radiotherapy and Clinical Oncology (AIRO)

Laryngology

Micronucleus, nucleoplasmic bridge and nuclear bud frequencies in patients with laryngeal carcinoma

Rhinology

Are sinonasal dissection courses a valid instrument for endoscopic sinus surgeons? A report on 7-years of experience

Effectiveness of superior eyelid endoscopic-assisted approach in the management of selected orbital abscess: considerations on 4 cases

Structural changes in the extracellular matrix after cross-linking of nasal polyp tissue

Effects of biological therapies on chronic rhinosinusitis in severe asthmatic patients

Vestibology

Evaluation of a large cohort of adult patients with Ménière's disease: bedside and clinical history

Otology

Subtotal petrosectomy and cochlear implantation

The effect of N-acetyl cysteine on biofilm layers in an experimental model of chronic otitis media

Letters to the Editor

Vertigo and hearing loss during the COVID-19 pandemic – is there an association?

Looking at the day after COVID-19… what laryngeal sequelae should we expect?

Volume 40
December 2020
6

PACINI EDITORE MEDICINA

www.actaitalica.it

ACTA Otorhinolaryngologica Italica

Official Journal of the Italian Society of Otorhinolaryngology Head and Neck Surgery

Organo Ufficiale della Società Italiana di Otorinolaringoiatria e Chirurgia Cervico-Facciale

Former Editors-in-Chief:
C. Calearo, E. de Campora, A. Staffieri, M. Piemonte, F. Chiesa, G. Paludetti

Italian Scientific Board

M. Alicandri-Ciufelli
Policlinico, Modena
G. Bellocchi
Ospedale "San Camillo", Roma
A. Bertolin
Presidio Ospedaliero, Vittorio Veneto
F. Dispenza
Policlinico "Paolo Giaccone", Palermo
M. Falcioni
Azienda Ospedaliera, Parma
F. Fiorino
Ospedale "Mater Salutis", Legnago
J. Galli
Policlinico Gemelli, Roma
G. Giourgos
Ospedale "Papa Giovanni XXIII", Bergamo
A. Greco
Policlinico "Umberto I", Roma
G. Marioni
Azienda Ospedaliera, Padova
A. Murri
Ospedale "Guglielmo Da Saliceto", Piacenza
P. Petrone
Ospedale "San Giacomo", Monopoli
C. Piazza
Istituto Nazionale dei Tumori, Milano
N.A.A. Quaranta
Policlinico, Bari
R. Teggi
Ospedale "San Raffaele", Milano
D. Testa
Seconda Università, Napoli

International Scientific Board

J. Betka
Charles University, Prague Czech Republik
P. Clement
ENT Department,University Hospital, Brussels, Belgium
M. Pais Clemente
Department of Otolaryngology, University of Porto, Portugal
R.W. Gilbert
Otolaryngology H&N Surgery, University of Toronto, Canada
M. Halmagyi
Royal Prince Alfred Hospital, Camperdown, Australia
L.P. Kowalski
A C Camargo Cancer Center, Sao Paulo, Brazil
R. Laszig
Universitäts-HNO-Klinik, Freiburg, Germany
C.R. Leemans
VU University Medical Center, Amsterdam, The Netherlands
F. Marchal
Hopitaux Universitaires, Geneve, Switzerland
G. O'Donoghue
ENT Department, Queen's Medical Centre, Nottingham, UK
M. Remacle
CHL Clinique d'Eich, Luxembourg
R.J. Salvi
Center for Hearing and Deafness, Buffalo, NY, USA
B. Scola Yurrita
Hospital General Universitario G. Marañón, Madrid, Spain
J. Shah
Memorial Sloan Kettering Cancer Centrer, New York, USA
H. Stammberger
Medical University, Graz, Austria
H.P. Zenner
Universitäts Hals-Nasen-Ohren-Klinik, Tübingen, Germany

Editorial Board
Editor-in-Chief:
M. Ansarin

President of S.I.O.:
G. Paludetti

Former Presidents of S.I.O.:
L. Coppo, A. Ottaviani, P. Puxeddu, G. Sperati, D. Passali, E. de Campora, A. Sartoris, P. Laudadio, M. De Benedetto, S. Conticello, D. Casolino, A. Rinaldi Ceroni, M. Piemonte, R. Fiorella, A. Camaioni, A. Serra, G. Spriano, R. Filipo, C.A. Leone, E. Cassandro, C. Vicini, M. Bussi

Editorial Staff
Editor-in-Chief:
M. Ansarin
Division of Otolaryngology and Head & Neck Surgery, European Institute of Oncology IRCCS
Via Ripamonti, 435 - 20141 Milan, Italy
Tel. +39 02 57489490 - Fax +39 02 94379216
actaitalicaorl@ieo.it

Associate Editors:
P. Canzi
Dipartimento di Otorinolaringoiatria, Università di Pavia, Fondazione IRCCS Policlinico "San Matteo", Pavia, Italy
pietro.canzi@unipv.it

E. De Corso
Fondazione Policlinico Universitario A. Gemelli IRCCS, Università Cattolica del Sacro Cuore, Roma, Italy
eugenio.decorso@policlinicogemelli.it

A. Karligkiotis
Struttura Complessa di Otorinolaringoiatria, ASST Sette Laghi - Ospedale di Circolo e Fondazione Macchi, Varese, Italy
alkis.karligkiotis@gmail.com

M.G. Rugiu
SOC ORL, Azienda Universitaria Integrata di Udine, Italy
mgrugiuactaorl@gmail.com

E. Zanoletti
Otorinolaringoiatria, Ospedale-Università di Padova, Italy
ezanolettiactaorl@gmail.com

Editorial Coordinator:
F. Chu
Division of Otolaryngology and Head & Neck Surgery
European Institute of Oncology IRCCS, Milan, Italy
francesco.chu@ieo.it

Scientific Secretariat:
G. Pietrobon
Division of Otolaryngology and Head & Neck Surgery
European Institute of Oncology IRCCS, Milan, Italy
giacomo.pietrobon@ieo.it

Editorial Assistant:
P. Moore

Copy Editor:
L. Andreazzi - *landreazzi@pacinieditore.it*

Treasurer:
F. Pagella
Dipartimento di Otorinolaringoiatria, Università di Pavia, Fondazione IRCCS Policlinico "San Matteo", Pavia, Italy
tpagella@libero.it

Argomenti di Acta Otorhinolaryngologica Italica
Editor-in-Chief: M. Ansarin
Editorial Coordinator: M. Tagliabue - *marta.tagliabue@ieo.it*
Division of Otolaryngology and Head & Neck Surgery
European Institute of Oncology IRCCS, Milan, Italy

© Copyright 2020 by
Società Italiana di Otorinolaringoiatria
e Chirurgia Cervico-Facciale
Via Luigi Pigorini, 6/3 - 00162 Rome, Italy

Managing Editor
M. Ansarin

Publisher
Pacini Editore Srl
Via Gherardesca, 1 - 56121 Pisa, Italy
Tel. +39 050 313011 -Fax +39 050 3130300
info@pacinieditore.it - www.pacinimedicina.it

Acta Otorhinolaryngologica Italica is cited in Index Medicus, MEDLINE, PubMed Central, Science Citation Index Expanded, Scopus, Open-J Gate, Free Medical Journals, Index Copernicus, Socolar

2019 Journal Impact Factor, Journal Citation Reports (Source Clarivate, 2020): 1.510
Acta Otorhinolaryngologica Italica is available on Google Scholar

SIOI CICE

PACINI EDITORE MEDICINA

Volume 40
December 2020

6

www.actaitalica.it

Contents

COVID-19

ENT surgical emergencies during the COVID-19 outbreak
Le urgenze chirurgiche otorinolaringoiatriche durante l'epidemia di COVID-19
V. Pontillo, L. Iannuzzi, P. Petrone, P.I. Sciancalepore, C. D'Auria, M. Rinaldi, G. Graziano, N. Quaranta 399

Head and neck

Results of a survey on elderly head and neck cancer patients on behalf of the Italian Association of Radiotherapy and Clinical Oncology (AIRO)
Risultati di una survey su pazienti anziani con tumore testa collo – a nome dell'Associazione Italiana di Radioterapia e Oncologia Clinica (AIRO)
L. Belgioia, F. De Felice, A. Bacigalupo, D. Alterio, A. Argenone, E. D'Angelo, I. Desideri, P.F. Franco, A. Merlotti, D. Musio, E. Orlandi, S. Ursino, F. Paiar. 405

Laryngology

Micronucleus, nucleoplasmic bridge and nuclear bud frequencies in patients with laryngeal carcinoma
Micronucleo, ponte nucleoplasmatico e frequenze di gemme nucleari in pazienti con carcinoma laringeo
I. Yazici, O. Caglar, O. Guclu, H. Cobanoglu, Mahmut Coskun, Münevver Coskun, A. Kilic, F.S. Dereköy 410

Rhinology

Are sinonasal dissection courses a valid instrument for endoscopic sinus surgeons? A report on 7-years of experience
Corsi di chirurgia endoscopica dei seni paranasali: possono essere considerati un valido strumento per il training chirurgico? Rapporto su 7 anni di esperienza
F. Pagella, E. Emanuelli, M. Benazzo, A. Pusateri, S. Ugolini, M. Melegatti, A. Ciorba, S. Pelucchi 415

Effectiveness of superior eyelid endoscopic-assisted approach in the management of selected orbital abscess: considerations on 4 cases
Ruolo dell'approccio trans-palpebrale superiore endoscopico-assistito nella gestione delle complicanze infettive orbitarie multicompartimentali: considerazioni su 4 casi clinici
I. Dallan, L. Cristofani-Mencacci, C. Cambi, M. Scarano, A.P. Casani, V. Seccia. 421

Structural changes in the extracellular matrix after cross-linking of nasal polyp tissue
Cambiamenti strutturali della matrice extracellulare dopo cross-linking del tessuto polipoide nasale
N. Coronel, R. Pezato, J.B. do Amaral, L. Ticlia, T.F. Pinto Bezerra, L.F. Gomes, J. Dreyfuss, W. Chamon, L.C. Gregório 426

Effects of biological therapies on chronic rhinosinusitis in severe asthmatic patients
L'efficacia delle terapie biologiche sulla rinosinusite cronica nel paziente asmatico severo
F. Bandi, S. Gallo, A. Preti, F. Mozzanica, D. Visca, M. Marelli, E. Maddalone, C. Gambarini, A. Vaghi, A. Spanevello, P. Castelnuovo . . 435

Vestibology

Evaluation of a large cohort of adult patients with Ménière's disease: bedside and clinical history
Sindrome di Ménière: valutazione dell'esame vestibolare e della storia clinica in un'ampia popolazione
R. Teggi, R.A. Battista, F. Di Berardino, M. Familiari, I. Cangiano, O. Gatti, M. Bussi 444

Otology

Subtotal petrosectomy and cochlear implantation
Petrosectomia subtotale e impianto cocleare
G. D'Angelo, G. Donati, A. Bacciu, M. Guida, M. Falcioni 450

The effect of N-acetyl cysteine on biofilm layers in an experimental model of chronic otitis media
L'effetto della N-acetil cisteina sullo strato di biofilm in un modello sperimentale di otite media cronica
E. Ersoy Çallıoğlu, S. Berçin, G. Başdemir, M. Kiriş, İ. Tatar, A. Tuzuner, T. Oğuzhan, T. Müderris, M.F. Sargon, M.H. Korkmaz 457

Letters to the Editor

Vertigo and hearing loss during the COVID-19 pandemic – is there an association?
La vertigine e l'ipoacusia durante la pandemia COVID-19 – esiste un nesso?
M. Karimi-Galougahi, A.S. Naeini, N. Raad, N. Mikaniki, J. Ghorbani 463

Looking at the day after COVID-19… what laryngeal sequelae should we expect?
Guardando all'era post COVID-19… quali sequele laringee dobbiamo attenderci?
S. Torretta, L.M. Gaini, M. Gaffuri, L. Pignataro, R. Accorona, P. Capaccio 466

In Memoriam of Oskar Schindler

R. Albera, M. Spadola Bisetti 469

Notiziario SIO 471

Acknowledgements to our reviewers 473

Articles in open access, information for authors including editorial standards for the preparation of manuscripts and submission and Publisher's note available on-line: www.actaitalica.it

ACTA OTORHINOLARYNGOLOGICA ITALICA 2020;40:399-404; doi: 10.14639/0392-100X-N1036

COVID-19

ENT surgical emergencies during the COVID-19 outbreak

Le urgenze chirurgiche otorinolaringoiatriche durante l'epidemia di COVID-19

Vito Pontillo[1], Lucia Iannuzzi[1], Paolo Petrone[2], Pasqua Irene Sciancalepore[1,2], Carlo D'Auria[3], Massimo Rinaldi[1,3], Giusi Graziano[4], Nicola Quaranta[1]

[1] Otolaryngology Unit, Department of BMS, Neuroscience and Sensory Organs, Policlinico di Bari, University of Bari, Italy; [2] Otolaryngology Unit, Ospedale Di Venere, Bari, Italy; [3] Otolaryngology Unit, Ente Ecclesiastico Ospedale Miulli, Acquaviva delle Fonti, Italy; [4] Biomedical Sciences and Human Oncology Department, University of Bari, Italy

SUMMARY

Introduction. The restrictive measures adopted by the Italian Government during the COVID-19 outbreak caused dramatic changes in routine public health care. Surprisingly, emergency activity also registered a reduction in frequency.

Methods. This multicentre retrospective study aims to investigate eventual changes in ENT surgical emergencies in a highly populated area of southern Italy during the COVID-19 pandemic. Data concerning the period between the February 1 and the May 31, 2020 were collected from the main three hospitals in the district and compared with the same period of 2019.

Results. A substantial reduction was found in the number of ENT emergency interventions in 2020 compared to the same period of 2019, particularly in the main lockdown phase and in the tertiary referral centre.

Conclusions. The reduction in the absolute number of emergency ENT interventions can be only partially explained by social distancing and home confinement. We have reason to believe that some of these patients may have not sought medical support due to fear of nosocomial SARS-CoV2 infection. This study could represent a trigger for further implementation of health system responses to emergencies in a period of transition that is likely to last for a prolonged period of time.

KEY WORDS: COVID-19, outbreak, ENT, emergency, surgery

RIASSUNTO

Introduzione. *Le misure restrittive adottate in Italia durante la pandemia di COVID-19 hanno determinato uno stravolgimento delle attività medico chirurgiche. Inaspettatamente, anche le prestazioni urgenti hanno registrato una riduzione.*

Metodi. *Abbiamo retrospettivamente confrontato le urgenze chirurgiche ORL eseguite nei tre principali ospedali della Provincia di Bari nel periodo compreso tra il 1° febbraio e il 31 maggio del 2020 con quelle dello stesso periodo del 2019.*

Risultati. *È stata riscontrata una importante riduzione nel numero di interventi nel 2020 rispetto all'anno precedente, in particolare nella fase del lockdown vero e proprio e nel centro di riferimento terziario.*

Conclusioni. *La riduzione del numero di urgenze chirurgiche ORL può essere solo parzialmente spiegata dal distanziamento sociale e dal confinamento domiciliare imposti dalle misure restrittive. Abbiamo motivo di credere che alcuni pazienti potrebbero aver evitato l'assistenza medica per paura di contrarre l'infezione nosocomiale da SARS-CoV2. Questo primo studio potrebbe avviare un processo di implementazione del sistema di risposta alle urgenze ORL che sarebbe auspicabile in un periodo di transizione potenzialmente duraturo.*

PAROLE CHIAVE: *COVID-19, pandemia, ORL, urgenze, chirurgiche*

Received: July 31, 2020
Accepted: August 18, 2020
Published online: November 24, 2020

Correspondence
Vito Pontillo
Otorinolaringoiatria Universitaria Policlinico di Bari, Università di Bari, piazza Giulio Cesare 11, 70124 Bari, Italy
Tel. +39 080 5592299
E-mail: pontillovito@gmail.com

Funding
None.

Conflict of interest
The Authors declare no conflict of interest.

How to cite this article: Pontillo V, Iannuzzi L, Petrone P, et al. ENT surgical emergencies during the COVID-19 outbreak. Acta Otorhinolaryngol Ital 2020;40:399-404. https://doi.org/10.14639/0392-100X-N1036

© Società Italiana di Otorinolaringoiatria e Chirurgia Cervico-Facciale

OPEN ACCESS

This is an open access article distributed in accordance with the CC-BY-NC-ND (Creative Commons Attribution-Non-Commercial-NoDerivatives 4.0 International) license. The article can be used by giving appropriate credit and mentioning the license, but only for non-commercial purposes and only in the original version. For further information: https://creativecommons.org/licenses/by-nc-nd/4.0/deed.en

Introduction

The COVID-19 pandemic rapidly spread in Europe in the first months of 2020. Italy was one of the first and most affected countries worldwide, with more than 240,000 cases to date. The outbreak mainly struck the northern regions, while the peak was delayed and weakened in middle and southern Italy.

The province of Bari, with more than 1,200,000 inhabitants, is the most populated province in the Puglia region, the third in southern Italy and the seventh in Italy. Thanks to the restrictive measures adopted by the Italian Government, this district was relatively spared by the first COVID-19 outbreak, despite presenting a consistent number of infected people, 1493 at time of writing, almost one-third of all Apulian cases. Nevertheless, the lockdown caused dramatic changes in routine public health care. Surprisingly, even emergency activity has registered a reduction in frequency.

The aim of this study is to investigate changes in ENT surgical emergencies in a highly populated area of southern Italy during the COVID-19 pandemic.

Materials and methods

This multicentre retrospective study was conducted in the three ENT Units covering all emergencies in the province of Bari: 'Policlinico' (tertiary referral centre), 'Di Venere' and 'Miulli' Hospitals (secondary care centres). While 'Di Venere' Hospital remained COVID-free, 'Policlinico' and 'Miulli' were designated to host COVID-19 patients during the pandemic.

We collected data about ENT surgical emergencies performed between the February 1 and the May 31 for 2020 and 2019. We divided this period into four phases, based on the main restrictive decrees released by the Italian Government (Fig. 1):

- Phase 0 (pre-lockdown);
- Phase 1 (lockdown): starting with the beginning of the restrictive measures (March 9, 2020);

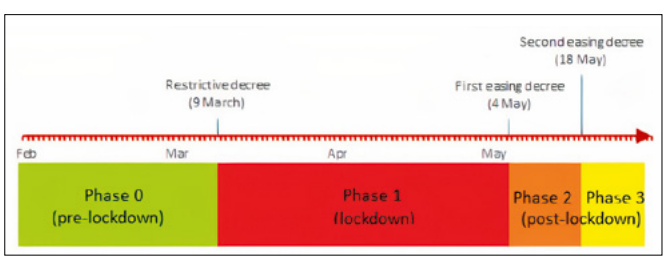

Figure 1. Phases of the study based on the main restrictive and easing decrees by the Italian Government.

- Phase 2 (immediate post-lockdown period): starting with the first and partial relaxation of these measures (May 4, 2020);
- Phase 3 (post-lockdown complete opening): between the 18th (opening decree) and 31st of May 2020.

The same sub-periods were set for 2019.

All procedures were in accordance with the ethical standards of the institutional research committee and with the 1964 Helsinki Declaration and its later amendments or comparable ethical standards. Our Ethics Committee was informed of the retrospective data collection.

Surgical emergencies were divided according to the cause into respiratory, haemorrhagic, suppurative, traumatic and obstructive. Post-operative haemorrhagic complications of elective interventions were the only 'internal emergencies' and were considered separately since this data is strongly influenced by the impairment of scheduled surgery during the outbreak. All 'external' patients were assigned a yellow or red code at the Emergency Department. We retrospectively reclassified priority codes based on our clinical and radiological assessment.

Statistical analysis

The number of emergency interventions was expressed as absolute number and percentage. Age was expressed as mean ± sd. Chi-square or Fisher's exact tests and Mann-Whitney test were used to compare categorical and continuous variables between the two considered periods, respectively. The difference, in terms of surgical interventions, between 2019 and 2020 was calculated as percent change. A p-value < 0.05 was considered statistically significant. The software R (version 3.5.2) was used for statistical analysis.

Results

Forty-five surgical emergencies were performed in the study period of 2020, versus 65 interventions performed in 2019, for a reduction of 30.77% (Tab. I and Fig. 2).

We found a significant reduction ($p = 0.0275$) in the rate of interventions performed in the tertiary referral centre (35.6% vs. 61.5% in 2019). On the other hand, the proportion of cases increased in the secondary clinics (51.1% and 13.3% vs. 30.8% and 7.69% in 2019 respectively), especially at 'Di Venere', the only COVID-free hospital (Tab. I).

A higher percentage of emergencies was recorded for respiratory (31.1% vs. 26.2% of 2019) and haemorrhagic conditions (11.1% vs. 6.15% of 2019), while traumatic (31.1% vs. 35.4%) and infectious causes (22.2% vs. 24.6%) remained stable or slightly reduced (Tab. I). Thus, the pro-

Table I. Emergency interventions in February-May 2019 and 2020.

Variable	2019	2020	p-value
N	65	45	
Age (mean ± sd)	48.6 ± 23.3	52.7 ± 25.6	0.3856
Gender n (%)			
F	23 (35.4)	18 (40.0)	0.6226
M	42 (64.6)	27 (60.0)	
Care centre N (%)			
Hospital 1 (Policlinico)	40 (61.5)	16 (35.6)	
Hospital 2 (Di Venere)	20 (30.8)	23 (51.1)	0.0275
Hospital 3 (Miulli)	5 (7.7)	6 (13.3)	
Causes N (%)			
Respiratory	17 (26.2)	14 (31.1)	
Traumatic	23 (35.4)	14 (31.1)	
Haemorrhagic	4 (6.2)	5 (11.1)	0.9015
Post-operative bleeding	4 (6.2)	2 (4.4)	
Infectious	16 (24.6)	10 (22.2)	
Foreign bodies	1 (1.5)	0 (0.0)	
Subperiods N (%)			
Phase 0	17 (26.2)	14 (31.1)	
Phase 1	31 (47.7)	19 (42.2)	0.9381
Phase 2	10 (15.4)	7 (15.6)	
Phase 3	7 (10.8)	5 (11.1)	

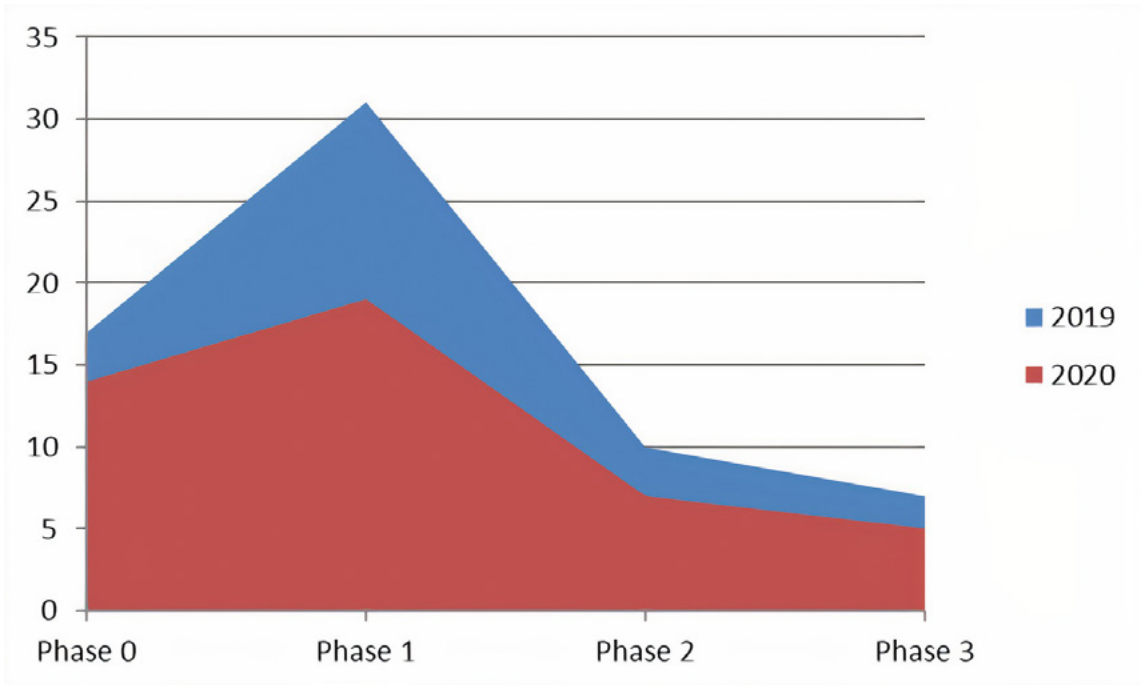

Figure 2. Number of emergency interventions by subperiod in 2019 (blue) and 2020 (red).

Table II. Emergency interventions in the different hospitals.

Causes N (%)	Policlinico		Di Venere		Miulli	
	2019	2020	2019	2020	2019	2020
Respiratory	10 (25)	5 (31.25)	4 (20)	5 (21.74)	3 (60)	4 (66.67)
Traumatic	18 45)	5 (31.25)	4 (20)	9 (39.13)	1 (20)	0 (0)
Haemorrhagic	2 (5)	1 (6.25)	2 (10)	4 (17.39)	0 (0)	0 (0)
Post-operative bleeding	3 (7.5)	1 (6.25)	1 (5)	1 (4.35)	0 (0)	0 (0)
Infectious	7 (17.5)	4 (25)	9 (45)	4 (17.39)	0 (0)	2 (33.33)
Foreign bodies	0 (0)	0 (0)	0 (0)	0 (0)	1 (20)	0 (0)

portion of code red life-threatening emergencies increased from 44.62% of 2019 to 51.11% of 2020.

Table II shows the distribution by cause in the different hospitals.

When considering the different subperiods, we observed a substantial reduction in the number of emergencies in Phase 1, the period of the lockdown (19 cases of 2020 vs. 31 cases of 2019), while we found comparable values in the pre- (Phase 0) and post-lockdown (Phases 2 and 3) periods. The lack of statistical significance ($p = 0.93$) is probably related to the small sample size (Tab. I).

Specifically, a significant reduction ($p = 0.0334$) in the proportion of interventions performed at 'Policlinico' (Hospital 1) was found in Phase 1 (26.3% vs. 58.1% of 2019), again related to a proportional increase at the COVID-free centre (52.63% vs. 38.71% of 2019) (Tab. III). Moreover, the frequency of interventions for traumatic and infective causes halved in this subperiod (4 cases in Phase 1 2020 vs. 9 cases in Phase 1 2019) (Tab. III).

Surprisingly, a significant change ($p = 0.0076$) in the proportion of emergencies between hospitals was also demonstrated at the end of the lockdown, specifically in Phase 3 (Tab. III).

Finally, we investigated the eventual relation between the rate of emergency ENT interventions and the number of new COVID-19 cases per week in the same province. As represented in Figure 3, a fall in the number of interventions was observed in the two weeks (23-29 March and 30 March - 5 April) in which the highest number of new COVID-19 patients was registered (287 and 272 respectively).

Discussion

The COVID-19 pandemic has rapidly spread in Italy, and is strongly influenced by socio-demographic characteristics. The province of Bari is one of the most populated districts in Italy, and thus predictions in terms of pandemic spread and strain on public health care were not promising. Southern Italy was partially spared by the outbreak since the restrictive measures by the Italian Government anticipated possible negative evolutions. These measures impacted both people's lifestyle and public health care routine. In particular, ENT elective activity was deeply affected by the outbreak and various national and international scientific societies proposed best-practice recommendations in order to adapt elective clinical and surgical activity during pandemic conditions [1-5]. Italian societies have also recently published their strategic plan for management of surgical patients in the current era [6,7].

Gelardi et al. [8] reported an important decrease in emergency ENT consultations (80.8%) in the Apulia region during the COVID-19 pandemic. However, to our knowledge the impact of the lockdown on ENT emergency surgical activity has not been previously analysed.

Our analysis showed a reduction in the number of ENT surgical emergencies in the entire province in the months of the outbreak (February-May). The major reduction registered in the tertiary referral centre, specifically during the main lockdown (Phase 1), is probably to put in relation to the fact that a large part of the workforce and spaces were dedicated to the care of COVID-19 patients and some of the emergencies were rerouted to secondary centres. Surprisingly, similar results were also found in the post-lockdown period (Phase 3), when all hospitals were gradually returning to routine activity. We have reason to believe that this could be imputable to the patients' preference to present to COVID-free hospitals for fear of the virus.

It appears obvious that home confinement, traffic restriction and social distancing inevitably reduced the incidence of traumas, common cold and other upper respiratory tract viral or bacterial infections, together with their eventual evolutions. Additionally, the worry about the risk of nosocomial infection probably contributed to the reduction in medical demand in hospitals.

In fact, in our series the proportion of life-threatening respiratory and haemorrhagic emergencies increased during the pandemic, while interventions for traumatic and infectious diseases remained unchanged with respect to the

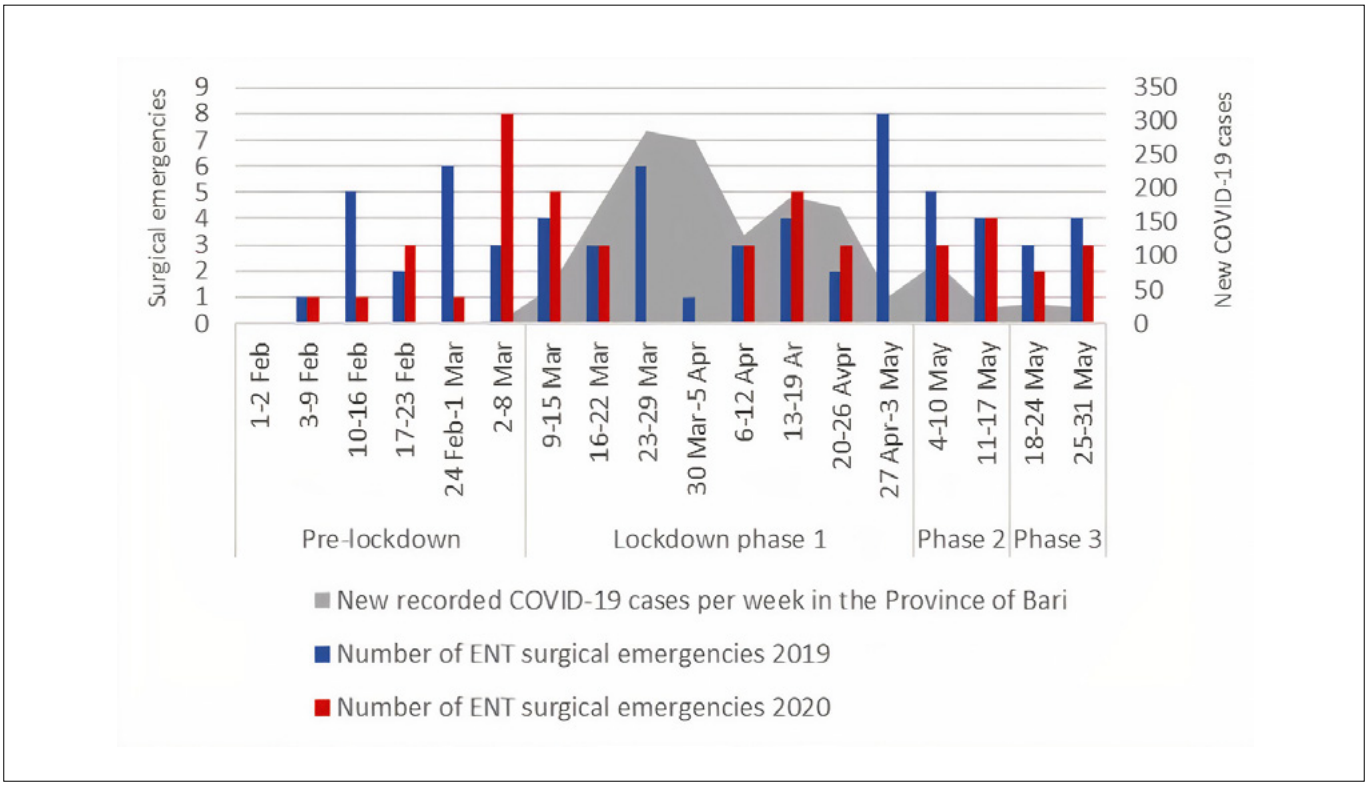

Figure 3. Graphical representation of the relationship between surgical emergencies and new COVID-19 cases per week in the Province of Bari.

Table III. Emergency interventions in the different subperiods categorised by hospital and cause.

Variable	Phase 0			Phase 1			Phase 2			Phase 3		
	2019	2020	p-value	2019	2020	p-value	2019	2020	p-value	2019	2020	p-value
N	17	14		31	19		10	7		7	5	
Care centre, N (%)												
Hospital 1 (Policlinico)	8 (47.06)	8 (57.14)		18 (58.06)	5 (26.32)		8 (80)	3 (42.86)		6 (85.71)	0	
Hospital 2 (Di Venere)	5 (29.41)	5 (35.71)	0.5593	12 (38.71)	10 (52.63)	0.0334	2 (20)	4 (57.14)	0.9825	1 (14.29)	4 (80)	0.0076
Hospital 3 (Miulli)	4 (23.53)	1 (7.14)		1 (3.23)	4 (21.05)		0	0		0	1 (20)	
Causes, N (%)												
Respiratory	4 (23.53)	3 (21.43)		9 (29.03)	8 (42.11)		2 (20)	2 (28.57)		2 (28.57)	1 (20)	
Traumatic	5 (29.41)	5 (35.71)		9 (29.03)	4 (21.05)		5 (50)	2 (28.57)		4 (57.14)	3 (60)	
Haemorrhagic	1 (5.88)	1 (7.14)		2 (6.45)	2 (10.53)		1 (10)	1 (14.29)		0	1 (20)	
Post-operative bleeding	1 (5.88)	1 (7.14)	1	2 (6.45)	1 (5.26)	0.8536	1 (10)	0	0.8056	0	0	1
Infectious	5 (29.41)	4 (28.57)		9 (29.03)	4 (21.05)		1 (10)	2 (28.57)		1 (14.29)	0	
Foreign bodies	1 (5.88)	0		0	0		0	0		0	0	

same period of 2019. Most of our trauma patients were treated for nasal bone fracture, a non-life threatening and optionable condition that certainly registered a decline during the outbreak. On the other hand, the reduction in the percentage of emergency intervention for infectious diseases, especially in Phase 1 (4 cases vs. 9 cases of 2019) may be partially explained by home confinement and social distancing, at least for bacterial suppurations that are

secondary to upper respiratory tract infections. However, the quota of odontogenic neck infections should have been unchanged since it does not depend on social and environmental exposition. Our theory is that a part of these subjects may have ignored the problem for fear of nosocomial SARS-COV2 contagion. No data are available about the possible outcomes of these individuals, but a future focus on the cause of deaths during this pandemic could help to explain this phenomenon.

Figure 3 probably confirms the hypothesis of the role that was played by the population's risk perception on the number of surgical emergencies. Daily bulletins released by local authorities and mass-media about the new infected cases certainly improved people's compliance to restrictions, but they might have indirectly influenced their tendency to see physicians for other diseases, as confirmed by other authors [9,10].

Conclusions

The main limit of our study is the small number of cases and its poor relevance in comparison to other regions where the outbreak was much more severe. Further studies could be useful to verify if the same conditions were recorded in other regions, especially in those most struck by the pandemic. An online survey addressed to all Italian otolaryngologists could help gain knowledge about behaviours in surgical emergency care during the COVID-19 pandemic.

In fact, in consideration of the imminent risk of new COVID-19 waves in Italy and Europe, this study could represent a trigger for the realisation of new strategies to improve the health system response to an emergency in a period of transition that is likely to last for a prolonged period of time. The individuation of specific no-COVID-19 centres dedicated to emergencies and reinforcement of telemedicine strategies may allow early detection and treatment of ENT emergencies.

Acknowledgements

We thank the medical and paramedical staff of the three hospitals for participating in elective and emergency activity during the COVID-19 outbreak. We would also like to show our gratitude to the University of Bari for the support and for providing all the scientific material for the research. All data and material are available and can be provided if requested.

References

1 Bann DV, Patel VA, Saadi R, et al. Impact of coronavirus (COVID-19) on otolaryngologic surgery: brief commentary. Head Neck 2020;42:1227-34. https://doi.org/10.1002/hed.26162

2 Couloigner V, Schmerber S, Nicollas R, et al. COVID-19 and ENT Surgery. Eur Ann Otorhinolaryngol Head Neck Dis 2020;137:161-6. https://doi.org/10.1016/j.anorl.2020.04.012

3 Mehanna H, Hardman JC, Shenson JA, et al. Recommendations for head and neck surgical oncology practice in a setting of acute severe resource constraint during the COVID-19 pandemic: an international consensus. Lancet Oncol 2020;21:e350-9. https://doi.org/10.1016/S1470-2045(20)30334-X

4 Lescanne E, van der Mee-Marquet N, Juvanon JM, et al. Best practice recommendations: ENT consultations during the COVID-19 pandemic. Eur Ann Otorhinolaryngol Head Neck Dis 2020;137:303-8. https://doi.org/10.1016/j.anorl.2020.05.007

5 Radulesco T, Verillaud B, Béquignon E, et al. COVID-19 and rhinology, from the consultation room to the operating theatre. Eur Ann Otorhinolaryngol Head Neck Dis 2020;137:309-14. https://doi.org/10.1016/j.anorl.2020.04.013

6 Quaranta N, Pantaleo A, Berrettini S, et al. Strategic plan for the management of ENT and maxillofacial patients during the post-pandemic transition period (SIOeChCF). https://www.sioechcf.it/piano-strategico-per-la-gestione-del-paziente-orl-durante-il-periodo-di-transizione-a-seguito-della-pandemia-covid-19-versione-2. Accessed 6 July 2020.

7 Castelnuovo P, Turri-Zanoni M, Karligkiotis A, et al. Skull-base surgery during the COVID-19 pandemic: the Italian Skull Base Society recommendations. Int Forum Allergy Rhinol 2020;10:963-7. https://doi.org/10.1002/alr.22596

8 Gelardi M, Iannuzzi L, Trecca EMC, et al. COVID-19: what happened to all of the otolaryngology emergencies? Eur Arch Otorhinolaryngol 2020;277:3231-2. https://doi.org/10.1007/s00405-020-06046-z

9 Pessoa-Amorim G, Camm CF, Gajendragadkar P, et al. Admission of patients with STEMI since the outbreak of the COVID-19 pandemic. A survey by the European Society of Cardiology. Eur Heart J Qual Care Clin Outcomes 2020;6:210-6. https://doi.org/10.1093/ehjqcco/qcaa046

10 De Rosa S, Spaccarotella C, Basso C, et al. Reduction of hospitalizations for myocardial infarction in Italy in the COVID-19 era. Eur Heart J 2020;41:2083-8. https://doi.org/10.1093/eurheartj/ehaa409

ACTA OTORHINOLARYNGOLOGICA ITALICA 2020;40:405-409; doi: 10.14639/0392-100X-N0618

Head and neck

Results of a survey on elderly head and neck cancer patients on behalf of the Italian Association of Radiotherapy and Clinical Oncology (AIRO)

Risultati di una survey su pazienti anziani con tumore testa collo – a nome dell'Associazione Italiana di Radioterapia e Oncologia Clinica (AIRO)

Liliana Belgioia[1,2], Francesca De Felice[3], Almalina Bacigalupo[2], Daniela Alterio[4], Angela Argenone[5], Elisa D'Angelo[6], Isacco Desideri[7], Pier Francesco Franco[8], Anna Merlotti[9], Daniela Musio[3], Ester Orlandi[10], Stefano Ursino[11], Fabiola Paiar[11]

[1] Health Science Department (DISSAL), University of Genoa, Italy; [2] Radiation Oncology Department, Policlinico San Martino Hospital, Genoa, Italy; [3] Department of Radiotherapy, Policlinico Umberto I, "Sapienza" University of Rome , Italy; [4] Division of Radiation Oncology, IEO, European Institute of Oncology IRCCS, Milan, Italy; [5] Radiation Oncology Unit, A.O.R.N. San Pio Benevento, Italy; [6] Radiation Oncology Unit, University Hospital of Modena, Italy; [7] Azienda Ospedaliera Universitaria Careggi, Radiotherapy Unit, Oncology Department, University of Florence, Italy; [8] Department of Oncology, Radiation Oncology, School of Medicine, University of Turin, Italy; [9] Department of Radiation Oncology, S. Croce and Carle Teaching Hospital, Cuneo, Italy; [10] Radiotherapy 2 Unit, Fondazione IRCCS Istituto Nazionale dei Tumori, Milan, Italy; [11] Department of Radiation Oncology, University Hospital of Pisa, Italy

SUMMARY

Objective. Over the years, evidence-based data and technical improvements have consolidated the central role of radiation therapy (RT) in head and neck cancer (HNC) treatment, even in the elderly. This survey aimed to describe the management of the elderly HNC patients among Italian Radiation Oncology Departments (RODs) and provide possible suggestions for improvement.

Methods. An online survey based on 43 questions was sent to RODs via email. For each RODs, a radiation oncologist with expertise in HNC was invited to answer questions addressing his/her demographic data, ROD multidisciplinary unit (MU) organisation and ROD management policy in elderly HNC patients.

Results. In total, 68 RODs answered, representing centres located in 16 Italian regions. MU was considered the core of HNC patient management in almost all the entire country. However, in many RODs, there was minimal access to a routinely comprehensive geriatric assessment at diagnosis. Most treatments were reported by respondents as curative (89% on average) and the preferred treatment technique was intensity modulated radiation therapy (IMRT). A considerable variation between RODs was found for RT target volumes. There was a relation between the specialist's years of experience and type of concomitant systemic therapy prescribed.

Conclusions. Substantial differences in elderly HNC management have been found, especially concerning patient clinical evaluation and target volume delineation. This survey shows the necessity to design a prospective national trial to provide a uniform treatment strategy and define an effective patient-centred approach.

KEY WORDS: elderly patients, head and neck cancer, radiotherapy, combined treatment

RIASSUNTO

Obiettivo. *Il ruolo della radioterapia nel trattamento dei tumori testa collo è ormai consolidato anche per i pazienti anziani. Lo scopo di questa survey è quello di descrivere la gestione del paziente anziano con tumore testa collo tra i centri di radioterapia italiani e fornire possibili suggerimenti di miglioramento.*

Metodi. *Una survey online basata su 43 domande è stata inviata ai vari centri via mail. Per ciascun centro un radioterapista oncologo (RO) esperto nel trattamento di questi tumori è stato invitato a rispondere a domande riguardanti i suoi dati demografici, l'organizzazione del team multidisciplinare (TM) del centro e la gestione del paziente anziano con tumore testa collo.*

Risultati. *In totale hanno risposto 68 RO, rappresentanti centri situati in 16 regioni italiane. Il TM è stato considerato il nucleo della gestione dei pazienti con tumore testa collo in quasi tutto il paese. In molti centri c'era un accesso ridotto a una routinaria valutazione*

Received: January 19, 2020
Accepted: August 29, 2020

Correspondence
Liliana Belgioia
Health Science Department (DISSAL), University of Genoa, via Pastore 1, 16132 Genova, Italy
Tel. +39 010 5558050
E-mail: liliana.belgioia@unige.it

Funding
None.

Conflict of interest
The Authors declare no conflict of interest.

How to cite this article: Belgioia L, De Felice F, Bacigalupo A, et al. Results of a survey on elderly head and neck cancer patients on behalf of the Italian Association of Radiotherapy and Clinical Oncology (AIRO). Acta Otorhinolaryngol Ital 2020;40:405-409. https://doi.org/10.14639/0392-100X-N0618

© Società Italiana di Otorinolaringoiatria e Chirurgia Cervico-Facciale

OPEN ACCESS

This is an open access article distributed in accordance with the CC-BY-NC-ND (Creative Commons Attribution-Non-Commercial-NoDerivatives 4.0 International) license. The article can be used by giving appropriate credit and mentioning the license, but only for non-commercial purposes and only in the original version. For further information: https://creativecommons.org/licenses/by-nc-nd/4.0/deed.en

geriatrica multidimensionale. La maggior parte dei trattamenti (89%) aveva intento curativo e la radioterapia a intensità modulata (IMRT) era la tecnica di trattamento di scelta. È stata rilevata una notevole variazione tra i vari centri circa la scelta dei volumi target e una correlazione tra gli anni di esperienza dello specialista e il tipo di terapia sistemica concomitante prescritta.
Conclusioni. *Sono state riscontrate differenze sostanziali nella gestione del paziente anziano con tumore testa collo, in particolare per quanto riguarda la valutazione clinica del paziente e la delineazione del volume target. Questa survey mostra la necessità di progettare una sperimentazione nazionale prospettica per omogeneizzare la strategia di trattamento e definire un approccio efficace incentrato sul paziente.*

PAROLE CHIAVE: *pazienti anziani, tumore della testa collo, radioterapia, trattamenti combinati*

Introduction

Head and neck cancer (HNC) is the sixth most frequent malignancy worldwide [1]. Despite an increase in the incidence of human papilloma virus (HPV)-related cancer in younger patients, HNC can still be considered pertinent to an elderly population [1,2]. Current data estimate that more than 60% of all new HNC diagnoses occur in patients aged over 65 years [2]. Whether a standard treatment approach, especially in locally advanced cases, is applicable to an elderly population represents a crucial issue. It has been reported that patient age affects the benefits of chemotherapy in this setting [3,4]. The update of the meta-analysis of chemotherapy in head and neck cancer (MACH-NC) showed that the benefit of concomitant chemotherapy was lower in older patients, and, similarly, there was a decreasing effect of bio-radiotherapy (RT) with age in a subgroup analysis of the Bonner's study [3,4]. Nevertheless, these studies were not sufficiently powered for this subgroup analysis and, generally, elderly patients were grossly underrepresented in clinical trials, accounting for < 5% of enrolled cases. The worse clinical outcomes observed in elderly patients are mainly due to patient-related factors, such as general conditions, cognitive status and comorbidity. Consequently, these patients are at a higher risk to develop toxicity leading to the delivery of suboptimal treatments [5]. In recent years, geriatric evaluation and categorisation have gained importance in order to define the most appropriate management. Several screening tools – geriatric 8 (G8), mini-cog, adult comorbidity evaluation-27 (ACE-27), Charlson comorbidity index (CCI), vulnerable elders survey (VES-13) – have been developed to stratify elderly patients into those who would tolerate standard therapy and those who would be at an increased risk of suffering severe toxicity [5]. However, definitive data on impact of these tools for selected frail patients in clinical practice are still scarce.

The purpose of the present national survey was to analyse the patterns of care across Italian Radiation Oncology Departments (RODs) to identify trends that may provide insights into the management of HNC among the elderly.

Materials and methods

An anonymous survey was conducted online using the free Survey Monkey platform (www.SurveyMonkey.com). The survey was open from February to April 2018.

Italian RODs were invited to participate via e-mail with an introduction letter using the AIRO mailing list and to delegate survey compilation to a radiation oncologist with expertise in HNC. Each radiation oncologist was allowed to answer the survey only once. Data were referred to the HNC patient population treated during the year 2017 in each department.

Survey description

A panel of experts of the AIRO Head and Neck working group designed a 43 item-based self-produced questionnaire. The 43 items were defined over a multi-step process and subsequently validated by the AIRO Head and Neck working group. The items were grouped in four sections, including i) ROD and equipment general information, ii) multidisciplinary team characteristics, iii) management of elderly (defined as over 70 years) HNC patients treated with curative intent, iv) management of elderly HNC patients treated with palliative intent. Geriatric assessment (screening tools) and treatment data (total dose, dose per fraction, target volume, technique, regimens of concomitant systemic therapy) were collected.

Statistical analysis. All values – numbers, percentages and estimates – presented in the results are derived from survey data that are prone to sampling limitations. The values met the criteria for statistical reliability. Values that did not meet reliability criteria were suppressed. Descriptive analysis focused on percentages, since they take into account any changes in the size of the total cohort and facilitate the comparison of values across variables.

To identify relatively homogeneous groups based on selected characteristics such as years of experience in HNC field, number of HNC treatment per year in ROD, type of chemotherapy and RT treatment volumes, we used the k-means clustering method via principal components analysis using the Hartigan and Wong method [6]. Multidimensional data are represented on two axes and the cluster centroids (vector of mean values of each variable) can be defined. Statistical analysis was carried out using R-Studio 0.98.1091 software.

Results

Centre distribution

The survey was sent to all Italian RODs (n = 195) and 68 answers were received (response rate = 34.8%). Globally, RODs were recorded in 16 regions, distributed as 32 public structures (48%), 19 University departments (28%), 16 private centres providing health care through the national healthcare system (23%) and 1 private centre. The highest number of RODs was located in the northern regions (n = 40), followed by central (n = 19) and southern regions (n = 9).

Participant characteristics

For each ROD, a radiation oncologist answered the survey. In total, 46 radiation oncologists were aged 30-50 (67.6%) and 22 (32.4%) were over 50 years old. None was less than 30 years old. Thirty-nine were females (57.4%) and 29 were male (42.6%). Forty-seven (69.2%) had been working as a specialist for more than 10 years. All responders declared daily clinical practice in HNC field and the vast majority (n = 64; 94.1%) believed that selected fit elderly patients could receive standard treatment.

HNC patient population characteristics

The global number of HNC patients treated per year per RODs varied from fewer than 10 (n = 2; 2.9%) to more than 100 (n = 7; 10.3%); about half of RODs (n = 31; 45.6%) ranged between 10 to 50 HNC patients. In 2017, the average number of RT treatment courses in elderly HNC patients was 22, with a large variation from fewer than 5 treatments per year in 5 RODs to ≥ 50 in 4 RODs.

Multidisciplinary unit characteristic

In total, 58 RODs discussed HNC cases in a multidisciplinary unit (MU) and most (n = 46; 79.3%) at regular weekly intervals. Other than maxillofacial/head and neck surgeon, medical oncologist, radiation oncologist, radiologist and histopathologist, the other main highly specialised figures included in the MU were nutritionist (n = 28; 48.3%), pain specialist (n = 20; 34.5%), speech and language therapist (n = 12; 20.7%) and head and neck dedicated nurse (n = 24; 41.4%). Only 4 (6.9%) MUs had a geriatrician within the team.

Evaluation of the elderly patient

In clinical practice, 36 RODs (52.9%) used different index score, mainly including Charlson's comorbidity index, ACE-27 score or G-8 tool, to actively screen elderly patients for disorders. Before treatment decision, 11 (16.2%) RODs routinely performed evaluation of function and quality of life in elderly HNC patients, but only 7 (10.3%) RODs systematically applied the comprehensive geriatric assessment (CGA). In 14 (20.6%) RODs, elderly patients scheduled to receive RT with or without concomitant chemotherapy were offered prophylactic percutaneous endoscopic gastrostomy (PEG) tube.

Radiation therapy treatment

In 2017, among the analysed centres, 1404 elderly HNC patients received RT with curative (n = 1255) or palliative (n = 149) intent. In the curative RT setting, 268 patients were treated with concurrent platinum-based chemoradiotherapy (CRT), 108 patients with RT plus cetuximab, 377 patients with definitive RT, 98 patients received induction chemotherapy before RT, 31 patients interstitial brachytherapy and 373 patients underwent surgery followed by adjuvant RT (n = 318) or CRT (n = 55). Adjuvant CRT was mainly programmed in case of adverse risk features, including positive margins and extranodal extension.

In case of curative RT, more than 85% of elderly patients were treated using intensity-modulated RT (IMRT) technique at a planned dose of 66-70 Gy delivered in conventional fractionation (2-2.2 Gy/fraction). Less than 10% of patients received accelerated RT. In total, 30/68 (44%) RODs delineated standard treatment volumes, based on TNM stage and HNC sub-site and 38/68 (56%) RODs proposed target volume reduction.

In the reduced volume group, 9/38 (23.7%) RODs delineated only the macroscopic disease sites and 29/38 (76.3%) defined as target the macroscopic disease sites (including the possible nodal involvement) plus the first uninvolved lymphatic drainage echelon.

In case of concurrent treatment, RT with cetuximab was considered the first option in only 3 RODs; the remainder (n = 65; 95.6%) proposed cetuximab only if patients were considered medically unfit for concomitant platinum-based chemotherapy.

During treatment, 28 RODs (48.3%) declared a higher hospitalisation request than in the case of non-elderly patients.

Cluster analysis

Four variables – year of experience in HNC field, number of HNC treatment per year in ROD, type of chemotherapy and RT treatment volumes – were used in the clustering analysis. These variables were graphically depicted using two axes which represented 76.71% of the total variability (Fig. 1). Using these two components, we found three clusters of RTUs. Details are presented in Figure 1. Cluster 1 was defined by 13 RODs, including Abruzzi (n = 1), Calabria (n = 1), Latium (n = 2), Liguria (n = 1), Lombardy (n = 3), Piedmont (n = 1), Trentino Alto Adige (n = 1), Tuscany (n = 1) and Veneto (n = 2). Cluster 2 was formed by 45 ROD distributed as Abruzzi (n = 2), Campania (n = 3), Emilia Ro-

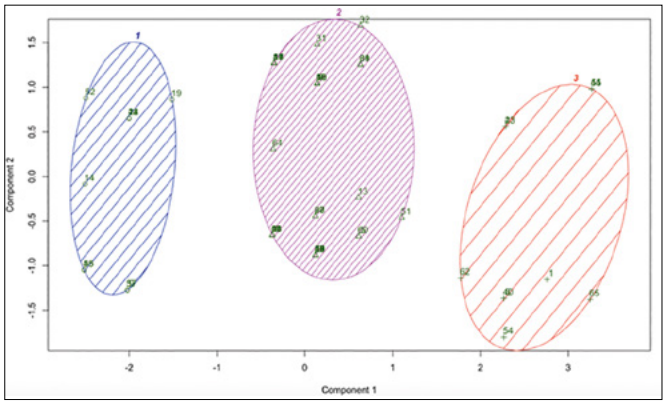

Figure 1. Cluster plot found through k-means clustering analysis.

magna (n = 3), Friuli Venezia Giulia (n = 1), Latium (n = 4), Liguria (n = 3), Lombardy (n = 12), Marches (n = 1), Molise (n = 1), Piedmont (n = 5), Puglia (n = 2), Sardinia (n = 1), Tuscany (n = 5) and Veneto (n = 2). The remaining 10 RODs defined cluster 3 (n = 1 Emilia Romagna, Piedmont, Veneto, Campania; n = 2 Puglia; n = 4 Lombardy).

Cluster 1 showed high young (in term of year of experience) HNC specialists and the highest cetuximab use. Cluster 2 prescribed platinum-based CHT and presented the highest specialist experience. Cluster 3 showed centroid values for specialist experience and chemotherapy prescription.

Discussion

This survey firstly addresses at the national level the relevant issue of the RODs choices for the treatment of elderly patients with locally advanced HNC. In most RODs, a MU discussion is held for HNC cases. The majority of elderly patients (56%) received RT with curative doses but with reduced volumes (in these cases, about 24% and 76% of RODs delineated only the macroscopic disease sites or macroscopic disease sites plus the first uninvolved lymphatic drainage echelon, respectively). The majority of patients received intensity modulated radiotherapy. Interestingly, cluster analysis showed that more experienced specialists prescribed cisplatin-based chemotherapy more often than young HNC specialists did. Possible explanations could include the lower experience with radiation sensitisers and the presumed gentler toxicity profile of cetuximab compared to cisplatin-based toxicity and sequelae, including renal dysfunction and hearing loss. Robust evidence for HNC management in elderly patients is still lacking, but several considerations can be made.

Firstly, both expertise and multidisciplinarity should be emphasised. It is reported that MU meetings change the diagnostic and/or therapeutic approach up to 60% of the cases, due to staging refinement and more frequent use of therapeutic plan escalation [7]; according to the survey results the majority of RODs (85%) discussed HNC cases in a MU.

Secondly, few data exist on the presence of a geriatrician as an effective MU member; our survey recorded that only 6.9% of RODs regularly included a geriatrician in the MU team members. We have mainly ascribed this result to the lack of a standardised method to evaluate HNC elderly patients and the difficulty to integrate a complete geriatric evaluation in the daily clinical practice. Only a minority of RODs (10%) performed a CGA in all elderly patients. Considering that many patients are susceptible to a curative treatment, an adequate geriatric evaluation at diagnosis is extremely relevant to guide therapeutic approach. The main risk is to under-treat or over-treat elderly patients due to their chronological age or their degree of frailty.

To date, the role of CGA is debated; the international society of geriatric oncology (SIOG) recommended its systematic use in the pre-treatment assessment of elderly people with cancer [8], but it is still not validated in HNC management [9]. Actually, two randomised clinical trials [10,11] have been designed to validate CGA in HNC patients, the preliminary results of one of these showed that CGA changed the planned treatment in 8% of patients [12]; nevertheless, no data has demonstrated that CGA ameliorates the results in HN cancer patients. It must also be considered that the main reported issue on systematic adoption of CGA is that take too much time to be performed routinely [8], so often pre-screening evaluation using specific tools such as G8 or VES-13, was performed in order to identify those patients who require further geriatric assessment [13]. Both G8 and VES-13 are validated tools in HNC patients [13] and several literature data clearly indicated that the G8 better correlates with geriatric assessment at baseline compared to the VES-13 (sensitivity 85.7% versus 57.1%, respectively) [14]. Therefore, the G8 should be considered the main screening tool to distinguish between fit from vulnerable HNC patients.

Lastly, the choice of the concomitant systemic therapy, the definition of target volumes and the fractionation schedules remain the major concerns. The meta-analysis of radiotherapy in carcinomas of head and neck (MARCH) collaborative group showed a decreasing effect of altered fractionated in older patients [15]. No firm conclusions can be stated mainly because the intrinsic questionable results generalisability in a meta-analysis and the lack of objective and reproducible criteria to evaluate elderly patient in the included studies.

In our analysis, despite the high percentage of curative treatments (89%), a heterogeneous scenario was depicted, with different options chosen, including concurrent platinum-based chemoradiotherapy, RT plus cetuximab or definitive RT alone. Another key question concerns RT details, such as the distribution of radiation dose over time and target volume delineation.

Radiation volume de-escalation could be an effective strategy to reduce toxicity and facilitate treatment compliance. High-quality RT and adequate patient selection should be promoted to guarantee reliable treatment outcome. In the literature, different experiences reduced RT volume avoiding elective nodal volume irradiation in elderly and frail patients with good rate of local control [16-19]. However, this is not the standard and it should be considered with caution in treatment with radical intent. Moreover, we underline that these data should be interpreted with caution for several issues such as, inhomogeneous study population, irradiation techniques or incomplete follow up [16-19].

This survey had several limitations. First of all, the data do not represent the collection of individual patient data from a database but the answers from a respondent per each centre with inevitable introduction of bias due to uncertainty in data collection. The main inhomogeneities highlight in this survey correspond to points in which literature data does not reveal a clear standard of care. Second, we underline that only about a third of Italian RODs answered the survey (68 of 196 centres). However, considering that one of the missions of the AIRO is to promote research, it is our hope that the obtained data will be a strong incentive and form the basis for the AIRO Head and Neck working group to design a prospective clinical trial especially to identify optimal target volumes and clarify if, a subgroup of elderly patients, might benefit from combined treatment.

Conclusions

This survey documented a significant heterogeneity in the management of elderly patients with HNC. Adequate patient evaluation is mandatory and significant expertise is required to propose a patient-centred treatment. Prospective studies are needed for this setting of patients.

Acknowledgements

The content of the paper has been approved by the Scientific Committee of Italian Association of Radiotherapy and Clinical Oncology (AIRO).

References

1. Vermorken JB, Specenier P. Optimal treatment for recurrent/metastatic head and neck cancer. Ann Oncol 2010;21(Suppl 7):vii252-61. https://doi.org/10.1093/annonc/mdq453
2. Coca-Pelaz A, Halmos GB, Strojan P, et al. The role of age in treatment-related adverse events in patients with head and neck cancer: a systematic review. Head Neck 2019;41:2410-29. https://doi.org/10.1002/hed.25696
3. Pignon JP, le Maître A, Maillard E, et al. Meta-analysis of chemotherapy in head and neck cancer (MACH-NC): an update on 93 randomised trials and 17,346 patients. Radiother Oncol 2009;92:4-14. https://doi.org/10.1016/j.radonc.2009.04.014
4. Bonner JA, Harari PM, Giralt J, et al. Radiotherapy plus cetuximab for locoregionally advanced head and neck cancer: 5-year survival data from a phase 3 randomised trial, and relation between cetuximab-induced rash and survival. Lancet Oncol 2010;11:21-8. https://doi.org/10.1016/S1470-2045(09)70311-0
5. National Comprehensive Cancer Network (NCCN). Guidelines Head and Neck Cancers, Version 1.2019. available at http://www.nccn.org
6. Hartigan JA, Wong MA. Algorithm AS. 136: a K-Means clustering algorithm. J R Stat Soc Ser C (Appl Stat) 1979;28:100-8.
7. Bossi P, Alfieri S. The benefit of a multidisciplinary approach to the patient treated with (chemo) radiation for head and neck cancer. Curr Treat Options Oncol 2016;17:53. https://doi.org/10.1007/s11864-016-0431-3
8. Decoster L, Van Puyvelde K, Mohile S, et al. Screening tools for multidimensional health problems warranting a geriatric assessment in older cancer patients: an update on SIOG recommendations. Ann Oncol 2015;26:288-300. https://doi.org/10.1093/annonc/mdu210
9. Maggiore R, Zumsteg ZS, BrintzenhofeSzoc K, et al.; CARG-HNC Study Group. The older adult with locoregionally advanced head and neck squamous cell carcinoma: knowledge gaps and future direction in assessment and treatment. Int J Radiat Oncol Biol Phys 2017;98:868-83. https:// doi.org/10.1016/j.ijrobp.2017.02.022.
10. Brugel L, Laurent M, Caillet P, et al. Impact of comprehensive geriatric assessment on survival, function, and nutritional status in elderly patients with head and neck cancer: protocol for a multicentre randomised controlled trial (EGeSOR). BMC Cancer 2014;14:427. https://doi.org/10.1186/1471-2407-14-427
11. ClinicalTrials.gov,https://clinicaltrials.gov/ct2/show/NCT03614936?term=NCT03614936&rank=1. Accessed 04 October 2019.
12. Mertens C, Le Caer H, Ortholan C, et al. The ELAN-ONCOVAL (ELderly heAd and Neck cancer-Oncology eValuation) study: evaluation of the feasibility of a suited geriatric assessment for use by oncologists to classify patients as fit or unfit. Ann Oncol 2017;28(suppl. 5):v372-v94. https://doi.org/10.1093/annonc/mdx374
13. Soubeyran P, Bellera C, Goyard J, et al. Screening for vulnerability in older cancer patients: the ONCODAGE Prospective Multicenter Cohort Study. PLoS One 2014;9:e115060. https://doi.org/10.1371/journal.pone.0115060
14. Pottel L, Boterberg T, Pottel H, et al. Determination of an adequate screening tool for identification of vulnerable elderly head and neck cancer patients treated with radio(chemo) therapy. J Geriatr Oncol 2012;3:24-32. https://doi.org/10.1016/j.jgo.2011.11.006
15. Bourhis J, Overgaard J, Audry H, et al.; Meta-Analysis of Radiotherapy in Carcinomas of Head and neck (MARCH) Collaborative Group. Hyperfractionated or accelerated radiotherapy in head and neck cancer: a meta-analysis. Lancet 2006;368:843-54. https://doi.org/10.1016/SO140-6736(06)69121-6
16. Bernier J, Bataini JP. Regional outcome in oropharyngeal and pharyngolaryngeal cancer treated with high dose per fraction radiotherapy. Analysis of neck disease response in 1646 cases. Radiother Oncol 1986;6:87-103. https://doi.org/10.1016/s0167-8140(86)80015-9
17. Boysen M, Lovdal O, Soberg R, et al. Elective radiotherapy of the neck in patients with squamous cell carcinoma of the head and neck. ORL J Otorhinolaryngol Relat Spec 1992;54:103-7. https://doi.org/10.1159/000276274
18. Mendenhall WM, Million RR, Cassisi NJ. Elective neck irradiation in squamous-cell carcinoma of the head and neck. Head Neck Surg 1980;3:15-20. https://doi.org/10.1002/hed.2890030105
19. Van den Bosch S, Dijkema T, Verhoef LC, et al. Patterns of recurrence in electively irradiated lymph node regions after definitive accelerated intensity modulated radiation therapy for head and neck squamous cell carcinoma. Int J Radiat Oncol Biol Phys 2016;94:766-74. https://doi.org/10.1016/j.ijrobp.2015.12.002

ACTA OTORHINOLARYNGOLOGICA ITALICA 2020;40:410-414; doi: 10.14639/0392-100X-N0490

LARYNGOLOGY

Micronucleus, nucleoplasmic bridge and nuclear bud frequencies in patients with laryngeal carcinoma

Micronucleo, ponte nucleoplasmatico e frequenze di gemme nucleari in pazienti con carcinoma laringeo

Ibrahim Yazici[1], Ozge Caglar[2], Oguz Guclu[2], Hayal Cobanoglu[3], Mahmut Coskun[4], Münevver Coskun[3], Aytac Kilic[2], Fevzi Sefa Dereköy[2]

[1] Deparment of Otorhinolaryngology, Ezine State Hospital Çanakkale, Turkey; [2] Deparment of Otorhinolaryngology, Çanakkale Onsekiz Mart University, Faculty of Medicine, Çanakkale, Turkey; [3] Çanakkale Onsekiz Mart University, Health Services Vocational College, Çanakkale, Turkey; [4] Çanakkale Onsekiz Mart University, Faculty of Medicine, Department of Medical Biology, Çanakkale, Turkey

SUMMARY

The aim of the study is to determine and compare micronucleus (MN), nucleoplasmic bridge (NPB) and nuclear bud (NBUD) frequencies in patients with laryngeal carcinoma and healthy controls. The study was conducted in the School of Medicine of Onsekiz Mart University. A total of 102 volunteers, 51 of whom had laryngeal carcinoma and 51 of whom were healthy control subjects, participated in this study. The Cytokinesis-Block Micronucleus Assay (CBMN) was applied to peripheral blood lymphocytes taken from patients and controls. We evaluated MN, NPBs and NBUDs frequencies in patients with laryngeal carcinoma and compared the results with those in the control group. The frequencies of MN, NPBs and NBUDs of patients with laryngeal carcinoma were found significantly higher than those in the control group (P = 0.01, P = 0.004, P = 0.01, respectively). MN, NPB and NBUD frequencies were also compared in the patients with and without pesticide exposure, and the means of all frequencies was higher in patients with pesticide exposure (P = 0.001, P = 0.02 respectively). The MN, NPBs and NBUDs frequencies of the patients with laryngeal cancer were significantly higher than those of the control group, and pesticide exposure might be a risk factor that increases genomic instability and risk of laryngeal cancer.

KEY WORDS: micronucleus, nucleoplasmic bridge, nuclear bud, larynx cancer, frequency

RIASSUNTO

Lo scopo dello studio è quello di valutare e confrontare le frequenze relative alla presenza di micronucleo (MN), ponte nucleoplasmatico (NPB) e gemma nucleare (NBUD) in pazienti con carcinoma laringeo e popolazione sana. Lo studio è stato condotto presso un istituto universitario di medicina. Sono stati arruolati 102 volontari, 51 dei quali con carcinoma laringeo e 51 controlli sani. Il metodo di Cytokinesis-Block Micronucleus Assay (CBMN) è stato applicato ai linfociti del sangue periferico dei casi e dei controlli. Abbiamo valutato le frequenze di MN, NPB e NBUD nel paziente con carcinoma laringeo e confrontato i risultati con il gruppo dei controlli. Le frequenze MN, NPB e NBUD dei pazienti con carcinoma laringeo sono risultate significativamente più alte rispetto al gruppo di controllo (P = 0,01, P = 0,004, P = 0,01, rispettivamente). Nello studio, le frequenze MN, NPB e NBUD sono state confrontate in pazienti con e senza esposizione ai pesticidi. I risultati hanno mostrato che la media delle frequenze di NBP, MN e NBUD era significativamente più alta nei pazienti con esposizione ai pesticidi (P = 0,001, P = 0,02 rispettivamente). Il presente studio ha indicato che un aumento delle frequenze di MN, NPB e NBUD nei linfociti periferici umani potrebbe essere utilizzato per prevedere il rischio individuale di sviluppare un carcinoma laringeo. Inoltre, i nostri risultati indicano che l'esposizione ai pesticidi potrebbe aumentare il rischio di carcinoma laringeo.

PAROLE CHIAVE: *micronucleo, ponte nucleoplasmatico, gemma nucleare, cancro alla laringe, frequenza*

Received: September 30, 2019
Accepted: May 5, 2020

Correspondence
Ozge Caglar
Onsekiz Mart University, Faculty of Medicine, Department of Otorhinolaryngology, Canakkale-Turkey 09000
Tel. 05326364459
E-mail: ozgecaglar@comu.edu.tr

Funding
This work was supported by Çanakkale Onsekiz Mart University The Scientific Research Coordination Unit, Project number: TTU-2014-197.

Conflict of interest
The Authors declare no conflict of interest.

How to cite this article: Yazici I, Caglar O, Guclu O, et al. Micronucleus, nucleoplasmic bridge and nuclear bud frequencies in patients with laryngeal carcinoma. Acta Otorhinolaryngol Ital 2020;40:410-414. https://doi.org/10.14639/0392-100X-N0490

© Società Italiana di Otorinolaringoiatria e Chirurgia Cervico-Facciale

OPEN ACCESS

This is an open access article distributed in accordance with the CC-BY-NC-ND (Creative Commons Attribution-Non-Commercial-NoDerivatives 4.0 International) license. The article can be used by giving appropriate credit and mentioning the license, but only for non-commercial purposes and only in the original version. For further information: https://creativecommons.org/licenses/by-nc-nd/4.0/deed.en

Introduction

Laryngeal carcinoma (LC) comprises 30% of all head and neck malignancies [1]. The incidence of LC is 5 times higher in males than in females, although the incidence of LC in female patients has increased in recent years. This is related to the increasing smoking rates in females and to the increases in participation in work life which also elevates toxic exposure [2]. Cancer rates increase after the fifth decade of life and reache the highest rates in the seventh or eighth decade of life. The incidence is 1% before the third decade [3]. Squamous cell carcinoma comprises 85-90% of laryngeal malignancies [4]. To increase the disease-free life span, survival and organ protection rates in laryngeal carcinoma, better understanding of behaviours is needed.

Tumour stage, anatomical localisation, histopathological differentiation and neck metastasis are general prognostic factors: neck metastasis is accepted as a particularly poor prognostic sign [5]. However, different tumour behaviours can be observed even in tumours with similar histopathological diagnosis, grade and stage, leading investigators to study additional prognostic factors and conduct new molecular studies.

The accumulation of genetic damage leading to genomic instability is a recognised cause of cancer [6,7]. Therefore, it is important to measure the genetic damage [8]. In human peripheral lymphocytes (PBL), the CBMN assay is one of the standard cytogenetic tests for evaluation of genetic damage because of its sensitivity, reliablity and low cost. CBMN is a comprehensive method that allows determination of multiple markers such as MN, NPB and NBUD arising from different genetic mechanisms [9,10]. The mechanisms of MN are chromosome and/or chromatid breaks and mal-segregated chromosomes. Dicentric chromosomes and gene amplifications are the mechanisms of NPB and NBUD, respectively. MN and NBUD may sometimes occur via breakage of NPBs [9,11]. These nuclear anomalies, which are markers of genomic instability, are frequently seen in cancer [6]. Numerous studies have validated that there is a positive correlation between increased MN, NPB and NBUD frequencies in PBL and cancer risk [6,8,12-15].

The CBMN assay is a useful method to monitor genomic instability, and many recent events reveal that the increased genomic instability in PBL might be an early event in carcinogenesis [6,16]. To the best of the authors' knowledge, there is no data about MN, NPB and NBUD frequencies in patients with LC.

In the present study, we aimed to determine the frequencies of MN, NPB and NBUD in PBL collected from individuals with LC, who were diagnosed by the ear, nose and throat (ENT) department, and healthy individuals who lived in Çanakkale, Turkey. For this purpose, we carried out the CBMN assay.

Methods

Population

A total of 102 volunteers, 51 with LC and 51 healthy control subjects, participated in this study. LC patient files were reviewed. Patients' age, gender, occupation, pesticide exposure, clinical history, anatomical location of disease, smoking history, radiotherapy history, physical examination, and TNM classifications were recorded (Tab. I). Cancers were staged according to the 2002 AJCC guidelines [17]. All patients had undergone video laryngoscope examination. Lymph node positivity was evaluated with both physical examination and ultrasonography. The type of the treatment, recurrence and metastasis frequency were noted. Lymph node invasion and tumour grade were recorded as well. Pathology reports were evaluated. LC patients were divided based on anatomical location of disease (supraglottic, glottic, subglottic), surgery type (partial, total laryngectomy, microlaryngoscopic resection), radiotherapy history and lymph node positivity of the neck. The control group was selected from healthy individuals who had no cancer cases in their family and who were over 40 years of age. This research was approved by the Ethics Committee of the Faculty of Medicine. Informed consent was obtained from each patient and control.

Table I. Size and characteristics of the studied population.

	Case (%)	Control (%)
N	51	51
Age		
Mean ± sd	64 ± 8.3	51 ± 7
Range	38-81	41-67
Gender		
Male	51 (100)	24 (47.1)
Female	0	27 (52.9)
Smoking		
Yes	51 (100)	39 (76.0)
No	0	12 (24.0)
Tumour stage		-
T1	18 (35.3)	
T2	22 (43.1)	
T3	9 (17.6)	
T4	2 (3.9)	
Tumour Location		-
Glottic	46 (90.2)	
Supraglottic	5 (9.8)	
Lymph node metastasis		-
Yes	11 (21.6)	
No	40 (78.4)	
Radiotherapy		-
Yes	24 (47.1)	
No	27 (52.9)	
Occupational exposure to pesticide		-
Yes	24 (47.1)	
No	27 (52.9)	

Chemicals

Chemicals used in the study were purchased from the following suppliers; cytochalasin B, culture medium RPMI 1640, foetal calf serum from Sigma (Germany), phytohaemagglutinin from Biological Industries (Israel), Giemsa, methanol, glacial acetic acid, potassium chloride from Merck (Germany).

Cytokinesis-block micronucleus assay

Fenech's method was used with minor modifications [10]. A 5 mL peripheral blood sample obtained from each donor taken in sterile heparinised tubes. A culture medium mixture, including 4 mL medium (RPMI 1640), 1 mL serum (foetal calf serum), 0.2 mL phytohemagglutinin (as a mitogen), was prepared for each donor. 0.5 mL whole blood, taken from each donor, was added to the medium. All cultures were incubated at 37°C for 72 h. At hour 44, cytochalasin B (6 μg/L) was added to each culture to stop cytokinesis. After 72 h, the cultures were harvested. At the harvest stage, the cells were firstly treated with cold potassium chloride (0.075 mol/L) as a hypotonic solution and culture tubes were centrifuged at 1000 rpm for 5 min; the supernatant was discarded. Secondly, the pellet was resuspended and fixed in methanol-acetic acid (7:1, v/v) three times. 5% Giemsa was used to stain slides. We evaluated 1000 binucleated cells under a light microscope for each individual. The microscopic evaluation of the slides was performed at x1000 magnification according to Fenech's criteria [18].

Statistical evaluation

We used frequency distribution, one sample t test, one-way analysis of variance (ANOVA) and correlation analysis. We used the SPSS (Statistical Package for the Social Sciences) 10.0 statistical program to evaluate the data. The Kolmogorow-Smirnov goodness-of-fit test was used to check the normal distribution of data. The MN, NPB and NBUDS rates were compared between LC patients and the control group. Results with $p < 0.05$ were considered statistically significant.

Results

A total of 102 volunteers, 51 with LC diagnosis by the ENT department and 51 control subjects, participated in the study. In the cancer group, all patients (n = 51) with LC were male, smokers, and the mean age was 64 (38-81). The tumour locations were 90.2% glottic and 9.8% supraglottic. In the control group, 47.1% were male, 52.9% were female and 76% were smokers.

Table II shows the MN, NPB and NBUD values of the control group and the cancer group. In the cancer group, the MN, NPB and NBUD values were 28.1, 1.31 and 3.33, respectively. In the control group, the MN, NPB and NBUD values were 13.9, 0.29 and 0.02, respectively. The analyses showed that there were significant differences between the control and the cancer groups in terms of MN, NPB and NBUDS values ($p = 0.01$, $p = 0.004$, $p = 0.01$, respectively).

Table II. Descriptive statistics of MN, NPB. and NBUDS values in cancer and control groups.

		N	Mean ± SD (‰)	p
MN	Cancer group	51	28.1 ± 15.4	0.01
	Control group	51	13.9 ± 4.07	
NPB	Cancer group	51	1.31 ± 2.28	0.004
	Control group	51	0.29 ± 0.75	
NBUD	Cancer group	51	3.33 ± 3.60	0.01
	Control group	51	0.02 ± 0.14	

MN: micronucleus; NPB: nucleoplasmic bridge; NBUD: nuclear bud; SD: standard deviation.

The MN, NPB and NBUDS values were compared in the patients with and without radiotherapy treatment (Tab. III). The average MN, NBP and NBUD frequencies in the group treated with radiotherapy were 32.8, 1.88 and 4.13, respectively. In the group treated without radiotherapy, the average MN, NBP and NBUD frequencies were 24.0, 0.81 and 2.63, respectively. There were no significant differences between the two groups in terms of MN, NPB and NBUD frequencies ($p > 0.05$).

The MN, NPB and NBUD frequencies were compared in patients with and without pesticide exposure (Tab. IV). The results showed that the mean of MN, NBP and NBUD frequencies in the patients with pesticide exposure were higher than in the patients without pesticide exposure. However, the differences in the median values of the MN and NBUD frequencies between the two groups were statistically significant ($p = 0.01$, $p = 0.02$ respectively).

Discussion

LC comprises 25-30% of all head and neck malignancies, and is the most common cancer of the upper respiratory

Table III. Descriptive statistics of MN, NPB, NBUD in LC with and without radiotherapy treatment.

	RT	N	Mean ± SD (‰)	p
MN	With RT	24	32.7 ± 20.6	0.06
	Without RT	27	23.9 ± 6.5	
NPB	With RT	24	1.8 ± 2.8	0.11
	Without RT	27	0.8 ± 1.4	
NBUDS	With RT	24	4.13 ± 4.52	0.14
	Without RT	27	2.63 ± 2.41	

MN: micronucleus; NPB: nucleoplasmic bridge; NBUD: nuclear bud; SD: standard deviation; RT: radiotherapy.

Table IV. Descriptive statistics of MN, NPB and NBUD values according to pesticide use status of patients in the cancer group.

	Pesticide exposure	N	Mean ± SD	p
MN	Yes	24	36.0 ± 17.7	0.01
	No	27	21.1 ± 8.4	
NPB	Yes	24	1.92 ± 2.82	0.09
	No	27	0.78 ± 1.52	
NBUD	Yes	24	4.63 ± 4.61	0.02
	No	27	2.19 ± 1.81	

MN: micronucleus; NPB: nucleoplasmic bridge; NBUD: nuclear bud; SD: standard deviation.

tract [19,20]. In the current study, we evaluated genomic damage in patients with LC. For this purpose, the CBMN assay was used in PBL. CBMN is sensitive, reliable and has low cost. Moreover, it is a comprehensive and preferred method allowing assessment of chromosomal damage [9,10,18]. In genetic toxicology, genetic damage at chromosome level is important because the mutation of a chromosome is a notable event for carcinogenesis [18].

The MN, NPB and NBUD frequencies were determined in the patient group, and compared with those of the control group. The analyses demonstrated that there were significant differences between the control and cancer groups in terms of MN, NPB and NBUD frequencies ($p = 0.01$, $p = 0.004$, $p = 0.01$, respectively). To our knowledge, there is no data related to genomic damage assessed in PBL in patients having LC. However, there are many studies on genomic damage in different cancer types. The result on the MN frequency obtained in the present study is consistent with the results of other studies [8,12-15]. There are only a few studies evaluating the frequency of NPB, NBUD and MN [21]. Pardini [21] reported that MN and NBUD frequencies were significantly elevated in bladder cancer patients compared to controls. Similarly, a significant relationship was found in the present study. However, contrary to Pardini [21], NPB, MN and NBUD were all significantly increased in the present study. NPB is an indicator of dicentric chromosomes in the anaphase stage of mitosis. It occurrs because of misrepair of DNA breaks and/or telomere end fusions. NBUDs caused by gene amplification and MN arise from chromosome fragments and/or whole chromosome, but MN and NBUD may sometimes occur via breakage of NPBs. Our findings showed that MN, NPB, and NBUDs frequencies representing the above-mentioned genetic mechanisms were increased in the cancer group, which was statistically significant.

Many epidemiological and experimental studies [2,22,23] and the 2004 and 2010 monographs of the International Agency for Research on Cancer (IARC) concluded that smoking habit is an important risk factor in cancer [24] and LC was more common in men [2]. In the present study, all the patients with LC were men and smokers. The result is consistent with previous findings investigating the relationship between smoking/gender and LC.

Since the two groups did not match in terms of gender and smoking habit, we compared only males and smokers in both groups. The mean of the MN, NPB, and NBUD frequencies for smokers were compared between the patient group ($n = 51$) and the control group ($n = 39$). The analyses demonstrated that the MN, NPB, and NBUD frequencies were significantly higher in the cancer group than the control group ($p < 0.001$, $p < 0.001$, $p < 0.001$ respectively). Similarly, the male controls ($n = 24$) and the male patients ($n = 51$) were compared in terms of MN, NPB, and NBUD values and a significant difference was found between the two groups ($p < 0.001$, $p < 0.01$, $p < 0.001$ respectively). As a result, gender and smoking habit were not found to be the confounding factors for the increase in MN, NPB, and NBUD frequencies.

There are many pesticides in the 2A (probably carcinogenic to humans) and 2B (possibly carcinogenic to humans) lists of the IARC [25]. Moreover, there have been relationships between many types of cancer and pesticide exposure such as brain, leukaemia, kidney, lung and prostate cancers [25]. There are some studies on cancer risk in farmers exposed to pesticides, which indicated a link between pesticide exposure and increased risk of cancer [26,27]. However, only a few studies examined the relationship between pesticide exposure and head and neck cancers. These studies reported that pesticide exposure might be a risk factor for head and neck cancers [28]. In our study, approximately half of the patients with LC had previous pesticide exposure. Therefore, we compared MN, NPB and NBUD frequencies in patients with and without pesticide exposure. The results showed that the mean of the NBP frequencies was higher and that the mean of the MN and NBUD frequencies were significantly higher in patients with pesticide exposure ($p = 0.001$, $p = 0.02$ respectively). Therefore, our findings suggest that pesticide exposure might be a risk factor that increases genomic instability and risk of LC.

In the cancer group, the frequencies of MN, NPB, and NBUD were compared between patients with and without radiotherapy treatment. All biomarkers were found to be higher in patients with radiotherapy treatment, but none of the increases was statistically significant ($p > 0.05$). To our knowledge, there is no data comparing genomic damage in patients with and without radiotherapy treatment. However, in the literature, there are some studies evaluating genomic damage in cancer patients undergoing radiotherapy. These studies showed that genomic damage increased significantly in cancer patients undergoing radiotherapy [29,30].

The main limitation of the present study was that it had a small number of patients. For this reason, future studies should be designed with larger cohorts. Another limitation of the study was lack of information on pesticide exposure of patients with LC, such as what types of pesticides were used.

Conclusions

The MN, NPBs and NBUDs frequencies of patients with LC were significantly higher than those in the control group. When we compared the genetic damage in the pesticide-exposed and nonexposed patients with LC, genetic damage was significantly higher in the patients with LC who were exposed to pesticides. Our findings suggest that pesticide exposure might be a risk factor that increases genomic instability and risk of LC. However, these data must be supported by future studies with a larger number of cases.

References

1. Beasley N, Gullane P. Cancer of the larynx, paranasal sinuses and temporal bone. In: Lee KJ, editor. Essential Otolaryngology. Chapter 27. Toronto: McGrawHill Medical Publishing Company; 2003.
2. Gallus S, Bosetti C, Franceschi S, et al. Laryngeal cancer in women: tobacco, alcohol, nutritional, and hormonal factors. Cancer Epidemiol Biomarkers Prev 2003;12:514-7.
3. Lipkin A, Miller RH, Woodson GE. Squamous cell carcinoma of the oral cavity, pharynx, and larynx in young adults. Laryngoscope 1985;95:790-3.
4. Cardesa A. Malignant epithelial tumours of larynx. Bas Boyun 2003;6-9.
5. Pera E, Moreno A, Galindo L. Prognostic factors in laryngeal carcinoma: a multifactorial study of 416 cases. Cancer 1986;58:928-34. https://doi.org/10.1002/1097-0142(19860815)58:4<928::aicncr2820580421>3.0.co;2-j
6. Bonassi S, El-Zein R, Bolognesi C, et al. Micronuclei frequency in peripheral blood lymphocytes and cancer risk: evidence from human studies. Mutagenesis 2011;26:93-100. https://doi.org/10.1093/mutage/geq075
7. El-Zein R, Vral A, Etzel CJ. Cytokinesis-blocked micronucleus assay and cancer risk assessment. Mutagenesis 2011;26:101-6. https://doi.org/10.1093/mutage/geq071
8. Kiraz A, Açmaz G, Uysal G, et al. Micronucleus testing as a cancer detector: endometrial hyperplasia to carcinoma. Arch Gynecol Obstet 2016;293:1065-71. https://doi.org/10.1007/s00404-016-4157-z
9. Bonassi S, Znaor A, Ceppi M, et al. An increased micronucleus frequency in peripheral blood lymphocytes predicts the risk of cancer in humans. Carcinogenesis 2007;28:625-31. https://doi.org/10. 1093/carcin/bgl177
10. Fenech, M. Cytokinesis-block micronucleus cytome assay. Nat Protoc 2007;2:1084-104. https://doi.org/10.1038/nprot.2007.77
11. Fenech M. Cytokinesis-block micronucleus assay evolves into a "cytome" assay of chromosomal instability, mitotic dysfunction and cell death. Mutat Res 2006;600:58-66. https://doi.org/10.1016/j.mrfmmm.2006.05.028.
12. El-Zein RA, Fenech M, Lopez MS, et al. Cytokinesis-blocked micronucleus cytome assay biomarkers identify lung cancer cases amongst smokers. Cancer Epidemiol Biomarkers Prev 2008;17:1111-9. https://doi.org/10.1158/1055-9965
13. Çelik DA, Koşar PA, Özçelik N, et al. Cytogenetic finding of breast cancer cases and in their first-degree relatives. J Breast Cancer 2013;16:285-90. https://doi.org/10.4048/jbc.2013.16.3.285.
14. Devi SM, Balachandar V, Arun M, et al. Analysis of genetic damage and gene polymorphism in hepatocellular carcinoma (HCC) patients in a South Indian population. Dig Dis Sci 2013;58:759-67. https://doi.org/10.1007/s10620-012-2409-8
15. Alfaisal AH, Al-Ramahi IJ, Abdul-Hassan IA, et al. Micronucleus frequency among Iraqi thyroid disorder patients. Comp Clin Path 2014;23:683-8. https://doi.org/10.1007/s00580-012-1671-7
16. Bolognesi C, Filiberti R, Neri M, et al. High frequency of micronuclei in peripheral blood lymphocytes as index of susceptibility to pleural malignant mesothelioma. Cancer Res 2002;62:5418-9
17. Greene FL, Page DL, Fleming ID, et al. AJCC cancer staging manual. USA: Springer; 2002.
18. Fenech M. The in vitro micronucleus technique. Mutat Res 2000;455:81-95.
19. Lu B, Li J, Gao Q, et al. Laryngeal cancer risk and common single nucleotide polymorphisms in nucleotide excision repair pathway genes ERCC1, ERCC2, ERCC3, ERCC4, ERCC5 and XPA. Gene 2014;542:64-8. https://doi.org/10.1016/j.gene.2014.02.043
20. Peller M, Katalinic A, Wollenberg B, et al. Epidemiology of laryngeal carcinoma in Germany, 1998-2011. Eur Arch Otorhinolaryngol 2016;273:1481-7. https://doi.org/10.1007/s00405-016-3922-8
21. Pardini B, Viberti C, Naccarati A, et al. Increased micronucleus frequency in peripheral blood lymphocytes predicts the risk of bladder cancer. Br J Cancer 2017;116:202-10. https://doi.org/10.1038/bjc.2016.411
22. Huang R, Wei Y, Hung RJ, et al. Associated links among smoking, chronic obstructive pulmonary disease, and small cell lung cancer: a pooled analysis in the International Lung Cancer Consortium. EBioMedicine 2015;2;1677-85. https://doi.org/10.1016/j.ebiom.2015.09.031.
23. Hori M, Tanaka H, Wakai K, et al. Secondhand smoke exposure and risk of lung cancer in Japan: a systematic review and meta-analysis of epidemiologic studies. Jpn J Clin Oncol 2016;46:942-51. https://doi.org/10.1093/jjco/hyw091
24. IARC. Personal habits and indoor combustions. IARC Monogr Eval Carcinog Risks Hum 2012;100:319-31.
25. Bolognesi C, Holland N. The use of the lymphocyte cytokinesis-block micronucleus assay for monitoring pesticide-exposed populations. Mutat Res Rev Mutat Res 2016;770:183-203. https://doi.org/10.1016/j.mrev.2016.04.006
26. Andreotti G, Freeman LEB, Hou L, et al. Agricultural pesticide use and pancreatic cancer risk in the Agricultural Health Study Cohort. Int J Cancer 2009;124:2495-500. https://doi.org/10.1002/ijc.24185
27. Band PR, Abanto Z, Bert J, et al. Prostate cancer risk and exposure to pesticides in british columbia farmers. Prostate 2011;71:168-83. https://doi.org/10.1002/pros.21232
28. Amizadeh M, Safari-Kamalabadi M, Askari-Saryazdi G, et al. Pesticide exposure and head and neck cancers: a case-control study in an agricultural region. Iran J Otorhinolaryngol 2017;29:275-85.
29. Cao J, Liu Y, Sun H, et al. Chromosomal aberrations, DNA strand breaks and gene mutations in nasopharyngeal cancer patients undergoing radiation therapy. Mutat Res 2002;504:85-90. https://doi.org/10.1016/s0027-5107(02)00082-9
30. Hintzsche H, Polat B, Schewe V, et al. Micronucleus formation kinetics in buccal mucosa cells of head and neck cancer patients undergoing radiotherapy. Toxicol Lett 2012;212:33-7. https://doi.org/10.1016/j.toxlet.2012.04.020

ACTA OTORHINOLARYNGOLOGICA ITALICA 2020;40:415-420; doi: 10.14639/0392-100X-N0705

Rhinology

Are sinonasal dissection courses a valid instrument for endoscopic sinus surgeons? A report on 7-years of experience

Corsi di chirurgia endoscopica dei seni paranasali: possono essere considerati un valido strumento per il training chirurgico? Rapporto su 7 anni di esperienza

Fabio Pagella[1,2], Enzo Emanuelli[3], Marco Benazzo[1,2], Alessandro Pusateri[4], Sara Ugolini[1,2], Michela Melegatti[5], Andrea Ciorba[5], Stefano Pelucchi[5]

[1] ENT Department, I.R.C.C.S. Policlinico San Matteo-University of Pavia, Italy; [2] ENT Department, University of Pavia, Italy; [3] Department of Neuroscience, Institute of Otorhinolaryngology, University Hospital of Padova, Italy; [4] ENT and Skull-Base Surgery Department, Department of Neurosciences, Ospedale Papa Giovanni XXIII, Bergamo, Italy; [5] ENT & Audiology Unit, Department of Neuroscience and Rehabilitation, University Hospital of Ferrara, Italy

SUMMARY

Sinonasal dissection courses have been reported to be effective in teaching sinonasal anatomy to trainees, and in improving surgical skills for trained surgeons. Between 2013 and 2019, a standardised structured questionnaire was handed out to 130 participants of 8 sinonasal dissection courses. Each questionnaire included questions about the medical equipment the surgeons were fitted, and the problems encountered during the dissection. The majority of the participants, regardless of their experience and age, considered uncinectomy and anterior ethmoidectomy as the simplest parts of the dissection, whereas the most complicated step was the approach to the frontal sinus. All participants considered the dissection course as a useful way to improve their medical skills while performing an endoscopic surgery procedure, such as their anatomical knowledge, and confidence with instrumentation and the dissection. Sinonasal dissection courses can be considered to be useful for both trainees and trained surgeons. Improving anatomical knowledge can reduce the occurrence of complications, especially in endoscopic surgery.

KEY WORDS: endoscopic sinus surgery, functional endoscopic sinus surgery, fess, dissection course, surgery

RIASSUNTO

I corsi di chirurgia endoscopica naso-sinusale sono rivolti sia a giovani specialisti per il training chirurgico, sia a chirurghi più esperti per migliorare le abilità chirurgiche. Ad un totale di centotrenta (130) partecipanti, ad 8 corsi di dissezione in totale, tra il 2013 e il 2019, è stato somministrato un questionario strutturato standardizzato, comprendente domande sulla strumentazione ricevuta e problemi riscontrati durante la pratica di dissezione.L'uncinectomia e l'etmoidectomia anteriore sono state considerate le procedure più semplici del corso, dalla maggior parte dei partecipanti, mentre l'approccio al seno frontale, indipendentemente dall'esperienza e dall'età, è stato ritenuto il passaggio più complicato. Tutti i partecipanti hanno considerato il corso di dissezione come un mezzo utile per migliorare le loro conoscenze anatomiche, ed il grado di confidenza con la strumentazione e con la dissezione. I corsi di chirurgia endoscopica naso-sinusale sono stati ritenuti utili sia dai giovani specialisti, che dai chirurghi più esperti. Il miglioramento delle conoscenze anatomiche può ridurre efficacemente l'insorgenza di complicazioni indesiderate, in particolare per gli approcci endoscopici.

PAROLE CHIAVE: *chirurgia endoscopica dei seni paranasali, corsi di dissezione, chirurgia*

Received: February 24, 2020
Accepted: May 30, 2020

Correspondence
Andrea Ciorba
ENT & Audiology Unit, Department of Neuroscience and Rehabilitation, University Hospital of Ferrara, via Aldo Moro 8, 44124 Ferrara, Italy
Tel. +39 0532 239745
E-mail: andrea.ciorba@unife.it

Funding
None.

Conflict of interest
The Authors declare no conflict of interest.

How to cite this article: Pagella F, Emanuelli E, Benazzo M, et al. Are sinonasal dissection courses a valid instrument for endoscopic sinus surgeons? A report on 7-years of experience. Acta Otorhinolaryngol Ital 2020;40:415-420. https://doi.org/10.14639/0392-100X-N0705

© Società Italiana di Otorinolaringoiatria e Chirurgia Cervico-Facciale

OPEN ACCESS

This is an open access article distributed in accordance with the CC-BY-NC-ND (Creative Commons Attribution-Non-Commercial-NoDerivatives 4.0 International) license. The article can be used by giving appropriate credit and mentioning the license, but only for non-commercial purposes and only in the original version. For further information: https://creativecommons.org/licenses/by-nc-nd/4.0/deed.en

Introduction

Sinonasal dissection courses are nowadays an established and fundamental part of the training of ENT surgeons, especially for those who are approaching Endoscopic Sinus Surgery (ESS). These courses are important because of the lack of anatomic facilities or valid simulation tools, and because of the difficult access to specimens related to a number of issues (such as cultural, religious, legal restrictions) [1,2]. Sinonasal dissection courses are able to allow: (i) understanding of the surgical anatomy; (ii) perception of the difficulties and complications that are likely to be encountered by surgeons, which must be handled promptly; (iii) improvement of confidence with the endoscopes [3]. Dissection courses usually begin with a theoretical explanation of the surgical anatomy of paranasal sinuses and surrounding structures, following by hands-on training on cadavers. Dissection courses have been shown to be effective in teaching sinonasal anatomy to trainees, as well as in improving surgical skills of trained surgeons and reducing the occurrence of complications during an ESS procedure [4-6]. Nowadays, the reported risk of complications during an ESS procedure ranges from 4 to 17% [7]. This percentage is composed of 5% minor complications, and 0.5-1% of major complications [8], including orbit injures, I and II cranial nerves, vascular structures (i.e. internal carotid artery, ethmoidal artery) [9].

The aim of this paper is to describe the strengths and weaknesses of sinonasal dissection courses during surgical training for sinonasal surgery, through the evaluation of questionnaire responses given to participants.

Materials and methods

One hundred and thirty participants attended a total of 8 sinonasal dissection courses between 2013 and 2019 in two different Italian cities (Arezzo and Verona), and all received a standardised structured questionnaire. Each questionnaire included questions about the medical instrumentation the participants were fitted, and the problems encountered during the dissection or dissection practice.

Each dissection course had a duration of three days; each day included an introductive theoretical part and hands-on training on cadavers.

The introductive theoretical part addressed the following topics: rhinosinusal surgical and radiological anatomy of the anterior and posterior compartments; anatomy of the lacrimal pathway and orbit, anatomy of the sellar region, pterygopalatine fossa and the cranial base as well as the vascular anatomy; risks of endoscopic sinus surgery (ESS) and extended endoscopic endonasal approaches.

Each dissection step was displayed in a short video of the same procedure. The surgical steps included uncinectomy and maxillary antrostomy, access to the maxillary sinus via canine fossa, identification of the ethmoid infundibulum, the frontal recess and the natural frontal sinus ostium, removal of the ethmoidalis bulla, identification of the basal lamella and the superior turbinate, and opening of the sphenoid ostium.

The participants then performed hands-on dissections: anterior and posterior ethmoidectomy; sphenoidotomy (paraseptal and transethmoid pathway); orbital decompression; sphenopalatine artery identification. The participants also performed endoscopic medial maxillectomy, access to the sellar and parasellar region and repair techniques for cranial base defects.

A structured questionnaire was handed out to the participants at the end of each course, and they were asked to fill it out anonymously (see also Fig. 1 for the questionnaire).

Statistical analysis

Data were analysed using SPSS Statistics 17.0 (SPSS Inc., Chicago, IL, USA). Levels of significance were: $p < 0.1^{*}$; $p < 0.05^{**}$; n.s.: not statistically significant.

Results

A total of 130 structured questionnaires were submitted to the participants. The average age of participants was 38 years (range 27-62 years), and on average they had been practicing ENT for 8.8 years (range 0-35 years). Since the questionnaire was performed anonymously, we could not retrieve information about the M/F ratio.

18% of participants declared problems with the instrumentation, mostly due to the lack of specific instruments or because of malfunctioning instruments.

15.5% of participants declared problems with anatomy, mainly due to a scarce confidence with anatomy and/or little experience; only a few participants had problems with the dissection, due to lack of experience, difficulty of the surgical task (such as skull base approach), or poor manual skills.

11.7% had problems during the dissection (either due to inexperience or due to performing difficult dissection steps, such as the skull base approach; either due to scarce confidence with the anatomy or poor manual ability with instruments).

The results concerning specific dissection steps were also analysed:

- 2.3% declared problems with uncinectomy;
- 2.3% declared problems with anterior ethmoidectomy;
- 27.9% declared problems with posterior ethmoidectomy (the participants complained problems such as the pres-

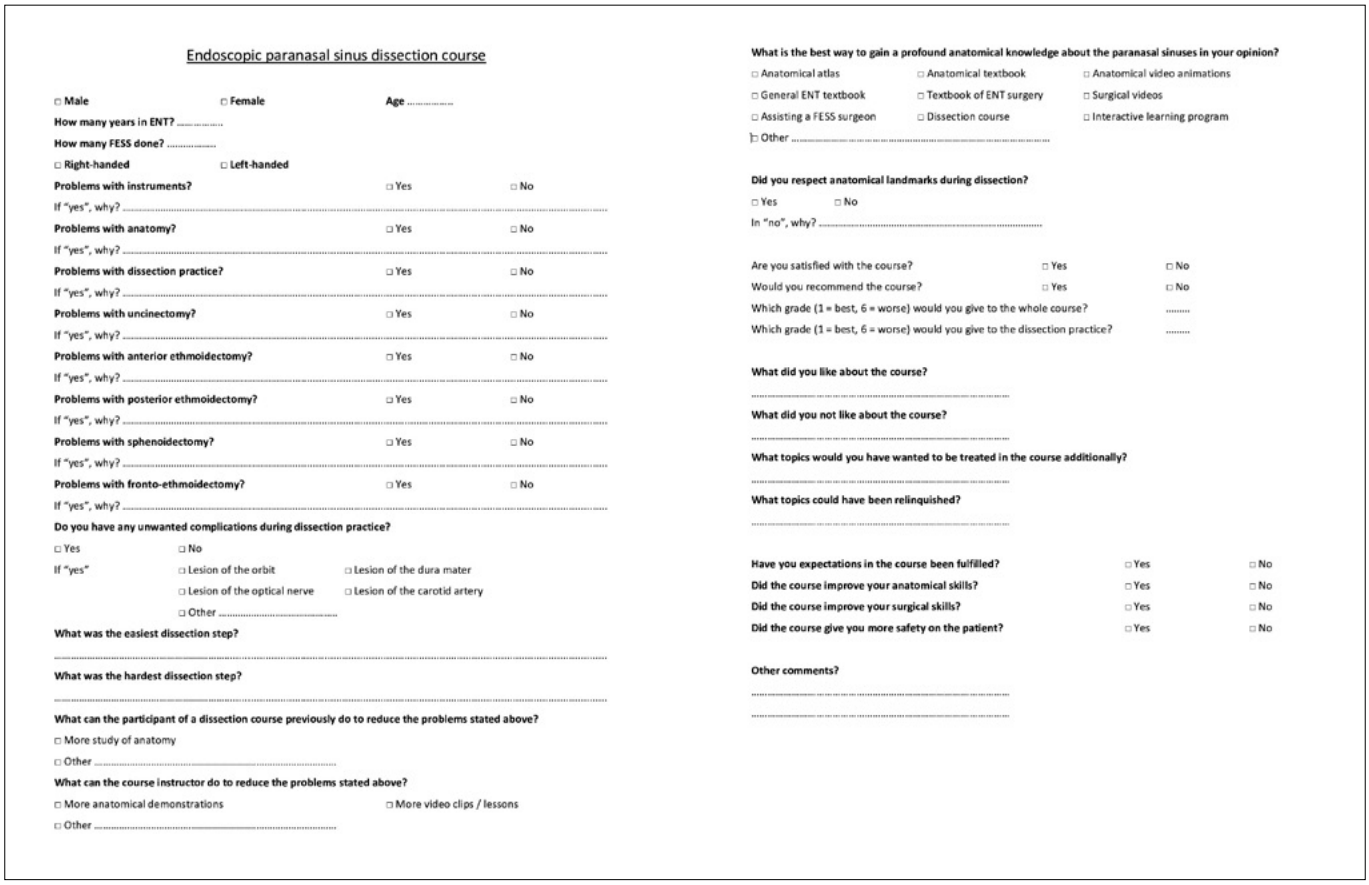

Endoscopic paranasal sinus dissection course

□ Male □ Female Age .....

How many years in ENT? .....

How many FESS done? .....

□ Right-handed □ Left-handed

Problems with instruments? □ Yes □ No

If "yes", why? .....

Problems with anatomy? □ Yes □ No

If "yes", why? .....

Problems with dissection practice? □ Yes □ No

If "yes", why? .....

Problems with uncinectomy? □ Yes □ No

If "yes", why? .....

Problems with anterior ethmoidectomy? □ Yes □ No

If "yes", why? .....

Problems with posterior ethmoidectomy? □ Yes □ No

If "yes", why? .....

Problems with sphenoidectomy? □ Yes □ No

If "yes", why? .....

Problems with fronto-ethmoidectomy? □ Yes □ No

If "yes", why? .....

Do you have any unwanted complications during dissection practice?

□ Yes □ No

If "yes" □ Lesion of the orbit □ Lesion of the dura mater

□ Lesion of the optical nerve □ Lesion of the carotid artery

□ Other .....

What was the easiest dissection step?

.....

What was the hardest dissection step?

.....

What can the participant of a dissection course previously do to reduce the problems stated above?

□ More study of anatomy

□ Other .....

What can the course instructor do to reduce the problems stated above?

□ More anatomical demonstrations □ More video clips / lessons

□ Other .....

What is the best way to gain a profound anatomical knowledge about the paranasal sinuses in your opinion?

□ Anatomical atlas □ Anatomical textbook □ Anatomical video animations

□ General ENT textbook □ Textbook of ENT surgery □ Surgical videos

□ Assisting a FESS surgeon □ Dissection course □ Interactive learning program

□ Other .....

Did you respect anatomical landmarks during dissection?

□ Yes □ No

In "no", why? .....

Are you satisfied with the course? □ Yes □ No

Would you recommend the course? □ Yes □ No

Which grade (1 = best, 6 = worse) would you give to the whole course? .....

Which grade (1 = best, 6 = worse) would you give to the dissection practice? .....

What did you like about the course?

.....

What did you not like about the course?

.....

What topics would you have wanted to be treated in the course additionally?

.....

What topics could have been relinquished?

.....

Have you expectations in the course been fulfilled? □ Yes □ No

Did the course improve your anatomical skills? □ Yes □ No

Did the course improve your surgical skills? □ Yes □ No

Did the course give you more safety on the patient? □ Yes □ No

Other comments?

.....

.....

Figure. 1. Structured questionnaire used during the dissection courses.

ence of complex anatomy; two surgeons encountered problems due to lack of landmarks; other surgeons declared difficulties due to lack of knowledge of anatomy and inexperience in dissection; other participants declared difficulties due to the presence of anatomical variants, such as excessive pneumatisation);

- 19.38% declared problems with sphenoidotomy (for the same reasons mentioned above);
- 29.46% declared problems with the access to the fronto-ethmoid (during this dissection step difficulties were referred to the complex anatomy of the frontal sinus, lack of landmarks, wide anatomical variability of this district and also to the troubles in using angled optics).

Most of the surgeons identified and spared anatomical landmarks; however, several complications occurred during the dissection; in particular, 31.5% of the participants encountered unwanted complications during the dissection, such as orbit lesions (14 participants), meningeal lesions (8 participants), vascular lesions, rhinoliquoral fistula (4 participants) and optic nerve lesions (4 participants).

The simplest part of the dissection was reported to be uncinectomy (76.4%), followed by antrostomy (11.8%), anterior ethmoidectomy (9.4%), sphenoidotomy (1.6%) and frontal sinus access (0.8%).

The most difficult part of the dissection was reported to be access to the fronto-ethmoid recess (37.8%), followed by posterior ethmoidectomy (22.7%), sphenoidotomy (15.1%), orbital decompression (9.2%) and DCR (3.4%).

The participants declared that the best way to acquire surgical anatomical knowledge (multiple choice question) was: participation (82.4%); assisting in a surgery performed by a well-trained ENT surgeon (36.8%); studying surgical videos (36%); studying anatomical videos (31.2%); studying anatomic atlases (33.6%); studying ENT books (14.4%); studying anatomy texts (11.2%); using interactive programmes (8.8%); studying other ENT books (8%).

All participants (100%) were eventually satisfied with the course and would all recommend to other colleagues to take part in it.

The overall course evaluation obtained an average score of 1.788 (the range was from 1, maximum score - to 6, mini-

mum score). The overall dissection evaluation obtained an average score of 1.915 (the range was from 1, maximum score - to 6, minimum score).

We then divided the 130 participants into two groups for statistical analysis, setting a cut-off at the age of 40. On average, those aged ≥ 40 were already more experienced in nasal surgery training (see below), according to the participants' declarations within the questionnaire. We therefore tested the hypothesis that the experience is a determining variable for the surgeon's practice.

Fifteen participants did not specify their age in the questionnaire and were excluded. Hence, group 1 consisted of 77 participants (66.95%), aged < 40, with an average ENT practice period of 4.29 years; group 2 consisted of 38 participants (33.05%), aged ≥ 40, with an average ENT practice period of 17.29 years.

Participants who declared problems with using the instruments were 17.1% of group 1 and 15.8% of group 2 (p = 0.86). Participants who declared problems with anatomy were 15.6% of group 1 and 15.8% of group 2 (p = 0.87). Participants who declared dissection problems were 11.7% of group 1, and 13.5% of group 2 (n.s., as p = 0.82) (Tab. I).

Concerning problems encountered while performing different steps (Tab. II):

- uncinectomy and anterior ethmoidectomy: 2.6% of group 1 and 2.7% of group 2 declared problems for uncinectomy; 2.6% of both groups for the anterior ethmoidectomy; p = 0.97 and p = 0.99, respectively;
- posterior ethmoidectomy: 31.2% of group 1 declared problems vs 26.3% of group 2 (p = 0.59);
- sphenoidotomy: 34.2% of those of group 2 declared difficulties in this step, compared to 13% of those of group 1, p = 0.007**;
- fronto-ethmoidectomy: 27.3% of group 2 declared difficulties in performing the dissection, compared to 39.5% of group 1 (n.s, p = 0.18).

In the end, there are no significant differences between the two groups, either related to the total number of unwanted

Table I. Comparison between the overall problems referred by the studied groups.

Problems with the instruments	Yes n./tot (%)	No n./tot
< 40 y.o.	13/76 (17.1%)	63/76
≥ 40 y.o.	6/38 (15.8%)	32/38
Problems with the anatomy		
< 40 y.o.	12/77 (15.6%)	65/77
≥ 40 y.o.	6/38 (15.8%)	32/38
Problems with dissection		
< 40 y.o.	9/77 (11.7%)	68/77
≥ 40 y.o.	5/37 (13.5%)	33/37

Table II. Comparison between the complications declared by the studied groups.

Problems with uncinectomy	Yes n./tot (%)	No n./tot
< 40 y.o.	2/77 (2.6%)	75/77
≥ 40 y.o.	1/37 (2.7%)	36/37
Problems with ant. ethmoidectomy		
< 40 y.o.	2/77 (2.6%)	75/77
≥ 40 y.o.	1/38 (2.6%)	37/38
Problems with post. ethmoidectomy		
< 40 y.o.	24/77 (31.2%)	53/77
≥ 40 y.o.	10/38 (26.3%)	28/38
Problems with sphenoidotomy		
< 40 y.o.	10/77 (13%)	67/77
≥ 40 y.o.	13/38 (34.2%)	25/38
Problems with frontal sinus		
< 40 y.o.	21/77 (27.3%)	56/77
≥ 40 y.o.	15/38 (39.5%)	23/38

complications (p = 0.92), or to the single type of complications reported.
The simplest part of the dissection was uncinectomy for 87.7% of those of group 1, and for 72.2% of those of group 2; uncinectomy was also reported to be an easier step by the younger surgeons, compared to the experienced surgeons.
Other dissection steps, such as antrostomy, anterior ethmoidectomy, sphenoidotomy, did not show significant differences between the two groups. Lastly, 1.4% of participants in group 1 considered access to the frontal sinus as the simplest step, which was not mentioned by any surgeon in group 2.
The opposite question was asked to participants: "What was the most difficult part of the dissection?", 30% of those of group 1 considered the posterior ethmoid as the most complex procedure, against 14.3% of the second group (p = 0.09 *). The sphenoid was voted as the most complex procedure by the 8.6% of those of group 1 and by the 22.8% of those of group 2 (p = 0.06 *).
In the end, 89.6% of those of group 1 declared the dissection course to be the best way to acquire the surgical anatomical knowledge, compared to the 71.4% of those in group 2 (p = 0.02 *).

Discussion

ESS is now widely used by ENT specialists around the world to treat inflammatory conditions, malformations and neoplastic diseases of the nasal cavities and paranasal sinuses. The first steps of ESS are linked to the names of Messerklinger, Stammberger and Storz [1]; they allowed replacing the previous open technique with considerable advantages from prognostic, surgical and therapeutic points of view [2-5].
ESS represents the best surgical technique for the treatment of nasal cavities and paranasal sinus diseases, which is among the most highly complex and variable anatomical districts of the human body. One limitation is represented by the two-dimensional vision of the optics, which does not allow the depth perception. Anatomical variability of sinuses and potential severe complications (vascular, cerebral as well as neurological) related to this surgery should be however taken in account when dealing with ESS. For these reasons, knowledge of the anatomy of this district is a fundamental prerequisite for safely dealing with the technique.
Sinonasal dissection courses are nowadays a mandatory part of the ENT surgeon training, and are even attended by trained surgeons, in order to improve skills in procedures on anatomic variants [1,2]. Based on other experiences (Braun et al. [10]), the participants were divided into two groups according to their age and experience (as declared on the questionnaires), in order to evaluate the problems arising at different levels of surgical practice, and along the learning curve.
Through the evaluation of the data from our study, those in group 1 (younger surgeons) mainly reported difficulties due to the scarce manual ability and because of the presence of an anatomical variant (i.e. excessive pneumatisation).
The analysis highlighted that most of the participants at our sinonasal courses were < 40 years of age (66.95%). It is possible that young surgeons approaching ESS are attracted by many reasons such as: (i) the possibility of learning sinonasal surgical anatomy safely; (ii) the opportunity of improving their confidence with endoscopes, and particularly with angled optics. In many hospitals' ordinary routines, young surgeons have usually a lower chance of performing sinonasal surgery as first operator than experienced surgeons; attending dissection courses can therefore improve their skills in a safe way.
It is interesting to notice that, according to the results of the study by Braun and Betz [10], our study also showed that: uncinectomy and anterior ethmoidectomy represented the simplest parts of the dissection, regardless of experience and age, whereas the most complicated step was considered to be the approach to the frontal sinus for all the groups.
Concerning sphenoidotomy, it is possible that the differences among the groups are caused by different approaches to this step: young surgeons just performed the minimal/essential approach to the sphenoid sinus, whereas trained surgeons performed a complete and functional opening, which exposes to greater risks and complications.
In the end, no differences were observed between the two groups, neither concerning the total occurrence rate of unwanted complications, nor considering the types of unwanted complications that can occur during the dissection. Despite this, just 31.5% of all participants experienced a minor or major complication, and thus it is possible to state that constant practice and exercise are efficient ways to improve ones expertise, reducing the occurrence of complications for the surgeon approaching ESS surgery and for trained surgeons as well.
There is no commercially available simulator for ESS that is particularly successful in simulating the anatomy with force feed-back so far, as opposed to other areas; a number have been described, but none are available [4,12,13]. Participating in a cadaver course is nonetheless a must in training young surgeons, especially to improve manual abilities in a safe way [4,12,13], despite difficult access to specimens related to a number of issues (such as cultural, religious, legal restrictions) [4,12-14].

Conclusions

In conclusion, the authors believe that hands-on courses are beneficial and satisfactory for both younger and trained surgeons, and all the participants were satisfied with the

course and would all suggest to other colleagues to participate in future courses. The authors are also willing to improve the questionnaire for future courses, and will try to evaluate which skill is considered to be the most improved by each participant during the course.

References

1. Tajudeen BA, Kennedy DW. Thirty years of endoscopic sinus surgery: what have we learned? World J Otorhinolaryngol Head Neck Surg 2017;21:115-21. https://doi.org/10.1016/j.wjorl.2016.12.001
2. Ahmed OH, Marcus S, Lebowitz RA, et al. Evolution in visualization for sinus and skull base surgery. Otolaryngol Clin North Am 2017;50:505-19. https://doi.org/10.1016/j.otc.2017.01.003
3. Ogino-Nishimura E, Nakagawa T, Sakamoto T, et al. Efficacy of three-dimensional endoscopy in endonasal surgery. Auris Nasus Larynx 2015;42:203-7. https://doi.org/10.1016/j.anl.2014.10.004
4. Zuckerman JD, Wise SK, Rogers GA, et al. The utility of cadaver dissection in endoscopic sinus surgery training courses. Am J Rhinol Allergy 2009;23:218-24. https://doi.org/10.2500/ajra.2009.23.3297
5. Phillips JS, Vowler SL, Salam MA. Is training in endoscopic sinus surgery detrimental to patient outcome? J Surg Educ 2007;64:278-81. https://doi.org/10.1016/j.jsurg.2007.07.003
6. McMains KC. Safety in endoscopic sinus surgery. Curr Opin Otolaryngol Head Neck Surg 2008;16:247-51. https://doi.org/10.1097/MOO.0b013e3282fdccad
7. Ulualp SO. Complications of endoscopic sinus surgery: appropriate management of complications. Curr Opin Otolaryngol Head Neck Surg 2008;16:252-9. https://doi.org/10.1097/MOO.0b013e3282fdc3b2.
8. Solyar A, Cuellar H, Sadoughi B, et al. Endoscopic sinus surgery simulator as a teaching tool for anatomy education. Am J Surg 2008;196:120-4. https://doi.org/10.1016/j.amjsurg.2007.06.026
9. Ramakrishnan VR. Ergonomics in endoscopic sinus surgery. Curr Opin Otolaryngol Head Neck Surg 2019;27:25-8. https://doi.org/10.1097/MOO.0000000000000504
10. Braun T, Betz CS, Ledderose GJ, et al. Endoscopic sinus surgery training courses: benefit and problems - a multicentre evaluation to systematically improve surgical training. Rhinology 2012;50: 246-54. https://doi.org/10.4193/Rhino11.266
11. Ossowski KL, Rhee DC, Rubinstein EN, et al. Efficacy of sinonasal simulator in teaching endoscopic nasal skills. Laryngoscope 2008;118:1482-5. https://doi.org/10.1097/MLG.0b013e3181772d4f
12. Laeeq K, Lin SY, Varela DA, et al. Achievement of competency in endoscopic sinus surgery of otolaryngology residents. Laryngoscope 2013;123:2932-4. https://doi.org/10.1002/lary.23509
13. Bakker NH, Fokkens WJ, Grimbergen CA. Investigation of training needs for functional endoscopic sinus surgery (FESS). Rhinology 2005;43:104-8.
14. Alicandri-Ciufelli M, Marchioni D, Pavesi G, et al. Acquisition of surgical skills for endoscopic ear and lateral skull base surgery: a staged training programme. Acta Otorhinolaryngol Ital 2018;38:151-9. https://doi.org/10.14639/0392-100X-1878

ACTA OTORHINOLARYNGOLOGICA ITALICA 2020;40:421-425; doi: 10.14639/0392-100X-N0679

Rhinology

Effectiveness of superior eyelid endoscopic-assisted approach in the management of selected orbital abscess: considerations on 4 cases

Ruolo dell'approccio trans-palpebrale superiore endoscopico-assistito nella gestione delle complicanze infettive orbitarie multicompartimentali: considerazioni su 4 casi clinici

Iacopo Dallan, Lodovica Cristofani-Mencacci, Christina Cambi, Mariella Scarano, Augusto Pietro Casani, Veronica Seccia
Otorinolaringoiatria Audiologia e Foniatria, Azienda Ospedaliero-Universitaria Pisana, Pisa, Italy

SUMMARY
Orbital abscess is one of the most serious complications of acute rhinosinusitis and requires surgical management to avoid further complications such as visual loss and intracranial extension of the infectious process. Endoscopic sinus surgery is the most frequently used procedure in such cases, even if its use may be insufficient in some cases. The aim of the present study is to present our experience on the management of selected orbital abscesses through a superior eyelid endoscopic approach in combination with endonasal surgery. Personal considerations on four cases and lessons learned are described.

KEY WORDS: abscess, sinusitis, rhinitis, orbital cellulitis, endoscopy

RIASSUNTO
Gli ascessi dell'orbita rappresentano una delle più temibili complicanze in corso di rinosinusite acuta. La loro gestione è di tipo chirurgico nella maggior parte dei casi, con l'obiettivo di drenare la raccolta ed evitare l'evoluzione verso quadri ancora più seri che possano comportare la perdita della vista o l'estensione intracranica del processo infettivo. L'approccio chirurgico più frequentemente utilizzato è rappresentato dalla chirurgia endoscopica dei seni paranasali, pur risultando in alcuni casi insufficiente. Lo scopo del presente studio è quello di presentare la nostra esperienza nell'utilizzo dell'approccio trans-palpebrale superiore in combinazione con la via endoscopica endonasale classica nella gestione di casi selezionati di ascessi orbitari.

PAROLE CHIAVE: *ascesso, sinusite, rinite, cellulite orbitaria, endoscopia*

Received:February 11, 2020
Accepted: May 20, 2020

Correspondence
Lodovica Cristofani Mencacci
Otorinolaringoiatria Audiologia e Foniatria, Azienda Ospedaliero-Universitaria Pisana, via Paradisa 2, 56124 Pisa, Italy
Tel. +39 050 997501
E-mail: lodovicacristofani@yahoo.it

Funding
None.

Conflict of interest
The Authors declare no conflict of interest.

How to cite this article: Dallan I, Cristofani-Mencacci L, Cambi C, et al. Effectiveness of superior eyelid endoscopic-assisted approach in the management of selected orbital abscess: considerations on 4 cases. Acta Otorhinolaryngol Ital 2020;40:421-425. https://doi.org/10.14639/0392-100X-N0679

© Società Italiana di Otorinolaringoiatria e Chirurgia Cervico-Facciale

OPEN ACCESS

This is an open access article distributed in accordance with the CC-BY-NC-ND (Creative Commons Attribution-Non-Commercial-NoDerivatives 4.0 International) license. The article can be used by giving appropriate credit and mentioning the license, but only for non-commercial purposes and only in the original version. For further information: https://creativecommons.org/licenses/by-nc-nd/4.0/deed.en

Introduction

Infectious orbital complications may occur secondary to acute rhinosinusitis, when pathogens spread from an infected sinus into the orbit. It may happen directly, given the close proximity of the orbit to the paranasal sinuses, or indirectly via the bloodstream. Chandler's classification for orbital complications of sinusitis distinguishes five stages on the basis of involvement of the orbital content [1]. Conservative management is possible in earlier Chandler's stages, while surgical drainage is indicated in later stages or in cases of failure to improve under medical treatment. The Chandler's IV stage is represented by an orbital abscess, in which purulent secretions are described within the orbital content, deep to the periorbita. Patients experience proptosis, chemosis, orbital pain and progressive ophthalmoplegia and, if not promptly treated, visual impairment and visual loss [1]. In this group of patients, surgical management is highly recommended in order to drain the abscess, release pressure in

the orbit, obtain material for culture and reduce the risk of intracranial extension, including cavernous sinus thrombosis, meningitis, cerebritis and cerebral abscess (Chandler's stage V) [2]. Endoscopic sinus surgery is the most frequently used procedure even if its use may be insufficient when dealing with areas that are complex to treat. In other words, the effectiveness of endonasal procedures depends on the location of the disease within the orbit, eventually requiring the association with or the necessity to switch to other approaches.

The aim of the present study is to present our experience on management of selected orbital abscesses through a superior eyelid endoscopic approach in combination with endonasal surgery. Personal considerations and lessons learned are described.

Materials and methods

In this retrospective cohort study, we report our experience with four adult patients treated with a superior eyelid transorbital endoscopic approach in combination with endonasal surgery for rhinogenic orbital abscesses at the University Hospital of Pisa between July 2016 and March 2019. Patients treated with an exclusive endonasal approach were not considered. Data collected included demographic, known history of chronic rhinosinusitis, previous nasal or orbital surgical procedures, ongoing medical treatments. All patients underwent a pre-operative eye examination and CT scan to evaluate orbital involvement (Fig. 1). All patients provided informed written consent for the procedure. Patients were selected for a superior eyelid endoscopic approach in combination with endonasal endoscopic surgery based on the location of the abscess within the orbit. In other words, the main criterion to indicate the need for a superior-eyelid approach was the location of the abscess in the supero-lateral orbital quadrant. Surgical procedures performed, hospitalisation days and complications were analysed. No statistical evaluations were performed due to the low number of patients.

Notes on surgical technique

The transnasal approach consisted in subtotal resection of the middle turbinate; complete spheno-etmoidectomy; exposure and removal of the lamina papyracea; periorbital exposure and opening and eventually extraconal fat management and drainage of the abscess. The transorbital approach was performed via superior eyelid incision and included identification of the orbicolaris oculi muscle; harvesting of the suborbicolaris flap and dissection until the orbital rim; dissection of the periorbita from the orbital bones and creation of enough room for instrumentation; incision of the

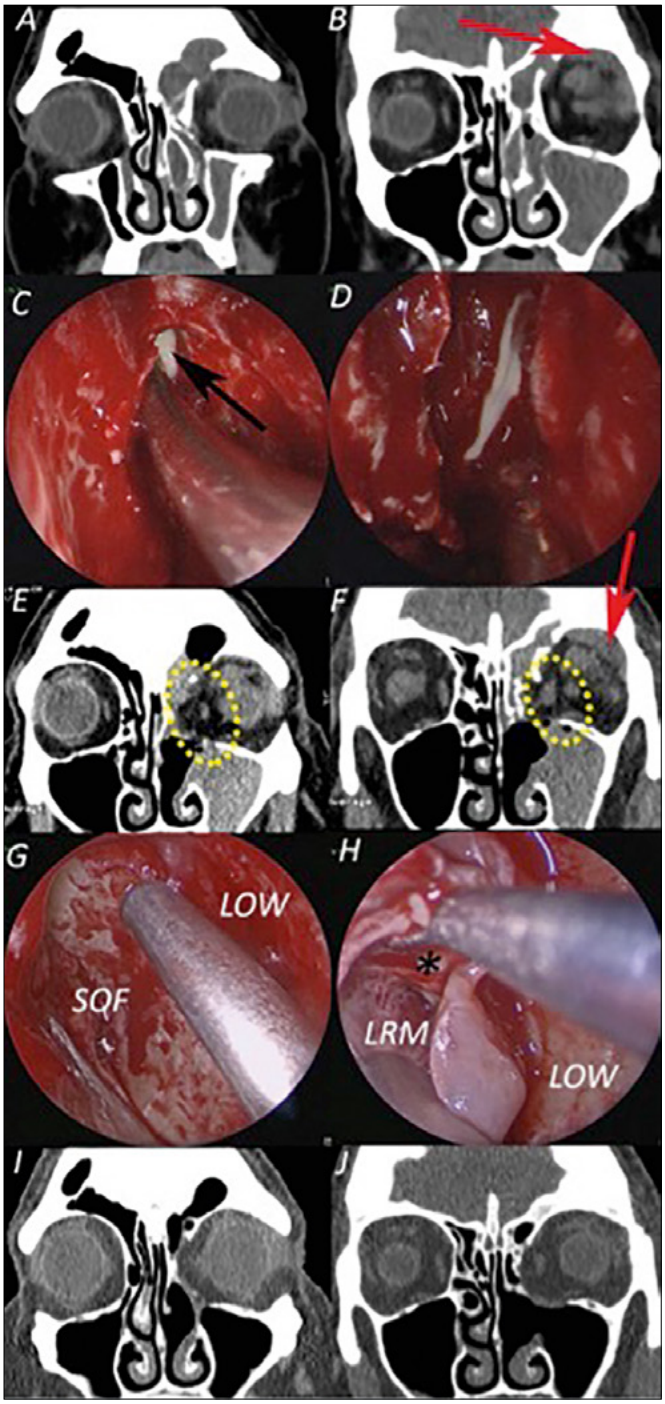

Figure 1. Radiological and endoscopic images describing the time evolution of the orbital abscess in patient number 1. Radiological evidence of a left acute rhinosinusitis (**A**, **B**). Red arrow show orbital roof dehiscence with involvement of the supero-lateral orbital compartment. Endoscopic evidence of pus during the endonasal surgical approach (black arrow in **C**, **D**). Post-operative radiological images showing adequate surgical outcomes of a complete ethmoidectomy with orbital decompression (**E**, **F**). Red arrow shows the persistence of the supero-lateral orbital abscess. Endoscopic images of the transorbital surgical approach (**G**, **H**). LOW: left orbital wall; SOF: superior orbital fissure; LRM: left rectus muscle; * shows the pus. Post-op radiological images showing adequate surgical outcome and complete resolution of the orbital abscess (**I**, **J**).

periorbita and dissection within the orbital fat till abscess is reached. Drainage of the abscess was performed according to individual requirements. The drain was removed the day after surgery. Neuronavigation was used to confirm the exact position of the abscess and to help the surgeon identify the abscess.

Results

Four adult patients affected by sinogenic orbital abscess were treated with a combined transnasal-transorbital endoscopic surgical procedure. Our cohort was formed by 3 males and 1 female, with a mean age of 39.75 ± 25 years. All patients presented acute rhinosinusitis with acute onset of orbital symptoms. Two patients had a known history of chronic rhinosinusitis, managed with topical steroids and in one patient with previous surgery. All patients were on antibiotic therapy when they came to our attention. Clinical details of the patients are reported in Table I. All patients presented a Stage IV Chandler's classification for acute rhinosinusits complications, as revealed by pre-operative radiological evaluation. At pre-operative eye examination, all patients presented chemosis, proptosis and orbital pain; two patients presented visual impairment: deep reduction of visual acuity in patient # 1; blindness in patient # 2 (Tab. II).

Surgery was represented by a combined transnasal-transorbital approach in three of four patients; one patient was treated transnasally and transorbitally at different times (patient # 1). Patient # 4 developed an asymptomatic epidural abscess in the post-operative period that was successfully treated with medical therapy in the infectious diseases ward. Long-term sequalae occurred in patient # 2 in terms of lack of improvement of blindness. All perioperative details are reported in Table III.

Discussion

Orbital abscess is one of the most frightening complications of acute rhinosinusitis and should be considered a very serious condition with possible permanent sequelae. In case of orbital abscesses, surgery should become rapidly advisable, although conservative management could be attempted in selected adult patients with limited subperiosteal

Table I. Clinical details of our cohort of patients.

Patient number	Sex, Age (years)	Known CRS	Previous surgery	Days from onset of ARS	Ongoing antibiotic treatment
1	F, 75	Y	N	9	Amox/Clav Ac.
2	M, 40	Y	Y	6	Cefixime-Amox/Clav. Ac.
3	M, 27	N	N	1	Amox/Clav. Ac.
4	M, 18	N	N	9	Levoflox-Ceftriaxone

M: male; F: female; Known CRS: known history of chronic rhinosinusitis; Days from onset of ARS: days between onset of acute rhinosinusitis and onset of orbital symptoms; Amox/Clav. Ac.: Amoxicillin/Clavulanic Acid; Levoflox: Levofloxacin

Table II. Ocular symptoms.

Patient number	Chemosis	Proptosis	Visual impairment	Ocular motility impairment	Orbital pain
1	Y	Y	Y, 1/10	Y	Y
2	Y	Y	Y, 0/10	Y	Y
3	Y	Y	N, 8/10	Y	Y
4	Y	Y	N, 10/10	N	Y

Table III. Perioperative details, complications and sequalae in our cohort.

Patient number	Surgery performed	Days of hospitalisation	Post-op CT scan	Second surgery	Short-term sequalae	Long-term sequalae
1	Transnasal	10	OA	Y, Transorb	N	N
2	Combined	6	Neg	N	Blindness	Blindness
3	Combined	10	Neg	N	N	N
4	Combined	Other dept.	EA	N	N	N

Transnasal: Transnasal endoscopic surgery; Combined: Transnasal-transorbital endoscopic surgery; Transorb: Transorbital endoscopic surgery; Other dept: moved to other department; OA: orbital abscess; Neg: negative for persistence of abscess or other complication; EA: Epidural abscess

abscesses [3]. Time is typically a critical factor, and, in such "conservative" cases, patients need to be closely monitored in order to avoid possible evolution and thus serious complications [4]. Technically speaking, most of subperiosteal abscesses can be managed transnasally. This is not always true in all cases of orbital abscesses. Thus, if endoscopic endonasal surgery is adequate in most cases, with the aim of opening the sinuses involved, removing pus, allowing direct cultures and providing a drainage pathway, this approach may be insufficient in cases of abscesses involving the supero-lateral orbital compartments. These orbital areas are normally involved due to spread of infection, although septic emboli may occur [5]. Hence, in suspected orbital abscesses orbital imaging becomes mandatory to confirm the suspicion and to choose the most appropriate approach. If MRI with contrast is the best option to evaluate orbital lesions, it is quite clear that examination is rarely available in such an urgent situation. Therefore, the vast majority of these cases have to be managed using CT, if possible using a contrast agent. We strongly advise, in such a scenario, to prefer the rapidity of action in respect to searching for the best imaging examination. Since most orbital abscesses are related to acute rhinosinusitis, we consider, as stated before, that the endonasal approach should be the first procedure to be performed in order to drain the purulence and restore ventilation to the sinuses [3]. On the other hand, there are clear limitations for an exclusive endonasal approach in managing selected sinogenic orbital complications, especially in case of supero-lateral or lateral abscesses. In these cases, transnasal approaches offer an unfavourable path-to-target trajectory, while other routes, like the superior eyelid approach, could be more efficient. Practically speaking, in these complex cases, it could be necessary to combine endonasal and transorbital approaches, and this is what we did in our patients. We normally move first with a transnasal approach and then a transorbital approach if a supero-lateral abscess is demonstrated by imaging. In our first case, imaging seemed to show a sub-periosteal abscess extending from the medial orbital compartment to the superior ones. Thus, we performed, as a first surgical procedure, an exclusive transnasal approach, although intraoperatively, sub-periosteally, there was only a limited amount of infected material. At post-operative CT, an abscess was still demonstrated in the supero-lateral orbital compartment, thus requiring a further surgical procedure via superior eyelid (Fig. 1). Since that time, we shifted to a combined procedure in case of supero-lateral orbital involvement. The effectiveness of the superior eyelid approach in the setting of intraorbital abscesses has been previously reported by other authors [5]. In fact, the superior eyelid approach is not thought to replace transnasal or other approaches, but rather to serve as a complementary tool to help the surgeon when facing challenging areas. Despite the high-risk anatomic location of the abscesses in our series, we have documented the feasibility and excellent safety profile of the superior eyelid approach. All abscesses were successfully reached and drained as intended (Fig. 2). In our series there were no new visual deficits, worsened diplopia, or ptosis.

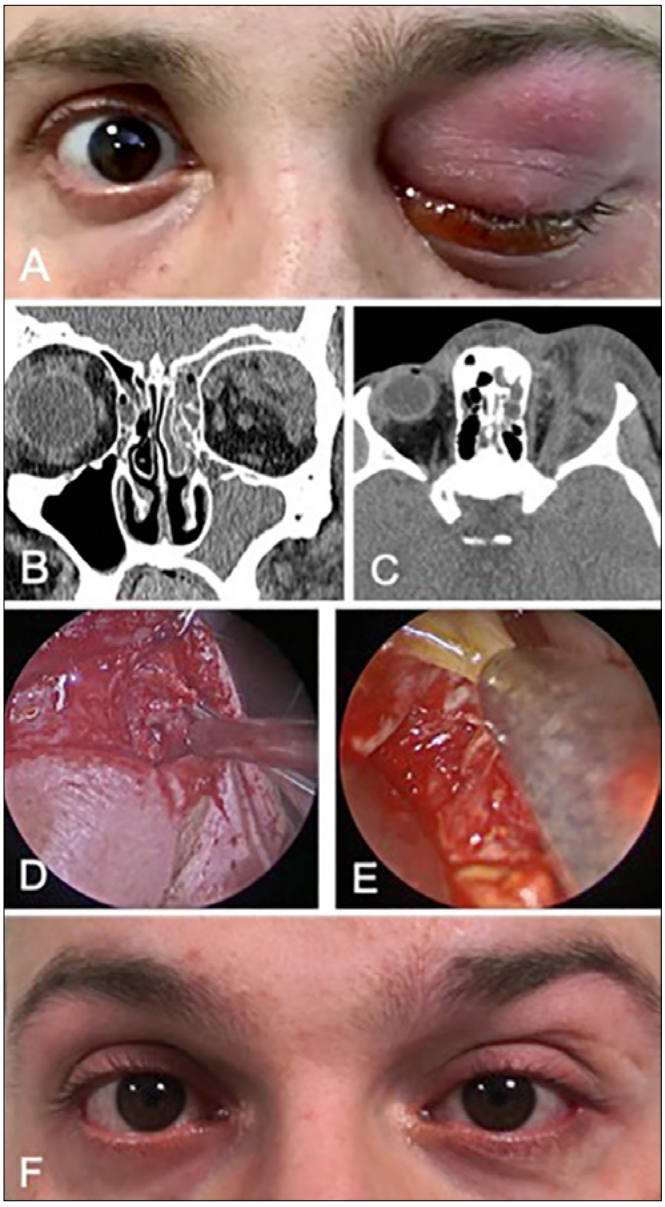

Figure 2. Clinical, radiological and surgical images of a left orbital abscess. Clinical presentation with significant proptosis, chemosis and inability to open the eye (**A**). Coronal and axial CT scan images showing the left orbital involvement in the context of a left acute rhinosinusitis (**B**, **C**). Endoscopic evidence and drainage of pus during the transorbital approach (**D**, **E**). Post-operative image showing complete resolution of the proptosis and chemosis. There is no evidence of enophthalmos (**F**).

Additionally, we did not experience unfavourable wound healing, eyelid distortion, or poor cosmetic outcomes associated with the superior eyelid incision. Patient # 2 in our cohort unfortunately experienced permanent vision loss, which was likely related to delayed surgery (about 24 hours after onset). This patient was blind before surgery and vision did not recover. Although anecdotical, this stresses the importance of rapid management of such abscesses, considering that delayed surgery may be associated with a reduced chance of visual recovery and an increased risk of intracranial complications. In this context, secondary vascular damage (mostly venous related) of minor but critical orbital vessels could be responsible of the dramatic worsening of the vision. Lastly, in our opinion, the transorbital route should be considered a minimally invasive, safe and effective approach to be further developed in combination with transnasal surgery. Its role in the management of orbital abscess should be considered based on the site and features of the abscess by CT. On these grounds, the transorbital endoscopic approach may overcome the limits of the transnasal route, providing improved visualisation and access to challenging anatomical areas. From a clinical point of view, we strongly advise careful and rapid evaluation of this patients, and if a supero-laterally located abscess is suspected a combined transnasal-transorbital procedure should be considered.

Conclusions

We present the transorbital endoscopic approach as an effective route to use in combination with the transnasal approach in cases of orbital abscess that involve multiple, not-necessarily-communicating compartments. More practically, the involvement of the supero-lateral compartment is a strong recommendation for the superior eyelid approach. In this scenario, only accurate pre-operative radiological evaluation will allow choice of the most appropriate surgical route.

References

1. Chandler JR, Langenbrunner DJ, Stevens ER. The pathogenesis of orbital complications in acute sinusitis. Laryngoscope 1970;80:1414-28. https://doi.org/10.1288/00005537-197009000-00007
2. Howe L, Jones NS. Guidelines for the management of periorbital cellulitis/abscess. Clin Otolaryngol Allied Sci 2004;29:725-8. https://doi.org/10.1111/j.1365-2273.2004.00889.x
3. Gavriel H, Jabrin B, Eviatar E. Management of superior subperiosteal orbital abscess. Eur Arch Otorhinolaryngol 2016;273:145-50. https://doi.org/10.1007/s00405-015-3557-1
4. Harris GJ. Subperiosteal abscess of the orbit: older children and adults require aggressive treatment. Ophthalmic Plast Reconstr Surg 2001;17:395-7. https://doi.org/10.1097/00002341-200111000-00002
5. Lim JH, Sardesai MG, Ferreira M Jr, et al. Transorbital neuroendoscopic management of sinogenic complications involving the frontal sinus, orbit, and anterior cranial fossa. J Neurol Surg B Skull Base 2012;73:394-400. https://doi.org/10.1055/s-0032-1329617

ACTA OTORHINOLARYNGOLOGICA ITALICA 2020;40:426-434; doi: 10.14639/0392-100X-N0566

Rhinology

Structural changes in the extracellular matrix after cross-linking of nasal polyp tissue

Cambiamenti strutturali della matrice extracellulare dopo cross-linking del tessuto polipoide nasale

Nathalia Coronel[1*], Rogério Pezato[1*], Jônatas Bussador do Amaral[1], Leandro Ticlia[2], Thiago Freire Pinto Bezerra[3], Lígia Ferreira Gomes[2], Juliana Dreyfuss[4], Wallace Chamon[5,6], Luiz Carlos Gregório[1]

[1] ENT Research Laboratory, Department of Otolaryngology-Head and Neck Surgery, Federal University of Sao Paulo, Sao Paulo, Brazil; [2] Laboratory of Microrheology and Molecular Physiology, Institute of Physics, University of São Paulo-USP, São Paulo, SP, Brazil; [3] Department of Otolaryngology, Federal University of Pernambuco-UFPE, Recife, PE, Brazil; [4] Department of Biochemistry, Federal University of São Paulo-Unifesp, São Paulo, SP, Brazil; [5] Department of Ophthalmology and Visual Sciences, Federal University of São Paulo-Unifesp, São Paulo, SP, Brazil; [6] Department of Ophthalmology and Visual Sciences, College of Medicine, University of Illinois at Chicago, Chicago, IL, United States

[*] N. Coronel and R. Pezato contributed equally to this work.

SUMMARY

Chronic rhinosinusitis with nasal polyposis is a disease characterised by a mechanical dysfunction that facilitates anomalous growth of the nasal mucosa, due to its unique remodelling process. The development of procedures capable of interfering with this process is thus of the utmost importance. This study deals with the evaluation of the effects of cross-linking upon the nasal polyp tissue extracellular matrix. Six patients undergoing surgery for polypectomy were selected. The riboflavin/UVA collagen cross-linking technique was applied to the surface of epithelialised and de-epithelialised resected polyps of the intervention group. The control group polyps were not submitted to cross-linking procedures. Ultrathin polyp tissue sections (8 µm) were processed for immunofluorescence with mouse anti-type I collagen antibody and AlexaFluor 488 conjugated secondary antibody plus DAPI counterstaining, and analysed by confocal microscopy. The effect of riboflavin/UVA collagen cross-linking was visible on confocal fluorescence microscopy. Quantitative morphology was associated with fluorescence imaging analysis, and pixel density and brightness were evaluated. The surface of treated polyps exhibited a higher density of collagen fibres compared to control polyps, as could be observed both visually and through objective measurements of the fluorescent regions. The effect was enhanced on the surface of the de-epithelialised polyps. The higher density of collagen fibres exhibited by the de-epithelialised treated polyps demonstrates the feasibility of this technique in interfering with the remodelling process and the mechanical dysfunction found in chronic rhinosinusitis with nasal polyposis.

KEY WORDS: paranasal sinus disease, chronic disease, rhinosinusitis, chronic rhinosinusitis, sinusitis

RIASSUNTO

La rinosinusite cronica con poliposi nasale è una malattia caratterizzata da una disfunzione meccanica che facilita la crescita anomala della mucosa nasale, a causa del suo peculiare processo di rimodellamento. Questo studio si propone di valutare gli effetti del cross-linking sulla matrice extracellulare del tessuto del polipo nasale. Sono stati selezionati sei pazienti sottoposti ad intervento chirurgico di polipectomia. È stata applicata la tecnica del cross linking del collagene con riboflavina / UVA alla superficie dei polipi resecati epitelizzati e disepitelizzati del gruppo di pazienti sottoposti ad intervento. I polipi del gruppo di controllo non sono stati sottoposti a procedure di cross linking. Le sezioni ultrasottili (8 µm) di tessuto polipoide sono state analizzate mediante immunofluorescenza con anticorpi anti collagene di tipo I di topo e anticorpi secondari coniugati AlexaFluor 488 con controcolorazione DAPI e analizzate mediante microscopia confocale. L'effetto del cross-linking è risultato visibile al microscopio confocale a fluorescenza. La morfologia

Received: December 11, 2019
Accepted: August 4, 2020

Correspondence
Rogério Pezato
ENT Research Lab. Department of Otorhinolaryngology - Head and Neck Surgery, Federal University of Sao Paulo. Rua Pedro de Toledo 781, 1o andar, sala 3 - Vila Clementino - São Paulo - SP - Brazil
CEP 04039-032
Tel. +55 11 5576-4848 PABX number:17267
E-mail: pezatobau@gmail.com

Funding
This work was supported by Coordenação de Aperfeiçoamento de Pessoal de Nível Superior (CAPES) PROAP

Conflict of interest
The Authors declare no conflict of interest.

How to cite this article: Coronel N, Pezato R, do Amaral JB, et al. Structural changes in the extracellular matrix after cross-linking of nasal polyp tissue. Acta Otorhinolaryngol Ital 2020;40:426-434. https://doi.org/10.14639/0392-100X-N0566

© Società Italiana di Otorinolaringoiatria e Chirurgia Cervico-Facciale

OPEN ACCESS

This is an open access article distributed in accordance with the CC-BY-NC-ND (Creative Commons Attribution-Non-Commercial-NoDerivatives 4.0 International) license. The article can be used by giving appropriate credit and mentioning the license, but only for non-commercial purposes and only in the original version. For further information: https://creativecommons.org/licenses/by-nc-nd/4.0/deed.en

quantitativa è stata associata all'analisi di imaging in fluorescenza e sono state valutate la densità e la luminosità dei pixel. La superficie dei polipi trattati mostrava una maggiore densità di fibre di collagene rispetto ai polipi di controllo, come è stato possibile osservare sia visivamente che attraverso misurazioni oggettive delle regioni fluorescenti. L'effetto è stato potenziato sulla superficie dei polipi disepitelizzati. La maggiore densità di fibre di collagene esibita dai polipi trattati disepitelizzati dimostra la fattibilità di questa tecnica per interferire con il processo di rimodellamento e affrontare la disfunzione meccanica riscontrata nella rinosinusite cronica con poliposi nasale.

PAROLE CHIAVE: *malattia dei seni paranasali, patologia cronica, rinosinusite, rinosinusite cronica, sinusite*

Introduction

Chronic rhinosinusitis with nasal polyposis (CRSwNP) is characterised by chronic inflammation of the nasal mucosa with an altered remodelling process, which affects extracellular matrix (ECM) formation and facilitates mechanical dysfunction and oedema formation [1].

The pathogenesis of CRSwNP is still not fully understood [2,3]; however, its foundation is the aforementioned chronic inflammatory process, characterised by a major imbalance in immunomodulation which increases inflammatory cells (such as dendritic cells, eosinophils, and T helper cells) and decreases immunoregulatory cells (such as regulatory T cells), as well as an impaired immunomodulation of mesenchymal stem cells [4,5].

Studies on the mechanical forces involved in nasal polyp development have been conducted in an attempt to at least partly elucidate the pathophysiology of CRSwNP [1,6,7]. Changes in the mechanical response of the nasal mucosa have been observed in patients with CRSwNP compared to the healthy mucosa of the middle meatus, with a loss of effectiveness in adequately increasing the interstitial hydrostatic pressure (IHP) in response to water inflow during the inflammatory process [1].

This discovery provides a new perspective for biomechanical management of CRSwNP [1] beyond treatment of the inflammatory process (corticosteroids, non-steroidal anti-inflammatory drugs, leukotriene receptor antagonists, anti-immunoglobulin antibodies and biological agents that modulate the inflammatory environment) [8].

Within this context, the study of the mechanical dysfunction of CRSwNP has become increasingly relevant. It has previously been shown that ECM composition interferes with the biomechanical response of nasal mucosa. Nasal mucosa with fibrosis (synechiae) and healthy nasal middle meatus mucosa produce similar mechanical responses, suggesting that changes in ECM composition may contribute to prevent oedema formation and, potentially, have an impact on CRSwNP treatment [7].

Recent studies have confirmed that increased IHP contributes to a reduction of nasal polyps. In one investigation, the authors increased this pressure by imparting continuous positive airway pressure (CPAP) in nasal polyp tissue. Such indirectly increased interstitial hydrostatic pressure was associated with a decrease in polyp volume and milder nasal-obstruction symptoms [9]. Considering the close interdependence between the IHP response and ECM composition, the remodelling process is an essential target in approaching the mechanical dysfunction of CRSwNP.

It is reasonable to speculate that not only would changes in ECM composition be capable of altering the mechanical properties of the tissue, but also that structural changes in the existing ECM could affect tissue mechanical properties. In ophthalmology, the riboflavin/UVA cross-linking technique has been used to alter ECM conformation and thus prevent the progression of corneal bulging in keratoconus, a disease characterised by derangement of ECM deposition, which facilitates change in the shape of the cornea [10-12]. In the same way, the strengthening of the structures that compose the ECM in nasal polyp mucosa might impact the remodelling process and act on the biophysics mechanisms involved in the nasal polyp development [13].

In this context, we evaluated the effect of this cross-linking technique upon polyp stromal collagen in patients with CRSwNP.

Materials and methods

This study was approved by the University of São Paulo Research Ethics Committee, protocol number 2905802, and conducted in accordance with the provisions of the Helsinki Declaration.

Histological sections of nasal polyp tissue from 6 patients with NP, diagnosed according to the European Position Paper on Rhinosinusitis and Nasal Polyps (EPOS) criteria, were evaluated [8]. Patients between 18 and 60 years of age, non-steroidal anti-inflammatory tolerant, non-smokers were selected. The exclusion criteria were degenerative or autoimmune diseases, cystic fibrosis, pregnancy and topical or systemic corticosteroid therapy within the 4 weeks preceding surgery for removal of nasal polyps.

Application of the cross-linking technique

Immediately after resection, polyp fragments were prepared and divided into two groups: control and intervention. The control group received no intervention. In the intervention group, riboflavin/UVA cross-linking was performed on the epithelial surface of the polyps of patients 1, 2, 3, 4 and 5.

In patient 6, the polyp was cut in half and the treatment applied to the de-epithelialised cut surface (Fig. 1).
In the intervention group, a photosensitising solution containing 0.1% riboflavin-5-phosphate and 20% dextran T-500 was applied to the surface of the polyp every 5 minutes for 30 minutes to ensure saturation of the polyp stroma with riboflavin. After 30 minutes, UVA radiation (365 nm) was applied 45 mm from the polyp surface, for 30 minutes, using a solid-state device (X-Link, Opto Eletrônica, São Carlos, Brazil) with a surface irradiance output of 3 mW/cm^2 (Fig. 1). The energy applied was 5.375 J/cm^2. Surface irradiation was ensured by continuous, microprocessor-based, automated monitoring by the X-Link device, which uses an internal power meter. After application of the cross-linking technique, polyps were frozen at -80°C.
Ultrathin cryostat sections (8 µm, -21°C) of treated and untreated polyps were obtained and analysed.
In the first four patients, sections were made parallel to the surface exposed to riboflavin/UVA. In patients 5 and 6, sections were obtained longitudinally (perpendicular to the exposed surface), so that all slides included the UVA-exposed area and the underlying stroma.

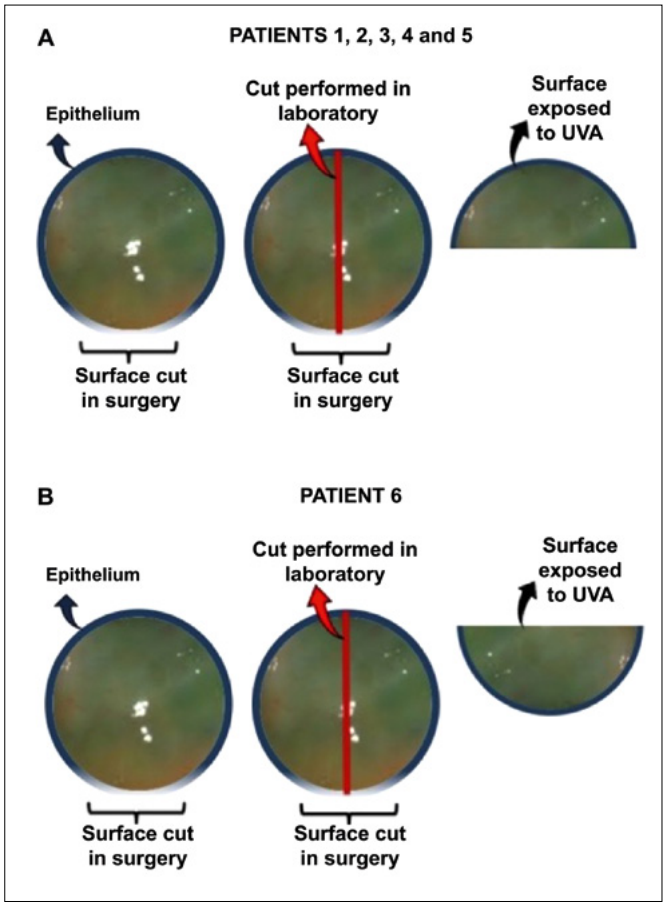

Figure 1. Polyp and area of riboflavin/UVA application. (**A**) In patients 1, 2, 3, 4, and 5: on the epithelialised surface of the polyp. (**B**) In patient 6: polyp cut in half and treatment applied on the de-epithelialised cut surface.

Eosinophil count

Part of the polyps was fixed using 10% acetaldehyde, maintained for 24 hours at room temperature, and then preserved in 70% alcohol for analysis. The previously fixed nasal tissue portions were embedded in paraffin and 4-µm-thick sections were obtained using a microtome. All sections were affixed onto Superfrost Plus glass slides (Menzel Glaser, Braunschweig, Germany) and dried at 60°C for a few hours. For deparaffinisation, slides were washed successively in xylene (3 times for 10 minutes), 100% ethanol (2 times for 5 minutes), 90% ethanol (2 times for 5 minutes) and 70% ethanol (2 times for 5 minutes). The nuclei were stained with alum haematoxylin (Lillie-Mayer's solution) for 5 minutes and rinsed in running tap water. Differentiation was performed with 0.3% acid alcohol, sections were rinsed again in running tap water and, subsequently, in Scott's tap water substitute (sodium hydrogen carbonate 10 g, magnesium sulphate 100 g, distilled water 5 L).
After rinsing in tap water, sections were stained with eosin solution (1% eosin Y 400 mL, 1% aqueous phloxine 40 mL, 95% alcohol 3100 mL and glacial acetic acid 16 mL) for 2 minutes, dehydrated, and cleared.
Histological examination was performed by a pathology expert through a Leica DM2000 binocular microscope at 400x magnification. The absolute number of eosinophils per high-power field (HPF) was counted in an average of 10 independent fields of view selected from the most inflamed area of tissue.

Processing for immunofluorescence

The slides were washed with phosphate-buffered saline (PBS), covered with 2.5% PBS and albumin solution, and stored in a moisture chamber under refrigeration. After 2 hours, they were incubated with primary antibody (anti-type I collagen, Calbicochem, Darmstadt, Germany) at 1:50 concentration in PBS containing 1% bovine serum albumin and 0.1% saponin.
The next day, the slides were again rinsed with PBS and incubated with secondary antibody (AlexaFluor 488 conjugated anti-mouse IgG, Molecular Probes, Carlsbad, CA) at 1:300 concentration for 30 minutes. Next, slides were washed with ice-cold PBS and incubated with 1:2500 DAPI (4,6-diamidino-2-phenylindole dihydrochloride, Molecular Probes) in a PBS solution containing 0.1% saponin, for 30 minutes, to ensure nuclear staining. Finally, slides were washed again with PBS and mounted with Fluoromount-G liquid medium (Electron Microscopy Sciences, Hatfield,

PA) and, after 12 hours, were sealed with clear nail polish and stored at -80°C.
For each patient, one intervention slide and one control slide were set aside for use as negative controls. These slides were not treated with primary antibodies, for purposes of comparison with control-group polyps.
All slides were visualised and photographed using a Leica TCS SP8 confocal laser scanning microscope.

Comparison of images after tissue immunofluorescence
Images of sections of epithelialised and non-epithelialised polyps were first compared visually, with analysis focusing on the surface region to which riboflavin/UVA was applied and the corresponding region on the control polyp. Collagen fibres were stained green, while the nuclei of the epithelial cells were stained blue.

Objective assessment of images
The images obtained by confocal microscopy were also examined for two objective parameters: tissue texture, through pixel encoding by the local binary pattern (LBP) method and luminous intensity distribution.

1. Analysis of tissue texture by pixel encoding
   LBP is a method used in the field of computer vision for texture analysis of monochrome digital images. In the context of a digital image, the texture of each pixel is defined by the local variations in intensity of the nearest neighbouring pixels. When applied to an image, LBP compares the intensities of a central pixel with those of its 8 neighboring pixels, assigning a value of 1 when the intensity of a neighboring pixel is greater than or equal to the intensity of the central pixel and 0 otherwise. This generates a numeric representation that consists of a sequence of 8 binary digits (0 or 1), which represents the characteristics of the central pixel. This sequence of 8 binary digits is then expressed as its decimal equivalent. The 8-digit binary sequence can generate up to 256 different local patterns, some of which can be considered equivalent because they represent the same texture pattern.
   All binary sequences representing the same texture were grouped into the same set, known as the LBP code set. From this perspective, up to 10 sets of LBP codes could be created, which were denoted by numbers 0 to 9. Each of these codes was associated with a specific image feature. For example, codes 2 and 6 were associated with half-edges, while codes 3 and 5 were associated with dark and light edges, respectively. Half-edges, corresponding to discontinuous edges which do not exceed 2 pixels in length, represent collagen fibres that were photographed only partly or present any loss of continuity. Edges, in our context, represent the contour of whole collagen fibres.
   We applied the LBP method only to the regions of interest of the confocal photomicrographs. Data were obtained in the area juxtaposed to the surface to which the cross-linking agents were applied, at a depth of 105 µm (Figs. 2A-C), and in the control polyps, in the corresponding area also 105 µm in depth (Figs. 2D-F). Finally, a histogram of the decimal values attributed to each pixel group was generated, representing the texture pattern associated to the digital images of clinical specimens.
2. Analysis of luminous intensity distribution
   Analysis of luminous intensity distribution specifically evaluates pixels associated with greater brightness. In our photomicrographs, brighter areas (i.e., those with greater luminosity) represent collagen fibres.
   Brightness values in a monochrome image range from 0 to 255, where 0 represents the darkest hue and 255, the lightest. Bright pixels were defined as those with a hue exceeding a given threshold T, where $0 \leq T \leq 255$. One threshold value was attributed to the whole set of digital images under study. Subsequently, it was calculated which percentage of the whole image pixels belong to the bright part of the image, revealing the extension of the image area occupied by collagen fibres. This strategy allowed collagen fibre areas of control and intervention images to be compared, as the control and intervention images were acquired under the same conditions.

Results

Eosinophils per High-Power Field (HPF)
All 6 polyps analysed presented more than 5 eosinophils per HPF, characterising the eosinophilic endotype of CRSwNP.

Tissue immunofluorescence microscopy
Microscopically, a 105 µm-thick fluorescent line was visible on the treated surface of epithelialised (Figs. 3A-B) and de-epithelialised (Figs. 3C-D) polyps, stratified into a superficial zone with more organised collagen fibres and a deeper zone with less organised collagen fibres. The differences between the control and intervention groups, concerning the organisation of collagen fibres were even more evident in the de-epithelialised polyps.

Analysis of tissue texture by pixel encoding
Among the controls of the epithelialised polyp group, the most frequent LBP profile observed was code 4 (Fig. 4A), corresponding to the edges of collagen fibres. Edge detection occurred due to the contrast of the bright collagen fi-

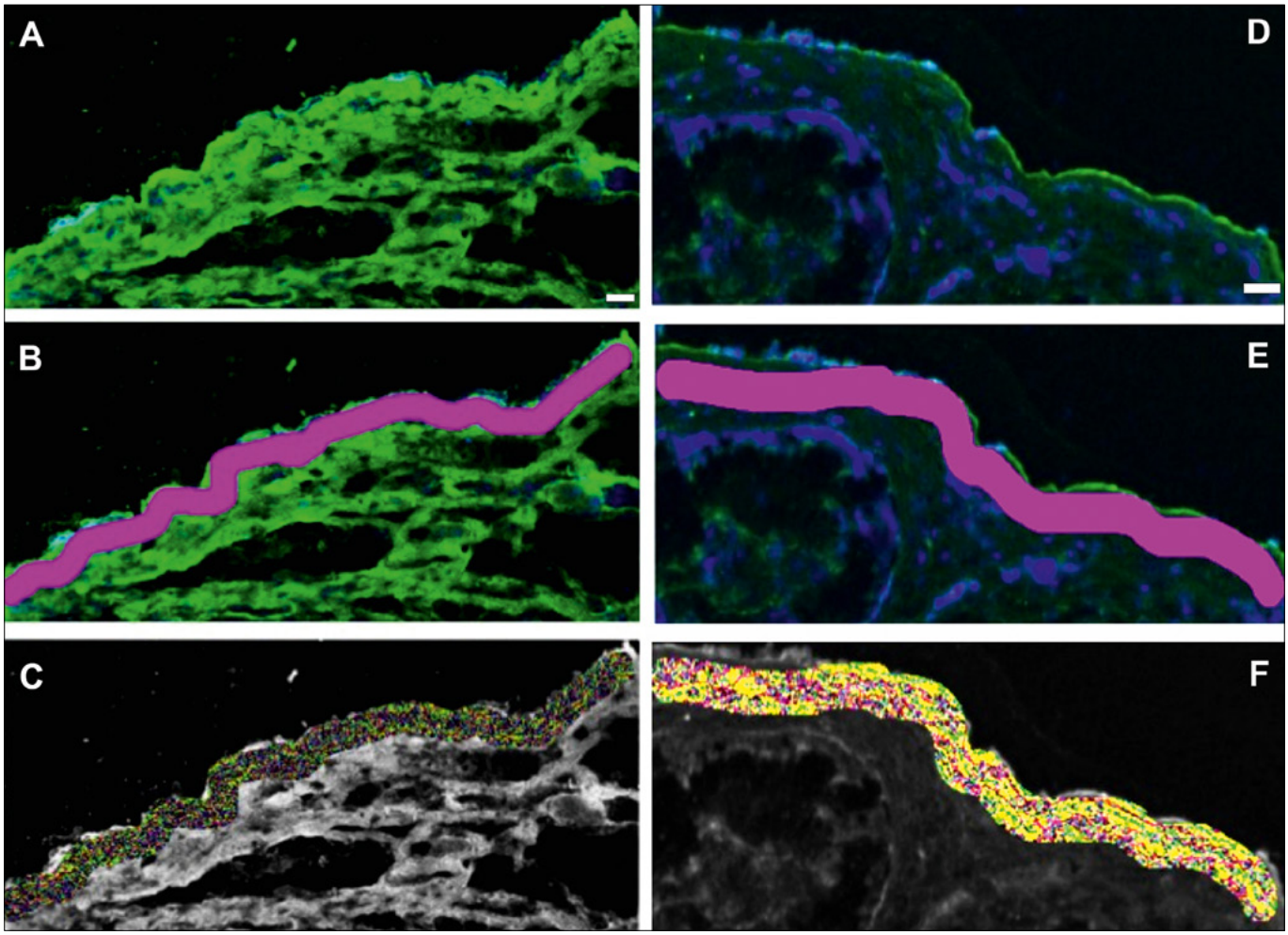

Figure 2. Area of LBP analysis in a representative treated polyp (patient 6). (**A**) Histological section to which cross-linking was applied. (**B**) In pink, demarcated area at a depth of 105 µm from which LPB codes were obtained. (**C**) Colour representation of LBP codes in the previously demarcated area. Area of LBP analysis in a representative control polyp (patient 6). (**D**) Histological section of the polyp. (**E**) In pink, demarcated area at a depth of 105 µm from which LPB codes were obtained. (**F**) Colour representation of LBP codes in the previously demarcated area.

bres with dark areas in which fibres were absent. The presence of edges implied a reference level for the control fibre densities in the epithelialised polyp tissues. The exposure of the epithelialised polyp tissues to riboflavin/UVA induced a distinct LBP profile. The lowering of code 4 relative frequencies and the higher frequencies for code 8 corresponded to the bright hue of the labeled areas, denoting a greater concentration of collagen fibres in which individual edges were less observable.

Among the de-epithelialised polyps (Fig. 4B), code 4 was also the most frequent LBP profile among the control polyps, while the UVA-exposed de-epithelialised polyp had its highest peak on code 9.

The tissue texture analysis demonstrated that both the epithelialised and the de-epithelialised polyps increased collagen fibre concentration.

In both situations, the pattern of distribution of LBP code densities after UVA exposure has changed; density of code 4 decreased in the treated polyps, which corresponds to an increase in collagen fibre concentration.

Luminous intensity distribution

Figure 5 shows a plot of tissue luminous intensity distribution for individual patients. It was demonstrated a higher luminous intensity after UVA applications, which corresponds to greater collagen fibre densities in the analysed areas.

Discussion

Studies of tissue biomechanics in NP have led to a progressive paradigm shift by revealing that the development of

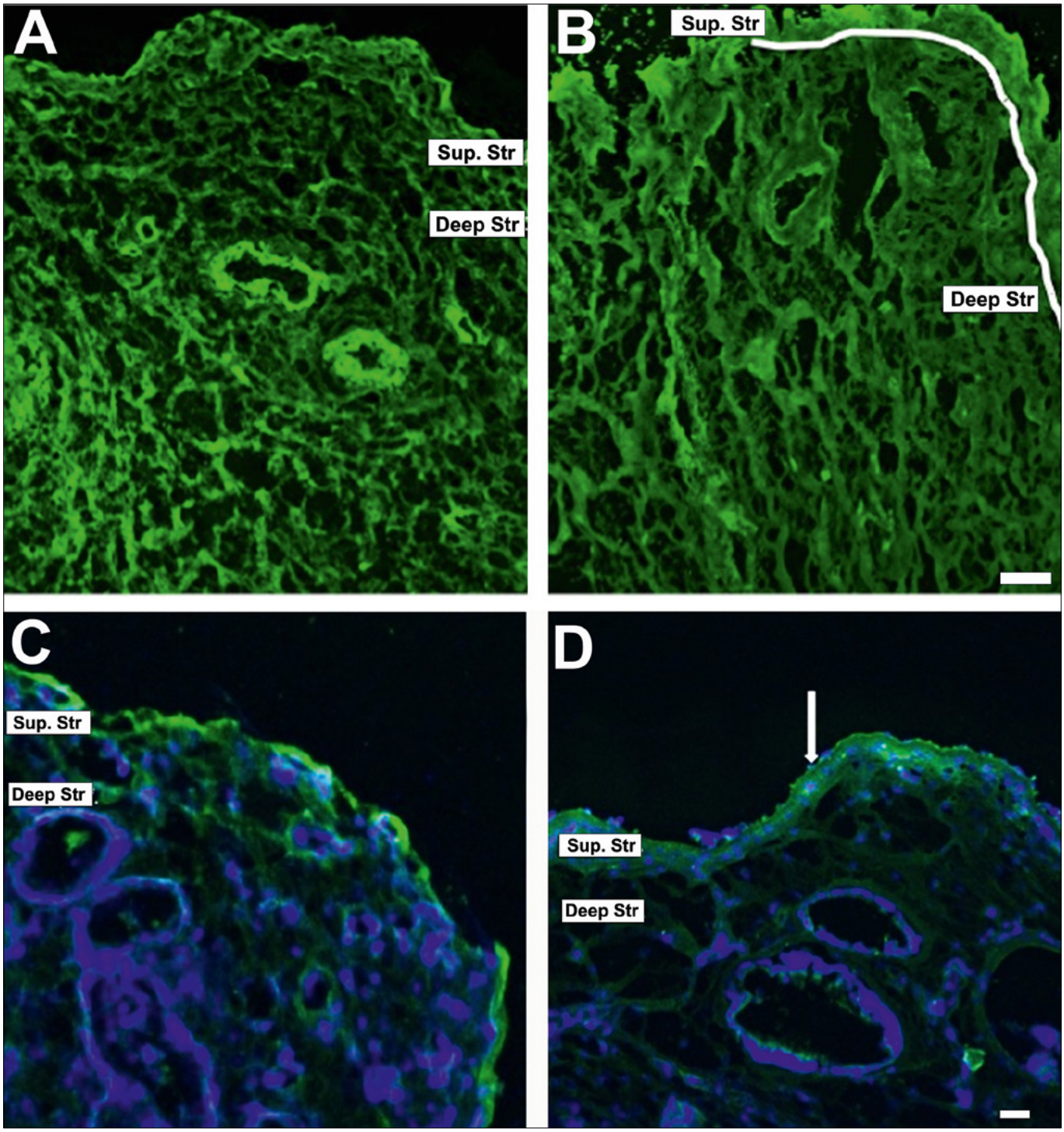

Figure 3. Photomicrograph of epithelialised nasal polyp section stained with anti-type I collagen antibody. (**A**) Control polyp, with rather disorganised collagen fibres (green) on the cut surface. (**B**) Intervention polyp exposed to riboflavin/UVA cross-linking of the epithelialised surface, with greater organisation of collagen fibres in the superficial stroma (above and to the right of the white line). Photomicrograph of de-epithelialised nasal polyp section stained with anti-type I collagen antibody. (**C**) Control polyp, with rather disorganised collagen fibres (green) on the cut surface. (**D**) Intervention polyp exposed to riboflavin/UVA cross-linking of the de-epithelialised surface, with highly organised collagen fibres in the superficial stroma (arrow). Sup. Str.: superficial stroma; Deep Str.: deep stroma.

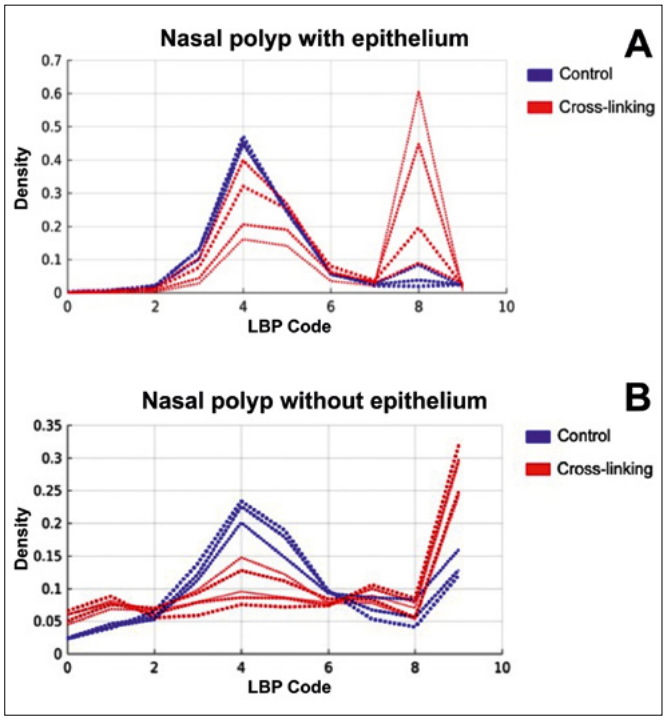

Figure 4. Histogram of LBP code density in epithelialised polyp tissue. In the control polyp, the peak (blue) occurs on LBP code 4, which represents greater presence of pixels corresponding to edges. In the polyp exposed to cross-linking, the peak occurs on code 8, which represents uniform green-coloured regions, corresponding to immunostained collagen fibres (**A**). Histogram of LBP code density in de-epithelialised polyp tissue. In the control polyp, the sole peak occurs on code 4, which represents a greater presence of edge-associated pixels, whereas in the polyp exposed to cross-linking, the peak occurs on code 9 (**B**).

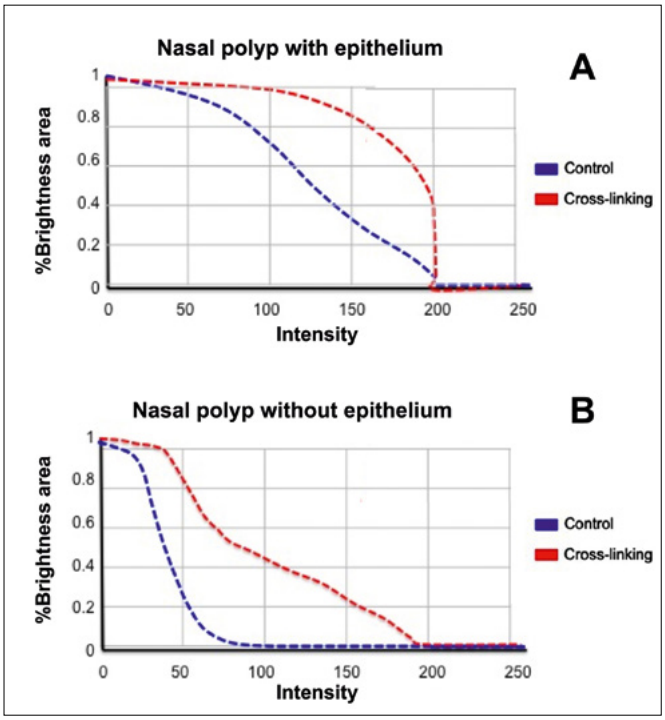

Figure 5. Mean luminous intensity curves of epithelialised (**A**) and de-epithelialised polyps (**B**). Blue represents control sections, and red, the intervention (treated) sections.

this condition is based on two processes: not only chronic inflammation, but also mechanical dysfunction. Within this context, the present study aimed to induce changes in the structure of the polyp ECM with a view to potentially modify the mechanical dysfunction found in polyp tissue.

This was the first investigation to evaluate a method capable of altering the shape and density of collagen in the ECM of nasal polyps. For this purpose, we used the riboflavin/UVA collagen cross-linking process. This method was chosen because it is already in clinical use in ophthalmology and has proven efficient in modifying the natural history of keratoconus, a disease characterised by derangement of ECM deposition, which facilitates change in the shape of the cornea [10-12,14].

In CRSwNP, the composition of the ECM is different from that of normal nasal tissue, especially regarding collagen, which is present at lower concentrations [15]. This process of altered tissue remodelling in NP has direct effects on the biomechanical properties of the polypoid tissue, facilitating tissue growth and oedema [1].

At the cellular level, ontological genetic analysis has shown that, in mesenchymal stem cells derived from nasal polyps, genes related to the ECM remodelling process are differentially modulated when compared to those of bone marrow-derived mesenchymal stem cells [5].

It has also been demonstrated that fibrotic tissue found in the nasal mucosa (synechiae) and the mucosa of the middle nasal meatus have similar mechanical properties. Moreover, it is suggested that the fibrotic modification of the biomechanical properties of the nasal mucosa of patients with CRSwNP, a tissue repair phenomenon in which increased collagen concentrations play a predominant role, could interfere in the altered remodelling process found in polypoid tissue [7].

Collagen fibres provide tensile strength to tissues. In living tissue, these fibres are stabilised through the formation of intermolecular covalent bonds, mediated by lysyl oxidase enzymes [16]. The intensity of this stabilisation can be increased artificially by application of UVA radiation directly to tissue, without altering the composition of the underlying ECM, through the cross-linking technique [12].

Previous studies performed on the porcine cornea have shown that riboflavin acts as a photosensitising agent and, when irradiated by UVA, leads to the formation of free radicals that create new chemical bonds within the corneal

stroma. This procedure increases the diameter of the collagen fibres and establishes stronger interfibrillar attachment, increasing the biomechanical stability of the exposed tissue [10-12,17].

Based on this method, we employed the same protocol for riboflavin/UVA exposure used in ophthalmology for keratoconus treatment in order to evaluate whether the same changes that occur in the corneal ECM can be induced in nasal polyp tissue [18].

In the images obtained from the epithelialised polyp, there was a slight increase in fibre density up to 105 µm below the epithelium, i.e., the depth reached by UVA radiation. Increased fibre density data were corroborated by objective analysis of the pixel patterns and brightness of images.

The increase in collagen fibre density was greater in the de-epithelialised polyp, with a higher fibre density at the surface where the riboflavin and UVA were applied. This revealed that the presence of the epithelium interfered negatively with riboflavin penetration into the stroma. This phenomenon resembles that found in the cornea, where removal of the epithelium intensifies the effect of cross-linking [17,18].

Objective analysis of pixel patterns and luminosity in the irradiated region reinforces the results of visual examination and provides reliable data for comparison, showing a greater impact on fibre density in the treated polypoid tissue than in untreated tissue.

These results also provide an opportunity for further investigations to replicate this pilot experiment, prompting further research into the ECM of the nasal polyp stroma and on the potential impact of structural changes to the conformation of the constituent proteins of the ECM on the mechanical properties of nasal polypoid tissue.

If the tissue changes observed after exposure to the cross-linking technique are shown to have a direct effect on the biomechanics of nasal polypoid tissue, this would open new avenues for the treatment of nasal polyposis, no longer based on anti-inflammatory agents or surgery alone, but rather by directly altering the mechanical properties of the affected tissue.

This technique has the potential for immediate application after polypectomy in patients with a history of recurrent CRSwNP, when this mucosa is already partially de-epithelialised. Once polyps have been removed and mucosal re-epithelialisation has not yet begun, one would expect for cross-linking to have the same effect observed in the de-epithelialised polyp in this study. We could also take advantage of the amplification of access to sinus cavities after sinus surgery and promote cross-linking on sinus walls.

Within this context, riboflavin/UVA cross-linking might also have utility as an outpatient office procedure to slow the growth of polypoid tissue, as our study showed that, although the method was less effective in epithelialised tissue, it still had an effect on the extracellular matrix structure of the nasal polyp. Prospective clinical studies are needed to evaluate the applicability of this procedure in the treatment of CRSwNP.

Conclusions

The results of this study show that riboflavin/UVA cross-linking promotes changes in the structural conformation of collagen fibres and increases their density on the exposed surface of nasal polyp tissue.

References

1. Pezato R, Voegels R, Pinto Bezerra T, et al. Mechanical dysfunction in the mucosal oedema formation of patients with nasal polyps. Rhinology 2014;52:162-6. https://doi.org/10.4193/Rhin13.066
2. Gelardi M, Piccininni K, Quaranta N, et al. Olfactory dysfunction in patients with chronic rhinosinusitis with nasal polyps is associated with clinical-cytological grading severity. Acta Otorhinolaryngol Ital 2019;39:329-35. https://doi.org/10.14639/0392-100X-2426
3. Pistochini A, Rossi F, Gallo S, et al. Multiple gene expression profiling suggests epithelial dysfunction in polypoid chronic rhinosinusitis. Acta Otorhinolaryngol Ital 2019;39:169-77. https://doi.org/10.14639/0392-100X-2361
4. Pezato R, Pérez-Novo CA, Holtappels G, et al. The expression of dendritic cell subsets in severe chronic rhinosinusitis with nasal polyps is altered. Immunobiology 2014;219:729-36. https://doi.org/10.1016/j.imbio.2014.05.004
5. Oliveira PWB, Pezato R, Agudelo JSH, et al. Nasal polyp-derived mesenchymal stromal cells exhibit lack of immune-associated molecules and high levels of stem/progenitor cells markers. Front Immunol 2017;8:39. https://doi.org/10.3389/fimmu.2017.00039
6. do Amaral JB, Bloise AC, França CN, et al. Alterations in cellular force parameters and cell projections in nasal polyps-derived fibroblasts. Auris Nasus Larynx 2020;47:98-104. https://doi.org/10.1016/j.anl.2019.06.007
7. Gregório L, Pezato R, Felici RS, et al. Fibrotic tissue and middle turbinate exhibit similar mechanical properties. is fibrosis a solution in nasal polyposis? Int Arch Otorhinolaryngol 2017;21:122-5. https://doi.org/10.1055/s-0036-1593728
8. Fokkens WJ, Lund VJ, Hopkins C, et al. European Position Paper on rhinosinusitis and nasal polyps 2020. Rhinology 2020;58(Suppl S29):1-464.
9. Balsalobre L, Pezato R, Mangussi-Gomes J, et al. What is the impact of positive airway pressure in nasal polyposis? An experimental study. Int Arch Otorhinolaryngol 2019;23:147-51. https://doi.org/10.1055/s-0038-1676095
10. Spoerl E, Huhle M, Seiler T. Induction of cross-links in corneal tissue. Exp Eye Res 1998;66:97-103. https://doi.org/10.1006/exer.1997.0410
11. Wollensak G, Spoerl E, Seiler T. Riboflavin/ultraviolet-a-induced collagen crosslinking for the treatment of keratoconus. Am J Ophthalmol 2003;135:620-7. https://doi.org/10.1016/S0002-9394(02)02220-1
12. Wollensak G, Spoerl E, Seiler T. Stress-strain measurements of human and porcine corneas after riboflavin-ultraviolet-A-induced cross-linking. J Cataract Refract Surg 2003;29:1780-5. https://doi.org/10.1016/S0886-3350(03)00407-3

[13] Pezato R, Voegels RL, Pignatari S, et al. Nasal polyposis: more than a chronic inflammatory disorder - a disease of mechanical dysfunction - the São Paulo position. Int Arch Otorhinolaryngol 2019;23:241-9. https://doi.org/10.1055/s-0038-1676659

[14] Daxer A, Fratzl P. Collagen fibril orientation in the human corneal stroma and its implication in keratoconus. Invest Ophthalmol Vis Sci 1997;38:121-9.

[15] Van Bruaene N, Derycke L, Perez-Novo CA, et al. TGF-β signaling and collagen deposition in chronic rhinosinusitis. J Allergy Clin Immunol 2009;124:253-9, 259.e1-2. https://doi.org/10.1016/j.jaci.2009.04.013

[16] Kagan HM, Li W. Lysyl oxidase: properties, specificity, and biological roles inside and outside of the cell. J Cell Biochem 2003;88:660-72. https://doi.org/10.1002/jcb.10413

[17] Wollensak G, Wilsch M, Spoerl E, et al. Collagen fiber diameter in the rabbit cornea after collagen crosslinking by riboflavin/uva. Cornea 2004;23:503-7. https://doi.org/10.1097/01.ico.0000105827.85025.7f

[18] Bottós KM, Regatieri CVS, Dreyfuss JL, et al. Immunofluorescence confocal microscopy of porcine corneas following collagen crosslinking treatment with riboflavin and ultraviolet A. J Refract Surg 2008;24:S715-S9. https://doi.org/10.3928/1081597x-20080901-14

ACTA OTORHINOLARYNGOLOGICA ITALICA 2020;40:435-443; doi: 10.14639/0392-100X-N0716

Rhinology

Effects of biological therapies on chronic rhinosinusitis in severe asthmatic patients

L'efficacia delle terapie biologiche sulla rinosinusite cronica nel paziente asmatico severo

Francesco Bandi[1,2*], Stefania Gallo[2*], Andrea Preti[4,5], Francesco Mozzanica[4,6], Dina Visca[7,8], Margherita Marelli[9], Enrico Maddalone[2], Cinzia Gambarini[9], Adriano Vaghi[10], Antonio Spanevello[7,8], Paolo Castelnuovo[2,3]

[1] Department of Otolaryngology-Head and Neck Surgery, European Institute of Oncology, Milan, Italy; [2] Department of Otorhinolaryngology, University of Insubria and ASST Sette Laghi, Varese, Italy; [3] Department of Biotechnology and Life Sciences, University of Insubria, Varese, Italy; [4] Department of Otorhinolaryngology, IRCCS Multimedica, Milano, Italy; [5] Department of Medicine and Surgery, University of Insubria, Varese, Italy; [6] Department of Biomedical and Clinical Sciences, University of Milan, Italy; [7] Istituti Clinici Scientifici Maugeri IRCCS, Respiratory Rehabilitation of the Institute of Tradate, Italy; [8] Department of Medicine and Surgery, Respiratory Diseases, University of Insubria, Varese-Como, Italy; [9] Department of Pulmonology, ASST Sette Laghi, Varese, Italy; [10] ASST-Rhodense, UOC Pneumologia, Garbagnate Milanese, Milan, Italy

[*] F. Bandi and S. Gallo contributed equally to the work.

SUMMARY

Objective. The introduction of monoclonal antibody (mAb) therapies represents a promising treatment for refractory chronic rhinosinusitis (CRS). We assessed the effects of selected mAbs (omalizumab, mepolizumab, benralizumab) on CRS in severe asthmatic patients in a real-life setting.

Methods. A prospective observational study on severe asthmatic patients, treated with 3 different mAb (omalizumab, mepolizumab, benralizumab), and comorbid CRS was conducted. All patients were followed for 52 weeks. The degree of nasal control, SinoNasal Outcome Test (SNOT) 22, Nasal Polyp Score (NPS), Lund Kennedy Score (LKS) were collected at baseline and at 52-week.

Results. 40 patients (33 with nasal polyps) were studied. 33 patients (82.5%) had uncontrolled nasal disease at baseline, and 15 (37.5%) were uncontrolled after 52 weeks. Significant improvement was observed for SNOT 22 ($P < 0.001$), SNOT 1-12 ($P < 0.001$) and degree of nasal control ($P < 0.001$). Differences in NPS ($P = 0.130$) and LKS ($P = 0.124$) were not significant. Net change in the above-mentioned parameters among the three treatment groups was not significantly different.

Conclusions. The study shows an improvement of nasal symptoms after 52 weeks of mAb treatment, which was not associated with significant improvement of endoscopic findings. Larger studies are needed to assess the real-life efficacy of mAbs in CRS.

KEY WORDS: chronic rhinosinusitis, nasal polyps, asthma, monoclonal antibody, biological therapies

RIASSUNTO

Obiettivi. *L'introduzione degli anticorpi monoclonali (mAb) rappresenta una promettente risorsa per il trattamento delle rinosinusiti croniche (RSC) refrattarie. Obiettivo dello studio è valutare l'efficacia del trattamento biologico sulla RSC nel paziente asmatico severo in un contesto real-life.*

Metodi. *È stato condotto uno studio osservazionale di 52 settimane su pazienti asmatici severi, trattati con 3 diversi mAb (omalizumab, mepolizumab, benralizumab), e con RSC come comorbidità. Sono stati raccolti raccolti dati riguardanti il grado di controllo nasale, il SinoNasal Outcome Test (SNOT) 22, il Nasal Polyp Score (NPS), il Lund Kennedy Score (LKS) al baseline e a 52 settimane.*

Risultati. *Sono stati analizzati 40 pazienti (33 con polipi nasali). 33 pazienti (82.5%) presentavano una RSC non controllata al baseline, 15 (37.5%) soffrivano ancora di RSC non controllata dopo 52 settimane. Un miglioramento significativo è descritto per lo SNOT 22 ($P < 0.001$), lo SNOT 1-12 ($P < 0.001$) e il grado di controllo nasale ($P < 0.001$); differenze nel NPS ($P = 0.130$) e LKS ($P = 0.124$) sono risultate non significative. Il cambiamento netto dei sopracitati parametri tra i tre gruppi di trattamento non era significativamente differente.*

Received: February 26, 2020
Accepted: September 6, 2020

Correspondence
Bandi Francesco
Department of Otolaryngology-Head and Neck Surgery, European Institute of Oncology (IEO)
via Ripamonti 435, 20141 Milano
Tel. +39 02 57489490. Fax +39 02 94379216
E-mail: bandi.francesco@gmail.com

Funding
None.

Conflict of interest
The Authors declare no conflict of interest.

How to cite this article: Bandi F, Gallo S, Preti A, et al. Effects of biological therapies on chronic rhinosinusitis in severe asthmatic patients. Acta Otorhinolaryngol Ital 2020;40:435-443. https://doi.org/10.14639/0392-100X-N0716

© Società Italiana di Otorinolaringoiatria e Chirurgia Cervico-Facciale

OPEN ACCESS

This is an open access article distributed in accordance with the CC-BY-NC-ND (Creative Commons Attribution-Non-Commercial-NoDerivatives 4.0 International) license. The article can be used by giving appropriate credit and mentioning the license, but only for non-commercial purposes and only in the original version. For further information: https://creativecommons.org/licenses/by-nc-nd/4.0/deed.en

Conclusioni. Lo studio evidenzia a 52 settimane di trattamento con mAb un miglioramento dei sintomi, non associato a cambiamenti significativi dei riscontri endoscopici. Sono necessari studi più ampi per determinare l'efficacia nella real-life dei mAb nella RSC.

PAROLE CHIAVE: *rinosinusite cronica, polipi nasali, asma, anticorpi monoclonali, terapie biologiche*

Introduction

Chronic rhinosinusitis (CRS) is a heterogeneous inflammatory disease with an as-yet-undefined aetiology. A complex combination of altered immunity, genetics and environmental factors (microbiome, allergy, etc.) seems to play a cooperative role in disease initiation and progression [1]. Going beyond its rooted phenotypes (with nasal polyps, CRSwNP; without nasal polyps, CRSsNP), CRS is nowadays considered an umbrella term for different clinical entities mirroring diverse biomolecular inflammatory processes, the endotypes [2]. Extensive knowledge on CRS pathophysiological mechanisms would be entirely speculative, except endotypes become a potential therapeutic target.

Since CRS is closely connected to asthma by the "unified airways" theory [3], it is no surprise that not only pathogenesis, but also therapeutic principles may be similar in both sections of the airways. Thus, biological therapies currently approved for severe asthma may represent a treatment option for refractory CRS cases, who can count only on courses of oral corticosteroids (OCS), antibiotics or repeated sinus surgeries, with failures ranging from 20 to 40% according to different series [4,5].

The efficacy of biological agents in the treatment of asthma is widely reported and documented in literature [6]; meanwhile several research studies are documenting encouraging results for CRS, as well [7,8]. In Italy, 3 monoclonal antibodies (mAb) are approved for the treatment of severe asthma in clinical practice: omalizumab (anti-IgE), mepolizumab (anti-IL5) and benralizumab (anti-IL5R). Phase III trials are currently evaluating the efficacy of the same mAbs in patients affected by CRSwNP. Therefore, to date, in Italy, the indication to start a biological therapy falls in the purview of pneumological practice and dependent on the coexistence of severe asthma.

While several randomised clinical trials (RCT) have highlighted the efficacy of mAbs in CRSwNP [9-12], the current literature still lacks observational studies evaluating the response to biological treatments in real-life.

Therefore, while waiting to actively take part, as rhinologists, in treatment indications and selection of biological therapies, we report our preliminary real-life data regarding the clinical effects of selected mAbs (omalizumab, mepolizumab and benralizumab) on CRS in adult patients treated for severe asthma. The primary endpoint was to portray the main clinical CRS-related characteristics of a cohort of patients with severe asthma treated with biologicals and with CRS as a comorbidity. Secondary endpoints included evaluation of endoscopic sinonasal changes, variations in patient-reported outcomes and in the degree of nasal disease control over 52 weeks of treatment.

Materials and methods

Study population

An observational study was conducted at the ENT Department of a single tertiary care centre enrolling subjects affected by severe uncontrolled asthma, eligible for mAb therapy, and with CRS as a comorbidity between July 2017 and May 2019. The study was concluded in June 2020.

Included patients were over 18 years old, with a negative clinical history for genetic syndromes, congenital or acquired immunodeficiency, autoimmune disorders, malignancy or history of head and neck cancer, and drug abuse.

Patients were addressed by pulmonologists to specific biological agents (anti-IgE, omalizumab; anti-IL5, mepolizumab; anti-IL5R, benralizumab) to treat severe asthma according to GINA guidelines [13-16] within 1 month from our baseline evaluation and were monitored with regular clinical and endoscopic assessments every 3 months. For analytical reasons and in order to align data, the 52-week visit after first mAb dosing was set as a follow-up cut-point.

Rhinologists involved in the study did not intervene in treatment selection which depended exclusively on features of asthma. We point out that all patients presented a type 2 inflammation profile of the airways, defined by blood eosinophil count ≥ 250 cells/mm^3 and/or peripheral total IgE ≥ 100 kU/L at the time of enrollment [17].

The study was conducted in compliance with the Helsinki Declaration and with policies approved by the Insubria Board of Ethics. Informed consent was obtained from all participants included in the study.

Study methods

CRS was confirmed and classified as controlled, partly controlled or uncontrolled according to EPOS guidelines [17,18].

Data concerning demographic features, CRS and asthma onset, smoking habits, non-steroidal anti-inflammatory drug (NSAID) intolerance, blood eosinophil count, peripheral IgE count, nasal therapies, need for OCS for airways exacerbations, previous nasal surgeries, adverse events (AEs) were collected in an electronic database [19].

Sensitization for common inhalants was evaluated on the basis of recent pre-existing skin or blood tests as defined by the Global Atlas Test Panel for Europe [20].
Symptoms were collected through the Italian version of the SinoNasal Outcome Test 22 (SNOT 22) questionnaire [21] and analysed both as total (SNOT 22) and partial (SNOT 1-12) scores, and as individual symptoms [22,23].
Endoscopic findings of the entire cohort were scaled according to the Lund-Kennedy Score (LKS) [24] and the size of nasal polyps in the CRSwNP subgroup was calculated through the Nasal Polyp Score (NPS) [25].
Patients were further sorted into three different subgroups depending on the type of mAb therapy (anti-IgE, anti-IL5 and anti-IL5R groups) and reassessed by means of the above-mentioned outcome measures.

Statistical analysis

The Kolmogorov-Smirnov test was used to check the normality of the distribution. Since this test demonstrated that the distribution was not normal, non-parametric tests were used. In particular, the median and interquartile ranges were calculated for all variables. The Mann-Whitney test and Fisher test were used to compare the distribution of continuous and non-continuous variables between the pre and post-treatment periods and between the three treatment groups. For all statistical comparisons an $\alpha = 0.05$ was used.

Results

A cohort of 40 severe asthmatic patients was examined. 33 patients (82.5%) were affected by CRSwNP, and 7 patients (17.5%) were affected by CRSsNP. Demographic data are reported in Table I.
Eighteen patients (45%) were in continuative or intermittent OCS treatment for control of airway exacerbations; 30 patients (75%) had a history of endoscopic sinus surgery and the most frequent procedure was full-house endoscopic sinus surgery with removal of middle turbinate (ESS) (13 patients, 43.3%). 20 subjects (66.7%) underwent more than 1 endoscopic procedure, with a mean of 2.9 surgeries per patient. All operated patients performed a sinus CT scan before the last surgery and the mean Lund-Mackay score was 16.5 ± 4.0 (range 6-22). The majority of operated patients (24 patients, 80%) underwent the last surgery before the introduction of the mAb; in 6 subjects (20%) surgery was performed during mAb treatment. Further details on surgical treatments are specified in Table II.
Mean baseline LKS was 5.4 ± 2.7 (median 5, IQR 4-7) and mean 52-week LKS was 4.8 ± 3.1 (median 4, IQR 3-6.2). In the CRSwNP subgroup, mean baseline NPS was 2.6 ± 1.9 (median 2, IQR 1.2-4) and mean 52-week NPS was 2.0 ± 2.1 (median 2, IQR 0-2.7). Differences between scores at baseline and at 52-week were not significant at Mann-Whitney test with P = 0.124 for LKS and P = 0.130 for NPS.
The mean baseline SNOT 22 score was 56.4 ± 27.3 (range 8-104; median 57,5, IQR 35.7-80) and SNOT 1-12 was 33.1 ± 14.5 (range 4-59; median 35, IQR 24-45.2). The

Table I. Demographic data of the cohort (n = 40).

Variable	Value
Age (years)	54.4 (range 31-73)
Sex, M:F	12 (30%):28 (70%)
Smoke	
Active	2/40 (5%)
Ex-smoker	12/40 (30%)
Non smoker	26/40 (65%)
Inhalant sensitisation	29/40 (72.5%)
Seasonal	3/29 (10.3%)
Perennial	8/29 (27.6%)
Both	18/29 (62.1%)
NSAID intolerance	11/40 (27.5%)
CRSwNP	33/40 (82.5%)
CRSsNP	7/40 (17.5%)
CRS onset	
Early (< 40 y)	20/40 (50%)
Late (≥ 40 y)	20/40 (50%)
Asthma onset	
Early (< 40 y)	17/40 (42.5%)
Late (≥ 40 y)	23/40 (57.5%)
CRS vs asthma onset	
Concordant	21/40 (52.5%)
CRS followed by asthma	4/40 (10%)
Asthma followed by CRS	15/40 (37.5%)

M: male; F: female; NSAID: non-steroidal anti-inflammatory drugs; CRSwNP: chronic rhinosinusitis with nasal polyps; CRSsNP: chronic rhinosinusitis without nasal polyps; y: years old; CRS: chronic rhinosinusitis

Table II. Surgical history of the cohort.

Number of operated patients	30/40 (75%)
Type of surgery	
Polypectomy	5/30 (16.7%)
Anterior FESS	2/30 (6.7%)
FESS	6/30 (20%)
ESS	13/30 (43.3%)
ESS + Draf III frontal sinusotomy	4/30 (13.3%)
Mean number of surgeries for each patient	2.9 (range 1-13)
Mean age at first surgery	42.1 (range 18-59)
Last surgery performed before mAb	24/30 (80%)
Last surgery performed during mAb	6/30 (20%)

FESS: functional endoscopic sinus surgery; ESS: endoscopic sinus surgery; mAb: monoclonal antibody

mean 52-week SNOT 22 score was 30.5 ± 21.2 (range 1-83; median 26.5, IQR 14-47) and SNOT 1-12 was 17.5 ± 11.7 (range 0-46; median 17.5, IQR 6.7-26). Differences between scores at baseline and at 52-week were found significant at Mann-Whitney test with P < 0.001 for SNOT 22 score and P < 0.001 for SNOT 1-12 score. Statistically significant differences were also found for individual sinonasal symptoms such as nasal blockage (P < 0.001), rhinorrhoea (P < 0.001), hyposmia (P = 0.023), facial pain (P = 0.027) and ear fullness (P = 0.006).

Nasal disease at baseline was partly controlled in 7 patients (17.5%) and uncontrolled in 33 patients (82.5%). No patient was controlled at baseline. At 52-weeks, nasal disease was controlled in 6 patients (15%), partly controlled in 19 (47.5%) and uncontrolled in 15 (37.5%). In detail, the nasal disease score remained unchanged in 20 patients (50%), irrespective of baseline status (15 uncontrolled, 5 partly controlled), whereas 20 patients (50%) clinically improved with 16 patients climbing one rank of the nasal disease scale and 4 patients climbing two ranks. Overall, a positive behavioural trend is evident (P < 0.001).

No serious AEs were reported in our cohort. However, 25 patients (62.5%) reported minor AEs. Complaints included nasopharyngitis (17/40, 42.5%), oropharyngeal pain (15/40, 37.5%), back pain (11/40, 27.5%), arthralgia (10/40, 25%), influenza (8/40, 20%) and pyrexia (2/40, 5%).

Subgroup analysis: anti-IgE, anti-IL5 and anti-IL5R groups

Eleven patients (27.5%) were addressed to omalizumab therapy, 20 (50%) to mepolizumab and the remaining 9 (22.5%) to benralizumab. Seven patients (17.5%) had a history of a previous mAb treatment. In particular, 5 patients, first selected for omalizumab after an average of 26.4 ± 15.6 months were switched to mepolizumab due to poor response on the lower airways; for the same reason, 2 patients suspended mepolizumab after 5.0 ± 1.4 months and started benralizumab for unsuccessful control of asthma symptoms.

Demographics of treatment groups are shown in Table III. Differences concerning inhalants sensitisation (P = 0.196), NSAID intolerance (P = 0.411), prevalence of nasal polyps (P = 0.892), CRS onset (P = 0.818), asthma onset (P = 0.625), endoscopic sinus surgeries (P = 0.431), chronic OCS treatment (P = 0.638) and nasal steroid treatment (P = 0.258) were not significantly different.

Differences concerning parameters as SNOT scores and individual symptoms, LKS, NPS and blood eosinophil count between baseline and at 52-week in each treatment group are shown in Table IV.

Briefly, improvements in SNOT 22 and SNOT 1-12 scores were evident in all three groups, with anti-IgE and anti-IL5 groups reaching a significant difference between baseline and 52 weeks for both parameters. Moreover, anti-IL5 significantly reduced nasal blockage (P = 0.001) and ear fullness (P = 0.026) scores, whereas anti-IL5R significantly reduced the rhinorrhoea score (P = 0.040).

A significant change was observed in nasal disease control at 52 weeks in all three treatment groups (Fig. 1).

Concerning endoscopic parameters, no significant variations were evident for LKS between baseline and 52 weeks in any treatment group. Only anti-IL5 significantly reduced NPS in the subgroup of patients with nasal polyps (P = 0.029). However, once the 3 patients on treatment with mepolizumab and operated on during the 52-week observation period were excluded from the analysis, this significance was lost (P = 0.096).

Blood eosinophil count was available at baseline for 37 patients and at 52 weeks for only 29 patients. No differ-

Table III. Characteristics and differences between treatment groups. P is calculated with a non-parametric Mann-Whitney test.

	Anti-IgE group n = 11	Anti-IL5 group n = 20	Anti-IL5R group n = 9	P
Inhalant sensitisation	11/11 (100%)	12/20 (60%)	8/9 (88.9%)	0.196
NSAID intolerance	3/11 (27.2%)	7/20 (35%)	1/9 (11.1%)	0.411
CRSwNP	9/11 (81.8%)	17/20 (85%)	7/9 (77.8%)	0.892
CRS onset				0.818
Early (< 40 y)	5/11 (45.4%)	11/20 (55%)	4/9 (44.4%)	
Late (≥ 40 y)	6/11 (54.5%)	9/20 (45%)	5/9 (55.6%)	
Asthma onset				0.625
Early (< 40 y)	4/11 (36.4%)	10/20 (50%)	3/9 (33.3%)	
Late (≥ 40 y)	7/11 (63.6%)	10/20 (50%)	6/9 (66.7%)	
Endoscopic sinus surgery	7/11 (63.6%)	15/20 (65%)	8/9 (88.9%)	0.431
Chronic OCS therapy	6/11 (54.5%)	9/20 (45%)	3/9 (33.3%)	0.638
Nasal steroid therapy	5/11 (45.4%)	14/20 (70%)	7/9 (77.8%)	0.258

NSAID: non-steroidal anti-inflammatory drugs; CRSwNP: chronic rhinosinusitis with nasal polyps; CRS: chronic rhinosinusitis; y: years old; OCS: oral corticosteroids

Table IV. Differences between baseline and 52-week measurements of selected variables in each treatment group. P is calculated with a non-parametric Mann-Whitney test.

	Anti-IgE group n = 11		
	Baseline	52-week	*P*
	median (IQR 25th 75th)		
SNOT 22	48 (33-78.5)	22.5 (12-33.5)	**0.047**
SNOT 1-12#	27 (19.5-44)	13.5 (5.2-24.5)	**0.047**
Nasal blockage°	4 (3-4)	2.5 (0.25-3)	0.116
Rhinorrhea°	2.5 (2-4)	1.25 (0.6-1.9)	0.400
Facial pain°	2 (0-4)	0 (0-2)	0.133
Ear fullness°	3 (0.5-4)	2 (0-2.75)	0.519
Hyposmia°	4 (2-5)	1 (0-4)	0.365
LKS	6 (4.5-8)	4 (3.5-8)	0.401
NPS*	3 (2-5)	3 (2-5)	0.989
Blood eosinophils§	660 (457.5-1162.5)	490 (122.5-532.5)	0.083
	Anti-IL5 group n = 20		
	Baseline	52-week	*P*
	median (IQR 25th 75th)		
SNOT 22	64.5 (42.7-80.5)	37.5 (10.5-55.5)	**0.002**
SNOT 1-12#	36 (25.5-47.2)	19 (6.7-28)	**0.001**
Nasal blockage°	4 (3-5)	2 (0.75-3)	**0.001**
Rhinorrhea°	4.5 (2.5-5)	2.25 (1-3)	0.076
Facial pain°	1 (0-5)	0 (0-3)	0.127
Ear fullness°	3 (1.75-5)	0.5 (0-3)	**0.026**
Hyposmia°	5 (0.75-5)	1 (0-3.5)	0.068
LKS	4.5 (4-6)	4 (2.75-6)	0.253
NPS*	2 (2-3)	0 (0-2)	**0.029**
Blood eosinophils§	700 (375-1005)	80 (45-100)	**0.001**
	Anti-IL5R group n = 9		
	Baseline	52-week	*P*
	median (IQR 25th 75th)		
SNOT 22	56 (33-70)	24 (16-27)	0.063
SNOT 1-12#	35 (26-39)	13 (9-25)	**0.024**
Nasal blockage°	3 (3-4)	1 (0-3)	0.222
Rhinorrhea°	2.5 (2.2-3)	1 (1-2)	**0.040**
Facial pain°	0 (0-4)	0 (0-1)	0.666
Ear fullness°	3 (0-3)	0 (0-2)	0.136
Hyposmia°	5 (3-5)	4 (0-5)	0.546
LKS	6 (3-6)	4 (3-7)	0-796
NPS*	2 (0.5-2)	2 (1-3)	0.710
Blood eosinophils§	400 (350-560)	80 (0-287.5)	**0.026**

SNOT: SinoNasal Outcome Test; LKS: Lund-Kennedy Score; NPS: Nasal Polyp Score
 # SNOT 1-12 represents a SNOT 22 sub-category which assesses rhinologic, ear and facial symptoms. SNOT 1-12 value is therefore the sum of the values of the 12 items that composes this subcategory (maximum value 60)
° Listed symptoms are individual items of the SNOT 22, each one assessed by a 5-point scale
** NPS was calculated only in the CRSwNP subgroup in each treatment arm*
§ Blood eosinophils are expressed as number of cells per mm3

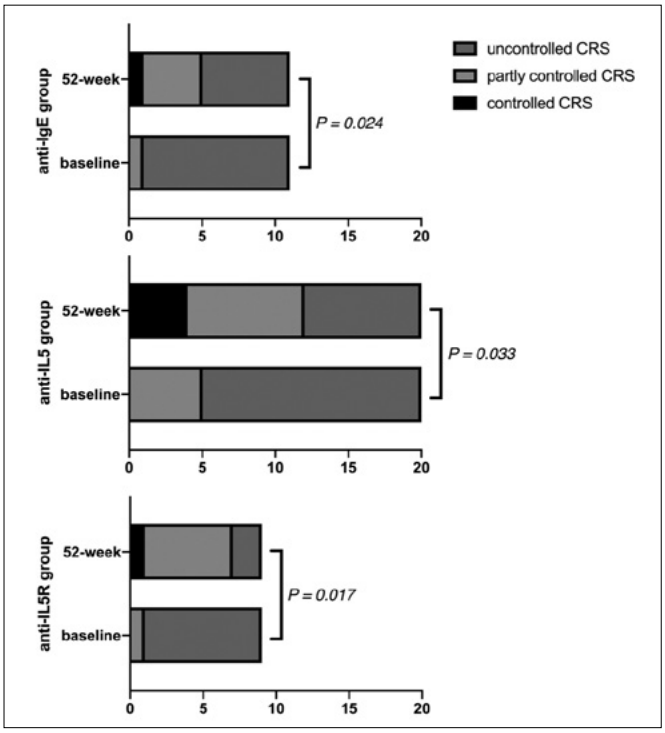

Figure 1. Graphic representation of the degree of nasal control in the three treatment groups and variations between baseline and week 52.

ence in baseline blood eosinophil count was evident among the three treatment groups (P = 0.129). Differences at Mann-Whitney test between baseline eosinophil count and 52 weeks were significant in the anti-IL5 and anti-IL5R groups (P = 0.001 and P = 0.026, respectively).

Mean net changes of scores between the three treatment groups along the 52-week observation period are shown in Table V. No significant difference was evident in any of the parameters analysed among the three groups by Mann-Whitney test (net change SNOT 22 P = 0.951; net change SNOT 1-12 P = 0.815; net change LKS P = 0.565; net change NPS P = 0.061).

Discussion

The treatment of refractory CRS is intensively debated in the literature, especially since biological drugs have shown excellent results in the treatment of asthma. While several RCTs have highlighted the efficacy of mAbs in CRSwNP [9-12], observational studies evaluating the response to biological treatments in real-life are limited [26-30].

Although an observational study may have several limitations, the application of clinical trial results to clinical practice is not often straightforward. Issues, such as restrictive

Table V. Differences in net change of selected scores between treatment groups.

	Anti-IgE group n = 11	Anti-IL5 group n = 20	Anti-IL5R group n = 9
	mean ± SD	mean ± SD	mean ± SD
Net change SNOT 22	24.6 ± 27.1	26.9 ± 20.6	25.3 ± 26.9
Net change SNOT 1-12	14 ± 14.3	16.9 ± 10.6	14.7 ± 16.3
Net change LKS	1.0 ± 1.5	0.2 ± 2.8	0.4 ± 2.5
Net change NPS*	0.1 ± 0.8	0.8 ± 1.4	-0.3 ± 1.2

SNOT: SinoNasal Outcome Test; LKS: Lund-Kennedy Score; NPS: Nasal Polyp Score
** Net change NPS was calculated only in the CRSwNP subgroup in each treatment arm.*

enrollment criteria, experimental design limitations, conflicts of interest (both financial and non-financial), publication bias and biological variability, can all underlie the disparity between the outcomes achieved from clinical trials compared to those observed in real-life [31].

For instance, exclusion criteria from clinical trials encompass the absence of nasal polyps or NPS lower than 5 [12], continuative use of high-dose OCS, treatment with another biologic in the previous 12 months, asthma exacerbations requiring hospitalisation within the period of screening [12], OCS and surgical intervention from 1 month before treatment until the end of the study, and use of nasal steroid therapies for two months after first dose [10].

Contrarily, the presented study group included both patients with CRSwNP (82.5%) and CRSsNP (17.5%); patients with nasal polyps had a baseline mean NPS of 2.6 ± 1.9; 6 patients (15%) underwent a sinonasal surgical procedure during mAb therapy, 18 patients (45%) were in chronic OCS treatment for control of airway exacerbations and 26 patients (65%) were in chronic nasal steroid therapy. In addition, a change in mAb therapy was observed in 7 patients in order to achieve better control of the lower airways: 5 patients (12.5%) switched from omalizumab to mepolizumab and 2 patients (5%) from mepolizumab to benralizumab at the time of enrollment in our study.

It follows that, considering the aforementioned exclusion criteria, most of our patients would not have been suitable for a RCT. All of the above, together with the associated non-respiratory comorbidities, explains the extreme variability of patients encountered in the daily practice.

Another element that further enriches our knowledge on the effectiveness of mAbs is the long-term follow-up. Our 52-week observation goes beyond previous literature experiences which evaluated patients at shorter times (16 weeks for omalizumab [11] and 25 weeks for mepolizumab [12]), providing a longer perspective on the effects of biological therapies in CRS.

Most of the RCTs published in the literature select endoscopic changes of nasal polyps as the primary outcome of treatment.

Gevaert et al. [11] reported a significant reduction in polyp size compared to baseline in the omalizumab group (P = 0.001), which also presented a significantly lower NPS than the placebo arm throughout the entire treatment period (P = 0.02). Another study by Gevaert et al. [10] reported a significant reduction of NPS in the mepolizumab group compared to placebo (P = 0.028). Bachert et al. [12] showed a significant higher probability of having a reduction of NPS in the mepolizumab group vs. placebo (P = 0.031). Differently, Pinto et al. [9] opted for changes in sinus opacification determined by CT scan as the primary outcome, reporting a significant reduction in inflammation for the omalizumab group from baseline (P = 0.043), without significant differences on net change across treatment groups (P = 0.391). NPS from baseline and net change across treatments did not show significant variations (P = 0.58).

Our evaluation of endoscopic parameters showed no significant differences in LKS (P = 0.124) and NPS (P = 0.130) between baseline and 52 weeks in the entire cohort; moreover, even the net change appeared quite small. Although, at a first glance, only anti-IL5 therapy was able to reduce NPS, this result should be considered with caution as it was strongly influenced by combination with surgical approaches.

It is proper to underline that mean baseline NPS in our cohort was clearly lower than in the aforementioned RCTs. This leads to the consideration that mAbs might be effective in polyp volume reduction, but not in their full reabsorption, so that beyond a certain shrinking threshold there is no further clinical improvement. Moreover, nasal polyp formation is known to depend on the complex interplay among different mechanisms orchestrated by a much wider panel of molecules than IgE or IL5. Likewise, the fact that LKS did not improve might imply that the impact of these specific drugs on nasal tissue remodeling in a broader sense (related to mucin production, extracellular matrix modifications, epithelial barrier functions) is somewhat limited [32].

Secondary endpoints included, among others, nasal symptoms. Pinto et al. [9] reported significant improvement in SNOT 20 with omalizumab (P < 0.05) from baseline, but there was no difference in the net change between omalizumab and placebo (P < 0.78); Gevaert et al. [11] reported a significant decrease in symptom scores for nasal congestion (P = 0.002), anterior rhinorrhoea (P = 0.003), hyposmia (P = 0.004), wheeze (P = 0.02) and dyspnoea (P = 0.02) and a significant improvement of Short-Form Health Questionnaire 36 (SF-36) in the omalizumab group (P = 0.02); Gevaert et al. [10] reported a non-statistically significant improvement of smell, postnasal drip and conges-

tion in patients treated with mepolizumab, while Bachert et al. [12] reported greater improvement with mepolizumab compared to placebo for SNOT 22 (P = 0.005) and individual symptoms such as rhinorrhoea (P < 0.001), mucus in throat (P < 0.001), nasal blockage (P = 0.002) and loss of smell (P < 0.001).

In our study, an improvement of symptoms was evident with a significant reduction of SNOT 22 (P < 0.001), SNOT 1-12 (P < 0.001) and individual symptoms such as nasal blockage (P < 0.001), rhinorrhoea (P < 0.021), hyposmia (P = 0.023), facial pain (P = 0.027) and ear fullness (P = 0.006). However, subgroup analysis showed similar improvements only for some of these symptoms and not shared by all treatment arms. It is reasonable to think that this discrepancy is mainly due to the limited number of individuals in each subgroup.

It clearly emerges from these comparisons that, in real-life, the classic primary endpoint of RCTs was not achieved, even though overall symptom improvement was statistically significant. One possible explanation is that patients treated with mAbs for asthma, in which a significant reduction in pulmonary exacerbations and an overall improvement of lower airways obstruction occurs, may also perceive an improvement in nasal symptoms that is not necessarily related to objective nasal findings [33,34].

A further consideration is unavoidable. It is reasonable to ask whether the only improvement in patient-reported symptoms is sufficient to define a good outcome or whether the lack of a significant improvement in endoscopic findings may be related to a faulty choice of mAb. In other words, are we satisfied only with improvement in symptoms or should we consider changing therapy when no endoscopic improvement is observed? According to current guidelines, a "moderate response" to a biological treatment (fulfillment of 3-4 criteria) would theoretically be achieved regardless of variations in nasal polyp size and only an "excellent response" would be defined on the fulfillment of all 5 evaluation criteria [17].

Coupling the objective and subjective aspects of the disease, together with other items as proposed by the EPOS multimodal scale for CRS control (i.e. sleep disturbance or fatigue, systemic medications needed to control disease) [17,18], we were able to show a significant difference on control of nasal disease between baseline and 52 weeks in all treatment groups. Interestingly, although all patients in the cohort were (for obvious reasons) affected by severe asthma, we found that 17.5% of patients presented with a partly controlled CRS at baseline. This suggests the possible coexistence of mild or moderate nasal disease in patients with severe lower airways comorbidity and, at the same time, the potential association of severe forms of CRS with mild or moderate asthma (unpublished data). Moreover, patients presenting with this latter combination are penalised because they are currently beyond the prescriptive limits of mAbs therapy in Italy.

Some reflections arise about the degree of nasal disease control as proposed by EPOS: the presence of particular symptoms, such as refractory smell loss and rhinorrhoea, is very common in all CRS stages, despite good overall control of disease; sleep disturbance or fatigue may be related to other general conditions that are not strictly connected to CRS; endoscopic findings of healthy or almost healthy mucosa is limited in clinical practice to very mild forms of CRS. This would mean that a revised and more accurate definition of disease control might down-stage patients defined as uncontrolled and not responsive to treatments.

No serious AEs were reported in the entire cohort, but minor AEs occurred in 25 patients (62.5%). The most common were nasopharyngitis (42.5%), oropharyngeal pain (37.5%) and back pain (27.5%). These findings appear concordant with previous reports [10].

The limits of our study first encompass the small sample size and its diversity in terms of patient characteristics and treatments. Larger and more uniform series are needed to verify these preliminary results.

Second, all patients were on mAb treatment and therefore we lack a control group.

Subgroup analysis between CRSwNP and CRSsNP, although conceptually consistent with the indications for the use of biological drugs in CRS, was not conducted because the size of the CRSsNP sample was too small for significant statistical considerations. In the literature, this dichotomous classification is increasingly cornered in favour of an endotype-based definition from which it emerges that these two phenotypes may share the same inflammatory mechanisms [35] and, thus, be potentially manageable in a similar manner.

We have shortcomings regarding biological parameters: peripheral eosinophil count was missing for some patients, peripheral IgE were dosed only once before starting treatment in the anti-IgE group, other biomarkers of type 2 inflammation (i.e. tissue eosinophil count, serum periostin, exhaled and nasal nitric oxide) were unavailable.

Moreover, we were not able to assess radiologic changes after treatment. Indeed, CT scan are repeated in daily practice only in refractory cases in expectation of a surgical procedure or a clinical need.

Although all patients self-reported an overall improvement of asthma-related quality of life, this feedback was not verified through validated questionnaires.

Lastly, we did not extensively evaluate the impact of surgery on outcomes; although mAb treatment groups did not

differ in the prevalence of previous endoscopic sinus surgery (P = 0.431), the variability in the type of surgical procedure did not allow comparisons between patients. For the same reason, thorough endoscopic assessment of outcomes of sinus surgery, which include the evaluation of patency of ostia, presence of scarring, characteristics of nasal secretions (other than LKS items) and microbiological data, was not reported.

Conclusions

The upcoming introduction of biologics in clinical practice may represent a promising treatment for refractory CRS. However, many issues are still open. Among these, RCTs published to date focus only on the CRSwNP phenotype, while CRSsNP are also known to present as a consequence of similar inflammatory pathways.

The present observational study showed an improvement of nasal symptoms in long-term follow-up that was not associated with significant variations in endoscopic findings. These preliminary results, of course, need to be verified in more extensive real-life studies. Moreover, we still lack data about the cost-effectiveness of these therapies, their relationship with surgery (interdependent or exclusive) and an accurate set of selection criteria and predictive biomarkers. Lastly, we do not exclude that in the near future other treatment options, upstream in the inflammatory cascade, will be developed that target the entire spectrum of mechanisms underlying multifactorial diseases, like CRS and asthma.

Acknowledgements

Andrea Preti is a PhD student of the “Sperimental and translational medicine” course at University of Insubria.

References

1 Schleimer RP. Immunopathogenesis of chronic rhinosinusitis and nasal polyposis. Annu Rev Pathol 2017;12:331-57. https://doi.org/10.1146/annurev-pathol-052016-100401

2 Cao PP, Wang ZC, Schleimer RP, et al. Pathophysiologic mechanisms of chronic rhinosinusitis and their roles in emerging disease endotypes. Ann Allergy Asthma Immunol 2019;122:33-40. https://doi.org/10.1016/j.anai.2018.10.01

3 Krouse JH, Krouse HJ. Asthma, rhinitis, and the unified airway. ORL Head Neck Nurs 2013;31:6-10.

4 van der Veen J, Seys SF, Timmermans M, et al. Real-life study showing uncontrolled rhinosinusitis after sinus surgery in a tertiary referral centre. Allergy 2017;72:282-90.https://doi.org/10.1111/all.12983

5 Calus L, Van Bruaene N, Bosteels C, et al. Twelve-year follow-up study after endoscopic sinus surgery in patients with chronic rhinosinusitis with nasal polyposis. Clin Transl Allergy 2019;9:30. https://doi.org/10.1186/s13601-019-0269-4

6 Edris A, De Feyter S, Maes T, et al. Monoclonal antibodies in type 2 asthma: a systematic review and network meta-analysis. Respir Res 2019;20:179. https://doi.org/10.1186/s12931-019-1138-3

7 Ren L, Zhang N, Zhang L, et al. Biologics for the treatment of chronic rhinosinusitis with nasal polyps - state of the art. World Allergy Organ J 2019;12:100050. https://doi.org/10.1016/j.waojou.2019.100050

8 Kartush AG, Schumacher JK, Shah R, et al. Biologic agents for the treatment of chronic rhinosinusitis with nasal polyps. Am J Rhinol Allergy 2019;33:203-11. https://doi.org/10.1177/1945892418814768

9 Pinto JM, Mehta N, Di Tineo M, et al. A randomized, double-blind, placebo-controlled trial of anti-IgE for chronic rhinosinusitis. Rhinology 2010;48:318-24. https://doi.org/10.4193/Rhin09.144

10 Gevaert P, Van Bruaene N, Cattaert T, et al. Mepolizumab, a humanized anti-IL-5 mAb, as a treatment option for severe nasal polyposis. J Allergy Clin Immunol 2011;128:989-95.e1-8. https://doi.org/10.1016/j.jaci.2011.07.056

11 Gevaert P, Calus L, Van Zele T, et al. Omalizumab is effective in allergic and nonallergic patients with nasal polyps and asthma. J Allergy Clin Immunol 2013;131:110-6.e1. https://doi.org/10.1016/j.jaci.2012.07.047

12 Bachert C, Sousa AR, Lund VJ, et al. Reduced need for surgery in severe nasal polyposis with mepolizumab: Randomized trial. J Allergy Clin Immunol 2017;140:1024-31.e14. https://doi.org/10.1016/j.jaci.2017.05.044

13 Global Initiative for Asthma. Global strategy for asthma management and prevention. 2017. Available from: www.ginasthma.org

14 Global Initiative for Asthma. Global strategy for asthma management and prevention. 2018. Available from: www.ginasthma.org

15 Global Initiative for Asthma. Global strategy for asthma management and prevention. 2019. Available from: www.ginasthma.org

16 Global Initiative for Asthma. Global strategy for asthma management and prevention. 2020. Available from: www.ginasthma.org

17 Fokkens WJ, Lund VJ, Hopkins C, et al. European position paper on rhinosinusitis and nasal polyps 2020. Rhinology 2020;58(Suppl S29):1-464. https://doi.org/10.4193/Rhin20.600

18 Fokkens WJ, Lund VJ, Mullol J, et al. European position paper on rhinosinusitis and nasal polyps 2012. Rhinol Suppl 2012;23:1-298.

19 Castelnuovo P, Bandi F, Preti, et al. Implementing strategies for data collection in chronic rhinosinusitis. Acta Otorhinolaryngol Ital 2018;38:222-4. https://doi.org/10.14639/0392-100X-1993

20 Akdis CA, Hellings, PW, Agache I; European Academy of Allergy and Clinical Immunology, Editors. Global atlas of allergic rhinitis and chronic rhinosinusitis. Zurich, Switzerland: European Academy of Allergy and Clinical Immunology; 2015.

21 Mozzanica F, Preti A, Gera R, et al. Cross-cultural adaptation and validation of the SNOT-22 into Italian. Eur Arch Otorhinolaryngol 2017;274:887-95. https://doi.org/10.1007/s00405-016-4313-x

22 Gallo S, Russo F, Mozzanica F, et al. Prognostic value of the Sinonasal Outcome Test 22 (SNOT-22) in chronic rhinosinusitis. Acta Otorhinolaryngol Ital 2020;40:113-21. https://doi.org/10.14639/0392-100X-N0364

23 Gelardi M, Piccininni K, Quaranta N, et al. Olfactory dysfunction in patients with chronic rhinosinusitis with nasal polyps is associated with clinical-cytological grading severity. Acta Otorhinolaryngol Ital 2019;39:329-35. https://doi.org/10.14639/0392-100X-2426

24 Lund VJ, Kennedy DW. Staging for rhinosinusitis. Otolaryngol Head Neck Surg 1997;117(3 Pt 2):S35-40. https://doi.org/10.1016/s0194-5998(97)70005-6

25 Meltzer EO, Hamilos DL, Hadley JA. Rhinosinusitis: developing guidance for clinical trials. J Allergy Clin Immunol 2006;118(5 Suppl):S17-61. https://doi.org/10.1016/j.jaci.2006.09.005

26 Bidder T, Sahota J, Rennie C, et al. Omalizumab treats chronic rhi-

nosinusitis with nasal polyps and asthma together-a real life study. Rhinology 2018;56:42-5. https://doi.org/10.4193/Rhin17.139

[27] Numata T, Nakayama K, Utsumi H, et al. Efficacy of mepolizumab for patients with severe asthma and eosinophilic chronic rhinosinusitis. BMC Pulm Med 2019;19:176. https://doi.org/10.1186/s12890-019-0952-1

[28] Tsurumaki H, Matsuyama T, Ezawa K, et al. Rapid effect of benralizumab for hypereosinophilia in a case of severe asthma with eosinophilic chronic rhinosinusitis. Medicina (Kaunas) 2019;55:336. https://doi.org/10.3390/medicina55070336

[29] Rowan NR, Naclerio RM. Persistence of sinonasal disease despite mepolizumab. J Allergy Clin Immunol Pract 2020;8:1550-5. https://doi.org/10.1016/j.jaip.2020.01.049

[30] Jandus P, Harr T, Soyka MB, et al. Efficacité de l'omalizumab dans la polypose nasale: à propos de deux cas [The efficacy of omalizumab in the treatment of chronic rhinosinusitis with nasal polyps: a discussion of 2 refractory cases]. Rev Med Suisse 2019;15:1748-51.

[31] Zarbin M. Real life outcomes vs. clinical trial results. J Ophthalmic Vis Res 2019;14:88-92. https://doi.org/10.4103/jovr.jovr_279_18

[32] Shay AD, Tajudeen BA. Histopathologic analysis in the diagnosis and management of chronic rhinosinusitis. Curr Opin Otolaryngol Head Neck Surg 2019;27:20-4. https://doi.org/10.1097/MOO.0000000000000510

[33] Huang CC, Chang PH, Wu PW, et al. Impact of nasal symptoms on the evaluation of asthma control. Medicine (Baltimore) 2017;96:e6147. https://doi.org/10.1097/MD.0000000000006147

[34] Chan R, RuiWen Kuo C, Lipworth B. Disconnect between effects of mepolizumab on severe eosinophilic asthma and chronic rhinosinusitis with nasal polyps. J Allergy Clin Immunol Pract 2020;8:1714-6. https://doi.org/10.1016/j.jaip.2020.01.009

[35] Delemarre T, Holtappels G, De Ruyck N, et al. Type 2 inflammation in chronic rhinosinusitis without nasal polyps: another relevant endotype. J Allergy Clin Immunol 2020;146:337-43.e6. https://doi.org/10.1016/j.jaci.2020.04.040

ACTA OTORHINOLARYNGOLOGICA ITALICA 2020;40:444-449; doi: 10.14639/0392-100X-N0776

Vestibology

Evaluation of a large cohort of adult patients with Ménière's disease: bedside and clinical history

Sindrome di Ménière: valutazione dell'esame vestibolare e della storia clinica in un'ampia popolazione

Roberto Teggi[1,2], Rosa Alessia Battista[1,2], Federica Di Berardino[3], Marco Familiari[1,2], Iacopo Cangiano[2], Omar Gatti[1], Mario Bussi[1,2]

[1] Department of Otolaryngology Head & Neck Surgery, IRCCS San Raffaele Scientific Institute, Milan, Italy; [2] Vita-Salute San Raffaele University, Milan, Italy; [3] Audiology Unit, Dept of Clinical Sciences and Community Health and Dept. of Specialistic Surgical Sciences, Fondazione IRCCS Cà Granda, Ospedale Maggiore Policlinico, University of Milan, Italy

SUMMARY

Objective. The purpose of this study was to assess vestibular findings and clinical history in a large cohort of patients affected by Ménière's disease.

Methods. We retrospectively analysed 511 adult patients fulfilling criteria for definite unilateral Ménière's disease according to Barany Society. Thorough clinical history, audiometric exam, central nervous system MRI, quantification of serum autoantibodies and complete vestibular function test were performed.

Results. Mean age at clinical record was 55.4 years, while age at onset of the first vertigo attack was 47.4 ± 14.3 years. Ménière's disease overlapped with migraine in 43.4% of patients. In 31.7% of cases, positivity was found for at least one autoantibody. Forty-nine patients (9.6%) had family history for Ménière's disease. Bedside examination resulted in 14.7% positivity for video head impulse test, 58.9% for skull vibration-induced nystagmus, 38.7% for the positional test and 23.1% for the post head shaking test. Complete negative examination was reported in 115 cases.

Conclusions. Ménière's disease was seen to present a characteristic phenotypic pattern in our cohort, confirming the crucial role of thorough anamnesis and bedside examination in diagnosis.

KEY WORDS: Ménière's disease, migraine, autoimmunity, family history, vestibular function tests

RIASSUNTO

Obiettivo. *Analizzare un'ampia casistica di pazienti affetti da sindrome di Ménière con particolare attenzione al dato anamnestico ed ai test di funzione vestibolare.*

Metodi. *Sono stati raccolti retrospettivamente i dati di 511 pazienti affetti da sindrome di Ménière monolaterale definita, che soddisfacevano i criteri della Barany Society. Ogni paziente è stato sottoposto a raccolta anamnestica, esame audiometrico tonale, RM encefalo, test di autoimmunità ed esame otovestibolare.*

Risultati. *L'età media alla presentazione clinica è stata di 55,4 anni mentre l'età del primo episodio di vertigine è risultata essere 47,4 ± 14,3. Il 43,4% della popolazione soffre contestualmente di emicrania. Nel 31,7% dei casi è stata quantificata una positività di almeno un autoanticorpo. Quarantanove pazienti hanno riferito un familiare affetto da possibile sindrome di Ménière. La video head impulse è risultata positiva nel 14,7%, il test vibratorio nel 58,9%, 38,6% il test posizionale nel 38,7% e la HST nel 23,1%; una completa negatività ai test vestibolari è stata rilevata in 115 casi.*

Conclusioni. *La sindrome di Ménière è spesso associata ad un fenotipo clinico e strumentale suggestivo che conferma il ruolo cruciale di una attentata raccolta anamnestica e dell'esame vestibolare nella diagnosi.*

PAROLE CHIAVE: *sindrome di Ménière, emicrania, autoimmunità, familiarità, esame vestibolare*

Received: April 2, 2020
Accepted: July 16, 2020

Correspondence
Roberto Teggi
San Raffaele Hospital, via Olgettina 60, 20132 Milan, Italy
Tel. +39 02 26433522. Fax +39 02 26433508
E-mail: teggi.roberto@hsr.it

Funding
None.

Conflict of interest
The Authors declare no conflict of interest.

How to cite this article: Teggi R, Battista RA, Di Berardino F, et al. Evaluation of a large cohort of adult patients with Ménière's disease: bedside and clinical history. Acta Otorhinolaryngol Ital 2020;40:444-449. https://doi.org/10.14639/0392-100X-N0776

© Società Italiana di Otorinolaringoiatria e Chirurgia Cervico-Facciale

OPEN ACCESS

This is an open access article distributed in accordance with the CC-BY-NC-ND (Creative Commons Attribution-Non-Commercial-NoDerivatives 4.0 International) license. The article can be used by giving appropriate credit and mentioning the license, but only for non-commercial purposes and only in the original version. For further information: https://creativecommons.org/licenses/by-nc-nd/4.0/deed.en

Introduction

Ménière's disease (MD) is an inner ear disorder characterised by episodic vertigo, usually preceded by cochlear symptoms: fluctuating hearing loss, tinnitus and aural fullness [1]. Increased endolymphatic volume (hydrops) is the commonly accepted pathophysiological mechanism, and this finding is also supported by newly developed imaging techniques [2,3]. However, the aetiology of the disorder is not fully understood. Recent publications have focused on the possibility of differentiating subgroups of unilateral MD subjects characterised by specific clinical features [4]. Moreover, since 8-9% of MD patients have positive family history [4], this highlights the possibility to develop new biomarkers including genetic ones [5,6].

Currently, diagnosis mainly relies on clinical history and audiometric exam; in 2015, the Barany Society proposed the following diagnostic criteria for definite MD [7].

A. Two or more spontaneous episodes of vertigo each lasting 20 minutes to 12 hours.
B. Audiometrically documented low to medium frequency sensorineural hearing loss in one ear, defining the affected ear, on at least one occasion before, during, or after one of the episodes of vertigo.
C. Fluctuating aural symptoms (hearing, tinnitus or fullness) in the affected ear.
D. Not better accounted for by another vestibular diagnosis.

MD presents in association with two other conditions: migraine and autoimmune disorders. In fact, around 50% of MD patients also suffer from migraine [8], and proteomics studies support the possibility of autoimmunity as a potential mechanism predisposing to MD [9].

Audiometric exam is mandatory for diagnosis of MD, while few studies have been published on vestibular findings during bedside examination. The purpose of the present study was to assess clinical history and vestibular findings in MD patients with 4 tests, namely Video Head Impulse Test (Video-HIT), Head Shaking Test (HST) and positional and Skull Vibration Test, performed outside attacks of vertigo.

Materials and methods

Study cohort

In our retrospective study the sample was composed of 511 adult patients; data were obtained from records of patients from 2008 to 2019. The study received ethical approval by an internal committee (No. GO/URC/ER/mm prot 762). Patients were included if they fulfilled criteria for definite unilateral MD according to the Barany Society; in subjects enrolled before 2015 a retrospective analysis of data confirmed Barany criteria [7]. Evaluation was made in a vertigo-free period (at least 15 days from the last vertigo attack). At inclusion all patients presented unilateral MD, while during different follow-up 21 (4.1%) of them developed bilateral MD.

Clinical history was collected with particular attention to migraine. According to International Headache Society (HIS) criteria [10], migrainous headaches typically last between 4 and 72 h and present at least two of the following features:

- unilateral;
- pulsating;
- moderate or severe intensity of pain;
- aggravated by, or resulting in the avoidance of, routine physical activity.

All patients underwent audiometric exam confirming a low to middle frequencies gap between the two thresholds in at least 2 frequencies, and concomitant vestibular evaluation, as routinely done in outpatients presenting for vertigo. Data were stored in a protected database. Cases were excluded if surgically treated before the examination or if they had undergone intratympanic therapy with steroids or gentamicin; delayed hydrops were not included. All subjects underwent central nervous system MRI with contrast focused on the cerebello-pontine angle to rule out 8th nerve schwannoma. All subjects were asked to assess autoimmunity with a panel of anti-nucleus (which were considered positive when with a title at least of 1:160), anti-neutrophil cytoplasmic, anti-thyroids and anti-cardiolipin autoantibodies.

One-hundred and fifty-five patients were also included in another genetic study on MD [11].

Bedside vestibular examination

Nystagmus was studied with video Frenzel goggles (Interacoustics - Assens - Denmark); spontaneous nystagmus was assessed with the patient seated in a clinical chair, in primary position and eyes rotated 15° on the right and left side. Positional nystagmus was assessed in the supine position with the head turned 90° on both sides.

Post head shaking test (HST) was performed with the patient sitting in a clinical chair with the head leaning down by 30°; nystagmus was studied with video Frenzel goggles. The patient's head was vigorously rotated for 20 times on the horizontal plane with a maximum amplitude around 30-40°. Post HST nystagmus was recorded for 1 minute and was considered positive when nystagmus lasting at least 5 seconds was detected.

Skull vibration test (Skull Vibration Induced Nystagmus – SVIN) was performed at 100 Hz with a commercially available system (VVIB - Synapsis). Stimuli were applied perpendicularly to the skin over the mastoid process, posteriorly to the auricle, at the level of the external acoustic meatus with

a force around 1 kg; three stimulation trials were performed on each mastoid, lasting 5-10 seconds each. Eye movements were studied with video Frenzel goggles and visual fixation of both eyes was inhibited. The test was considered positive when a horizontal nystagmus, always beating on the same side, was elicited in all 6 trials; it was considered "paretic" when directed toward the healthy side, and "irritative" when beating toward the affected side [12].

Video head impulse test (video-HIT) was performed only on the horizontal plane with a commercially available system (ICS Impulse, Otometrics, Taastrup, Denmark). Subjects were asked to remove spectacles at least 5 minutes before examination and calibration was made before tests. The calibration was also checked in the horizontal canal plane with slow sinusoidal movement of the head while the patient was asked to fixate the target. In this way, at least at low head velocity, we could confirm that head-eye velocity traces were overlapping and minimised the risk linked to the presence of square waves. Trials with blinks and outliers were automatically excluded. Patients in whom recordings demonstrated that eye movements always preceded head movements, even after attempts to improve goggle fit, were not included [13]. We considered the exam pathological when VOR gain was lower than 0.80 and/or when corrective saccades were demonstrated, while normal values were detected on the contralateral side.

All procedures were performed by a senior neurotologist.

Statistical analysis

Quantitative variables are presented as mean ± standard deviation and categorical as rate on the total sample. A P value < 0.05 was considered statistically significant. Spearman's test was performed to investigate the association between different variables. A linear regression model was calculated to assess the independent role of migraine, autoimmunity and family history on age of onset of vertigo; a linear regression was also performed to assess the independent role of age and duration of the disorder on different clinical signs. Chi-square and odds ratio were calculated to establish the different frequencies of clinical signs in subjects with and without a comorbidity for migraine and autoimmune disorders. We used SPSS software version 22.0 (SPSS, Inc., Chicago, IL, USA) for statistical analyses.

Results

Study population

In our cohort of 511 MD patients, 260 (50.8%) were females. Mean age at presentation was 55.4 ± 14.1 years (range 18-86) and age at first vertigo attack was 47.4 ± 14.3 years. Duration (the period between the first vertigo attack and inclusion) of disease was 8.3 ± 8.1 years. The distribution of age of the first vertigo in the sample is summarised in Figure 1. All patients reported several vertigo spells with nausea/vomiting; audiometric exam presented a hearing loss on low frequencies without differences between thresholds in 104 cases (20.3%), while all other subjects presented a flat threshold in the diseased ear. Twenty-six patients (5.1%) had positive history for Tumarkin attacks. The age of these subjects was higher than the entire sample (71 ± 5, $p < 0.01$). A Spearman test showed correlation with both patient age (r_s 0.25, $p = 0.0002$) and duration of vertigo attacks (r_s 0.18, $p = 0.02$).

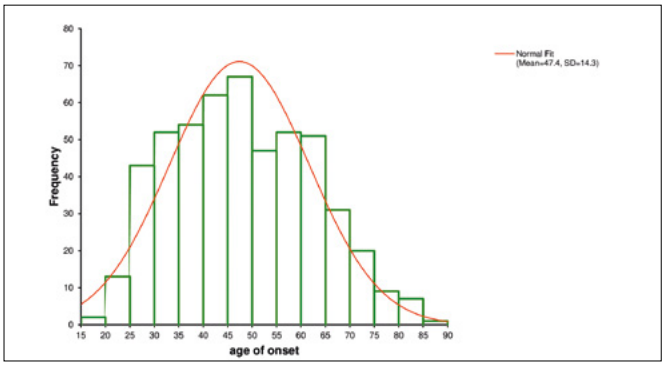

Figure 1. Age of onset of the first vertigo attack.

Comorbidities

In this cohort, 222 (43.4%) suffered from migrainous headache; 27 patients (12.1% of migraineurs) referred visual aura. The onset of the first migrainous headache was 27 ± 6.3 years. In all subjects except 4 the headache preceded the onset of vertigo. Micro-ischaemic lesions were detected on central nervous system MRI in 123 patients (24%).

Positivity for at least one autoantibodies was detected in 162 subjects (31.7%). The most common autoimmune disorders were thyroiditis (n = 65, 12.7%), undifferentiated connective tissue disease (n = 10, 2%) and rheumatoid arthritis (n = 6, 1.2%); in the remaining 81 (16%) patients, positivity for autoantibodies was an occasional finding and patients did not report clinical signs of an autoimmune disorder; consultation with a rheumatologist was asked in all subjects. Positivity for at least one autoantibody was more represented in the sample of migraineurs (χ^2 $p = 0.001$; odds ratio 0.53, 95% CI 0.36-0.77).

Forty-nine patients (9.6%) had family history, and in 20 a first-degree relative reported episodic vertigo and hearing loss (mother/father or brother/sister).

A linear model demonstrated that both migraine and family history were predictive for earlier onset of the vertigo. The results are reported in Table I.

Table I. Age of onset of the first vertigo attack according to different variables.

	Coefficient	95% CI		SE	T Statistic	p
Migraine	-10.36	-12.96	to -7.76	1.323	-7.83	< 0.0001
Family history	-4.997	-9.022	to -0.971	2.0490	-2.44	0.0151
Autoimmunity	-0.9883	-3.5718	to 1.5953	1.31501	-0.75	0.4527
Sex	-2.142	-4.721	to 0.436	1.3125	-1.63	0.1032

Data show a linear model considering the age of onset of vertigo as a dependent variable and migraine, family history and positivity for at least one autoantibody as independent variables. CI: Confidence Interval; SE: Standard Error

Bedside examination

Positive video HIT was found in 75 patients (14.7%), positive SVIN in 301 (58.9%), positive positional test in 198 (38.7%) and post HST in 118 (23.1%); in 115 subjects all clinical signs were negative. Only 2 patients with positive SVIN demonstrated an "irritative" nystagmus beating toward the diseased ear. Patients with positive vestibular tests in the entire sample and in subsamples, according to comorbidities of migraine or autoimmune disorders, are reported in Table II. Among 198 patients with positive positional test, 169 showed a monopositional apogeotropic nystagmus turning the head on the affected side, while in 29 a bipositional apogeotropic nystagmus was detected; all were characterised by few/no latency, low frequency, long lasting nystagmus (more than 3 minutes) and no vertigo. When asked, patients did not refer positioning vertigo in the previous days, possibly related to benign paroxysmal positional vertigo. Statistical analyses demonstrated that positive positional tests (n = 198, χ^2 p = 0.04; odds ratio = 1.43, 95% CI 1.00-2.05), as well as a bipositional apogeotropic nystagmus (n = 19, χ^2 p = 0.0016; odds ratio = 2.6, 95% CI 1.18-5.72,) were more frequent in migraineurs than in general sample. The duration of vertigo spells had no correlation with the clinical findings.

Discussion

Herein, we mainly focused on clinical history and comorbidities, specifically family history, migraine and autoimmunity (as routinely done in our centre), along with bedside examination.

We found an overlap between migraine and MD, demonstrated in 43.4% of MD subjects, while a recent study estimated the lifetime prevalence of migraine in general population to be around 10% [14]. The association of MD and migraine is still under debate; in a previous work, this comorbidity was reported in 56% of MD subjects [8]. Further works revealed a lower rate of migraineurs[4] or showed no association between the two disorders, even if the same author reported that symptoms suggestive of migraine may co-exist in patients with hydropic ear [15].

In all, 9.6% of all cases referred family history, which is in accordance with previously reported data [16,17]; however, we investigated relatives with episodic vertigo and hearing loss and it was impossible to confirm that cases were at least probable MD.

Interesting data was also seen considering the autoimmunity spectrum. Positivity for at least one autoantibody was detected in 31.7% of the sample, even if an autoimmune disorder was diagnosed in only 15.9% of these patients, with thyroiditis being the most frequent. Positivity for a single autoantibody was more frequent in migraineurs. The observed value (15.9%) of MD subjects with an autoimmune disorder is consistent with other published studies [4], reported to be around 17% in unilateral MD and over 20% in bilateral MD [18]. Interestingly, the number of patients with positivity for at least one antibody was 31.7%, which is lower than the previously reported percentage (38%) by other authors for only anti-thyroid autoantibodies [19]. The association between inner ear disorders and vertigo has been widely studied in the last years and it should be underlined that autoimmunity has been proposed as a predis-

Table II. Bedside examination results in the entire cohort and subgroups.

	Total sample (n = 511)	Migraineurs (n = 222)	Autoimmune + (n = 162)	p
Video - HIT	75 (14.7%)	25 (11.3%)	23 (14.2%)	n.s.
SVIN	301 (58.9%)	111 (50%)	94 (58%)	n.s.
Positional test	198 (38.7%)	96 (43.2%)	67 (41.3%)	n.s.
Post HST	119(23.1%)	47 (21.2%)	36 (22.2%)	n.s.

Total number and percentage of patients with positive vestibular tests (Video HIT: Video Head Impulse Test; SVIN: Skull Vibration Induced Nystagmus; HST; Head Shaking Test) in the total population and according to Migraineurs and patients with positivity for at least one of the autoantibodies (Autoimmune +).

posing factor to develop MD; this hypothesis is supported by the fact that hydrops can be induced experimentally by injection of antigens or monoclonal antibodies and the deposition of circulating immune complexes may produce inflammation and interfere with the filtering capability of the endolymphatic sac [20,21].

Interesting results can be obtained by clinical signs collected outside vertigo spells. We found a positive video-HIT in 14.7% of subjects. These results substantially confirm those of previous works, reporting low percentages of positive video HIT ranging between 54.5% [20] and 0% [22,23] in patients beyond vertigo attack. It can be speculated that video-HIT studies rapid vestibular acceleration, thus focusing on irregular neurons and phasic type-1 hair cells whose activity can be spared in hydrops [24].

SVIN was seen to be a more sensitive test, provoking a consistent nystagmus beating toward the unaffected side in 301 patients (58.7) except for two cases in which the nystagmus direction was toward the hydropic side. SVIN is a newly proposed test that is able to reveal nystagmus in patients with asymmetry in vestibulo-oculomotor reflex. The slow phase velocity of SVIN seemed to be correlated with that of caloric tests, suggesting the possibility that skull vibration mainly concerns the horizontal canal [12]. Moreover, other authors demonstrated a correlation between SVIN and caloric tests when caloric hypofunction was higher than 50% [25]. Finally, it has been reported that vibration on mastoid or neck muscles induced a shift of the subjective visual vertical, suggesting an induced deficit of the otolithic organs or vertical semicircular canals [26]. The literature is poor in this area. Hong et al. reported a positive SVIN in 71% of MD subjects beating toward the lesion side in 27% of cases [26]. Dumas et al. described a SVIN in 71% of MD patients (most observed in a pre-attack or a period close to a recent attack) with modified caloric test results in 64% [12]. We detected a lower percentage of positive patients with this test; however, it should be noted that previous investigations included patients studied immediately after a vertigo attack.

Finally, little has been published about positional tests in MD. In our cohort, 198 patients (38.7%) showed a positive positional test, detecting apogeotropic nystagmus in 169 of them when lying on the affected side. In 29 cases (5.6%), a smooth bipositional apogeotropic nystagmus was detected, without vertigo. Several hypotheses can be made on this finding. It could be hypothesised that the presence of a small otoconial mass in a lateral canal, unable to provoke a consistent nystagmus (even if patients denied positional nystagmus in the previous days), may be the causal factor of the finding, although a "heavy or light cupola" mechanism cannot be excluded. Finally, since a consistent part of our sample was composed of migraineurs and positional nystagmus is the most common finding in vestibular migraine (VM), it could be assumed that a proportion might experience attacks of both hydrops and VM, and the clinical finding may be related to the latter [27]. The increased rate of positional nystagmus in the subsample of migraineurs seems to support this hypothesis.

Data from our study support the hypothesis that SVIN has a higher sensitivity to detect a vestibular deficit in MD outside a vertigo attack, while HIT is more frequently normal; the finding is not inconsistent with the possibility that a discrepancy between the 2 tests may be useful in the diagnostic pathway. Further studies can assess if a dissociation between the 2 tests may be a peculiar characteristic of MD. Moreover, SVIN mainly detect a deficit of the lateral canal function; other tests, ocular and cervical VEMPs, are promising in studying macular function, above all when performed with sounds at different frequencies and studying the tuning curve of responses, thus allowing a mapping of all parts of the inner ear [28,29].

Some weak points in our investigation should be underlined. For example, we were unable to retrieve data about all comorbidities or about the number of crises in the last 6 months. On the other hand, even though further studies are needed, our data are not inconsistent with the hypothesis that skull vibration can be easy to perform and fast to orient the clinician towards diagnosis of a hydropic form.

Conclusions

Thorough clinical history and careful bedside vestibular examination can orientate the clinician's suspicions towards MD, thus guiding and confirming definite diagnosis.

References

1. Sajjadi H, Paparella MM. Meniere's disease. Lancet 2008;372:406-14. https://doi.org/10.1016/S0140-6736(08)61161-7
2. Merchant SN, Adams JC, Nadol JB Jr. Pathophysiology of Meniere's syndrome: are symptoms caused by endolymphatic hydrops?. Otol Neurotol 2005;26:74-81. https://doi.org/10.1097/00129492-200501000-00013
3. Ito T, Inui H, Miyasaka T, et al. Endolymphatic volume in patients with meniere's disease and healthy controls: three-dimensional analysis with magnetic resonance imaging. Laryngoscope Investig Otolaryngol 2019;4:653-8. https://doi.org/10.1002/lio2.313
4. Frejo L, Martin-Sanz E, Teggi R, et al. Extended phenotype and clinical subgroups in unilateral Meniere disease: a cross-sectional study with cluster analysis. Clin Otolaryngol 2017;42:1172-80. https://doi.org/10.1111/coa.12844
5. Requena T, Espinosa-Sanchez JM, Cabrera S, et al. Familial clustering and genetic heterogeneity in Meniere's disease. Clin Genet 2014;85:245-52. https://doi.org/10.1111/cge.12150
6. Teggi R, Carpini SD, Zagato L. Endolymphatic hydrops and ionic transporters: genetic and biohumoral aspects. J Neurol 2019;266(Suppl 1):47-51. https://doi.org/10.1007/s00415-019-09399-6

7 Lopez-Escamez JA, Carey J, Chung WH, et al. Diagnostic criteria for Menière's disease. J Vestib Res 2015;25:1-7. https://doi.org/10.3233/VES-150549

8 Radtke A, Lempert T, Gresty MA, et al. Migraine and Ménière's disease: is there a link? Neurology 2002;59:1700-4. https://doi.org/10.1212/01.wnl.0000036903.22461.39

9 Kim SH, Kim JY, Lee HJ, et al. Autoimmunity as a candidate for the etiopathogenesis of Meniere's disease: detection of autoimmune reactions and diagnostic biomarker candidate. PLoS One 2014;9:e111039. https://doi.org/10.1371/journal.pone.0111039.

10 Headache Classification Committee of the International Headache Society (IHS). The International Classification of Headache Disorders, 3rd edition (beta version). Cephalalgia 2013;33:629-808. https://doi.org/10.1177/0333102413485658

11 Teggi R, Zagato L, Delli Carpini S, et al. Genetics of ion homeostasis in Ménière's Disease. Eur Arch Otorhinolaryngol 2017;274:757-63. https://doi.org/10.1007/s00405-016-4375-9

12 Dumas G, Curthoys IS, Lion A, et al. The skull vibration-induced nystagmus test of vestibular function - a review. Front Neurol 2017;8:41. https://doi.org/10.3389/fneur.2017.00041

13 Versino M, Colagiorgio P, Sacco S, et al. Artifact avoidance for head impulse testing. Clin Neurophysiol 2014;125:1071-3. https://doi.org/10.1016/j.clinph.2013.09.024

14 Woldeamanuel YW, Cowan RP. Migraine affects 1 in 10 people worldwide featuring recent rise: A systematic review and meta-analysis of community-based studies involving 6 million participants. J Neurol Sci 2017;372:307-15. https://doi.org/10.1016/j.jns.2016.11.071

15 Gürkov R, Jerin C, Flatz W, et al. Clinical manifestations of hydropic ear disease (Menière's) [published correction appears in Eur Arch Otorhinolaryngol 2019;276:619-20]. Eur Arch Otorhinolaryngol 2019;276:27-40. https://doi.org/10.1007/s00405-018-5157-3

16 Frejo L, Giegling I, Teggi R, et al. Genetics of vestibular disorders: pathophysiological insights. J Neurol 2016;263(Suppl 1):S45-53. https://doi.org/10.1007/s00415-015-7988-9

17 Hietikko E, Kotimäki J, Sorri M, et al. High incidence of Meniere-like symptoms in relatives of Meniere patients in the areas of Oulu University Hospital and Kainuu Central Hospital in Finland. Eur J Med Genet 2013;56:279-85. https://doi.org/10.1016/j.ejmg.2013.03.010

18 Frejo L, Soto-Varela A, Santos-Perez S, et al. Clinical subgroups in bilateral Meniere disease. Front Neurol 2016;7:182. https://doi.org/10.3389/fneur.2016.00182

19 Fattori B, Nacci A, Dardano A, et al. Possible association between thyroid autoimmunity and Menière's disease. Clin Exp Immunol 2008;152:28-32. https://doi.org/10.1111/j.1365-2249.2008.03595.x

20 Girasoli L, Cazzador D, Padoan R, et al. Update on vertigo in autoimmune disorders, from diagnosis to treatment. J Immunol Res 2018;26:5072582. https://doi.org/10.1155/2018/5072582

21 Oberman BS, Patel VA, Cureoglu S, et al. The aetiopathologies of Ménière's Disease: a contemporary review. Acta Otorhinolaryngol Ital 2017;37:250-63. https://doi.org/10.14639/0392-100X-79.

22 Blödow A, Pannasch S, Walther LE. Detection of isolated covert saccades with the video head impulse test in peripheral vestibular disorders. Auris Nasus Larynx 2013;40:348-51. https://doi.org/10.1016/j.anl.2012.11.002

23 Heuberger M, Sağlam M, Todd NS, et al. Covert anti-compensatory quick eye movements during head impulses. PLoS One 2014;9:e93086. https://doi.org/10.1371/journal.pone.0093086

24 McGarvie LA, Curthoys IS, MacDougall HG, et al. What does the dissociation between the results of video head impulse versus caloric testing reveal about the vestibular dysfunction in Ménière's disease?. Acta Otolaryngol 2015;135:859-65. https://doi.org/10.3109/00016489.2015.1015606

25 Ohki M, Murofushi T, Nakahara H, et al. Vibration-induced nystagmus in patients with vestibular disorders. Otolaryngol Head Neck Surg 2003;129:255-8. https://doi.org/10.1016/S0194-5998(03)00529-1

26 Hong SK, Koo JW, Kim JS, et al. Implication of vibration induced nystagmus in Meniere's disease. Acta Otolaryngol Suppl 2007;(558):128-31. https://doi.org/10.1080/03655230701625019

27 Teggi R, Colombo B, Albera R, et al. Clinical features, familial history, and migraine precursors in patients with definite vestibular migraine: the VM-Phenotypes projects. Headache 2018;58:534-44. https://doi.org/10.1111/head.13240

28 Scarpa A, Gioacchini FM, Cassandro E, et al. Clinical application of cVEMPs and oVEMPs in patients affected by Ménière's disease, vestibular neuritis and benign paroxysmal positional vertigo: a systematic review. Acta Otorhinolaryngol Ital 2019;39:298-307. https://doi.org/10.14639/0392-100X-2104

29 Sobhy OA, Elmoazen DM, Abd-Elbaky FA. Towards a new staging of Meniere's disease: a vestibular approach. Acta Otorhinolaryngol Ital 2019;39:419-28. https://doi.org/10.14639/0392-100X-2461

ACTA OTORHINOLARYNGOLOGICA ITALICA 2020;40:450-456; doi: 10.14639/0392-100X-N0931

Otology

Subtotal petrosectomy and cochlear implantation

Petrosectomia subtotale e impianto cocleare

Giulia D'Angelo, Giulia Donati, Andrea Bacciu, Maurizio Guida, Maurizio Falcioni

Otorhinolaryngology and Otoneurosurgery Department, University Hospital of Parma, Italy

SUMMARY

Objective. The objective of this study is to analyse surgical outcomes in a series of patients who underwent subtotal petrosectomy in combination with cochlear implantation.

Methods. Retrospective chart review. Thirty patients (32 ears) underwent subtotal petrosectomy and cochlear implantation in one stage. Indications for subtotal petrosectomy included the following: cholesteatoma, chronic otitis media, previous canal wall-down, osteoradionecrosis, revision surgery for clinical reasons, inner ear malformations, middle ear anatomical variations and severe cochlear ossification.

Results. Follow-up ranged from 2 to 54 months. Only 2 complications related to the subtotal petrosectomy (1 subcutaneous abdominal haematoma and 1 subcutaneous abdominal seroma) occurred in this series. Complete electrode insertion was achieved in all but 4 cases.

Conclusions. Subtotal petrosectomy is a safe procedure and can offer technical advantages in some cases of complex cochlear implantation.

KEY WORDS: cochlear implantation, subtotal petrosectomy, cholesteatoma, cochlear ossification, inner ear malformation

RIASSUNTO

Obiettivo. *L'obiettivo dello studio è analizzare i risultati chirurgici in una serie di pazienti sottoposti a petrosectomia subtotale e impianto cocleare.*

Metodi. *Studio retrospettivo. Trenta pazienti (32 orecchie) sono stati sottoposti a petrosectomia subtotale e impianto cocleare, in unico tempo. Le indicazioni alla petrosectomia subtotale sono state le seguenti: colesteatoma, otite media cronica, precedente tecnica aperta, osteoradionecrosi, chirurgia di revisione per motivazioni cliniche, malformazioni dell'orecchio interno, varianti anatomiche dell'orecchio medio, e severa ossificazione cocleare.*

Risultati. *Il follow-up è compreso fra 2 e 54 mesi. Nella serie si sono verificate solo 2 complicanze correlate alla petrosectomia subtotale (1 ematoma addominale sottocutaneo e 1 sieroma addominale sottocutaneo). È stata ottenuta l'inserzione completa degli elettrodi in tutti i casi a parte 4.*

Conclusioni. *La petrosectomia subtotale è una procedura sicura che in alcuni casi complessi di impianto cocleare può offrire dei vantaggi tecnici.*

PAROLE CHIAVE: *impianto cocleare, petrosectomia subtotale, colesteatoma, ossificazione cocleare, malformazione dell'orecchio interno*

Introduction

Cochlear implant (CI) has long been proven to provide hearing rehabilitation to patients with bilateral severe-to-profound sensorineural hearing loss (SNHL) who do not benefit from traditional hearing aids.

In the majority of cases, the standardised transmastoid facial recess approach perfectly suits the surgical requirements, and surgical risks are fairly low [1,2]. However, cochlear implantation in complex situations (concomitant chronic otitis media with or without cholesteatoma, previous canal wall-down techniques, inner ear malformations with severe risk of cerebrospinal fluid leak, etc.) may be challenging [1-5].

Received: June 16, 2020
Accepted: August 25, 2020

Correspondence
Giulia Donati
Azienda Ospedaliero-Universitaria di Parma, UOC Otorinolaringoiatria e Otoneurochirurgia, via Gramsci 14, 43126 Parma, Italy
Tel. +39 0521 703542. Fax +39 0521 703788
E-mail: ju.donati@hotmail.it

Funding
None.

Conflict of interest
The Authors declare no conflict of interest.

How to cite this article: D'Angelo G, Donati G, Bacciu A, et al. Subtotal petrosectomy and cochlear implantation. Acta Otorhinolaryngol Ital 2020;40:450-456. https://doi.org/10.14639/0392-100X-N0931

© Società Italiana di Otorinolaringoiatria e Chirurgia Cervico-Facciale

OPEN ACCESS

This is an open access article distributed in accordance with the CC-BY-NC-ND (Creative Commons Attribution-Non-Commercial-NoDerivatives 4.0 International) license. The article can be used by giving appropriate credit and mentioning the license, but only for non-commercial purposes and only in the original version. For further information: https://creativecommons.org/licenses/by-nc-nd/4.0/deed.en

Subtotal petrosectomy (SP) was first described by Rambo in 1958 [6] and then modified and popularised by Fisch in 1965 [7]. The main steps of the procedure are: 1) blind sac closure of the external auditory canal (EAC); 2) exenteration of middle ear and mastoid, including perisigmoid, perilabyrinthine, perifacial and hypotympanic cells; 3) removal of middle ear epithelium and mucosa; 4) closure of tympanic orifice of the Eustachian tube; 5) and obliteration of the cavity with abdominal fat [8]. In 1998, Issing et al. and Bendet et al. [9,10] proposed SP as the technique of choice for cochlear implantation in ears affected by chronic otitis media (COM). Over the past few years, SP has been progressively applied to a variety of difficult situations in CI surgery [1-14], slowly overcoming the initial resilience of the majority of the CI surgeons.

In fact, through the closure of the tubal orifice and the EAC, SP permits complete isolation of the surgical cavity from the external environment, decreasing the risk of postoperative infection, cerebrospinal fluid (CSF) leakage and meningitis [14,15]. In addition, the unobstructed view and illumination of the surgical cavity provide an excellent control and visualisation of all available landmarks [1,16]. Finally, the wide angle of approach to the round window area, obtained by removing the postero-superior wall of the EAC, makes each manoeuvre during array insertion much easier. These advantages are particularly important in presence of surgical difficulties such as cochlear obliteration or distorted anatomy [13,17].

The purpose of this study is to report our experience in a group of 30 patients who underwent SP combined with CI.

Materials and methods

A retrospective analysis of patients who underwent SP in combination with CI at the Department of Otorhinolaryngology and Otoneurosurgery of the University of Parma between January 2015 and March 2019 was performed. Subjects gave informed consent to the study and the study received the approval from the local Ethical Committee (Ref N. 36071). Patients requiring primary CI underwent complete otologic, audiologic, logopaedic and radiological examination (CT and MRI). Revision cases were only investigated by CT scan. Cochlear implantation was advised for standard indications, with no patients implanted for invalidating tinnitus and/or single side deafness. Data collected from patients' medical records included: demographic information, indication for SP, surgical time, intraoperative findings, electrophysiological data and postoperative complications, as well as clinical and radiologic follow-up findings. Follow-up was defined as the period of time from surgery to the most recent office visit. All patients but the 3 children were scheduled for a baseline control CT scan within 3 months from surgery. In patients with previous cholesteatoma or radical cavity (all adults), in which the risk of a cholesteatoma entrapment is higher, a new scan was planned at 3 years.

Details of surgical technique

The main concepts of the surgical technique have been described in previous publications [1,18]. A few significant refinements have been introduced and should be stressed because of their importance when combining SP with the positioning of a CI.

The standard retroauricolar skin incision should be extended supero-posteriorly for 2-3 cm, in order to create the implant hosting pocket more posteriorly than in a standard case. This is very important because, after a SP, the development of a retroauricolar skin depression is very common even if without clinical significance in most of the cases. However, in presence of a CI, if the anterior margin of the receiver-stimulator is placed in correspondence of this depression, it can lead to extrusion (Fig. 1).

When performing the blind sac closure of the EAC, a second layer created by the posterior reflection of the tragal cartilage is strongly recommended. This helps to reinforce the closure and reduce the risk of connecting cable extrusion at this level. At the same time, it may limit the medial growth of the skin in case of a break-down of the first layer closure.

An aggressive drilling of the anterior and inferior walls of the EAC is performed, especially at the level of the bony anulus, to minimise the possibility of leaving some skin debris at this level.

The facial ridge is lowered as much as possible to offer the best exposure of the round window niche. For this purpose,

Figure 1. Extrusion of the receiver/stimulator in the area of the retroauricolar retraction.

the removal of the bone anterior to the facial nerve is even more important. Unobstructed access to the round window niche represents one of the advantages of the SP and, especially in difficult cases, it must be maximised.

Drilling of the perilabyrinthine, hypotympanic, retrofacial and mastoid tip cells is accomplished. Residual mucosa is dissected or coagulated from these areas, as well as from the promontory and the tubal orifice, in order to avoid leaving any potentially infected tissue and/or the formation of mucous cysts/granulomas. At the end of the preparation, the cavity must be denuded by mucosa for the maximum extent (Fig. 2). In case of previous radical cavity or cholesteatoma, the same technique is applied to carefully remove all squamous epithelium, to avoid leaving skin debris with subsequent risk of inclusion cholesteatoma.

When the implant is finally in place, the connecting cable must be accommodated on the medial wall of the cavity and kept in place by the fat, in order to be maintained away from the subcutaneous layer. This reduces the risk of extrusion in the area where the aforementioned skin retraction will develop.

Whenever possible, the electrode array is inserted into the scala tympani (ST) through the round window membrane. In cases where the round window niche is not accessible (Fig. 3), a promontorial cochleostomy is performed. In presence of cochlear ossification, a first attempt to reach the ST is performed, drilling progressively the promontory in an antero-inferior direction, starting from the round window niche. If no cochlear lumen is visible, drilling is moved superiorly in order to locate the scala vestibuli (SV). When this latter is patent, a further attempt to open the ST is performed (2-3 mm) before taking the final decision (Fig. 4).

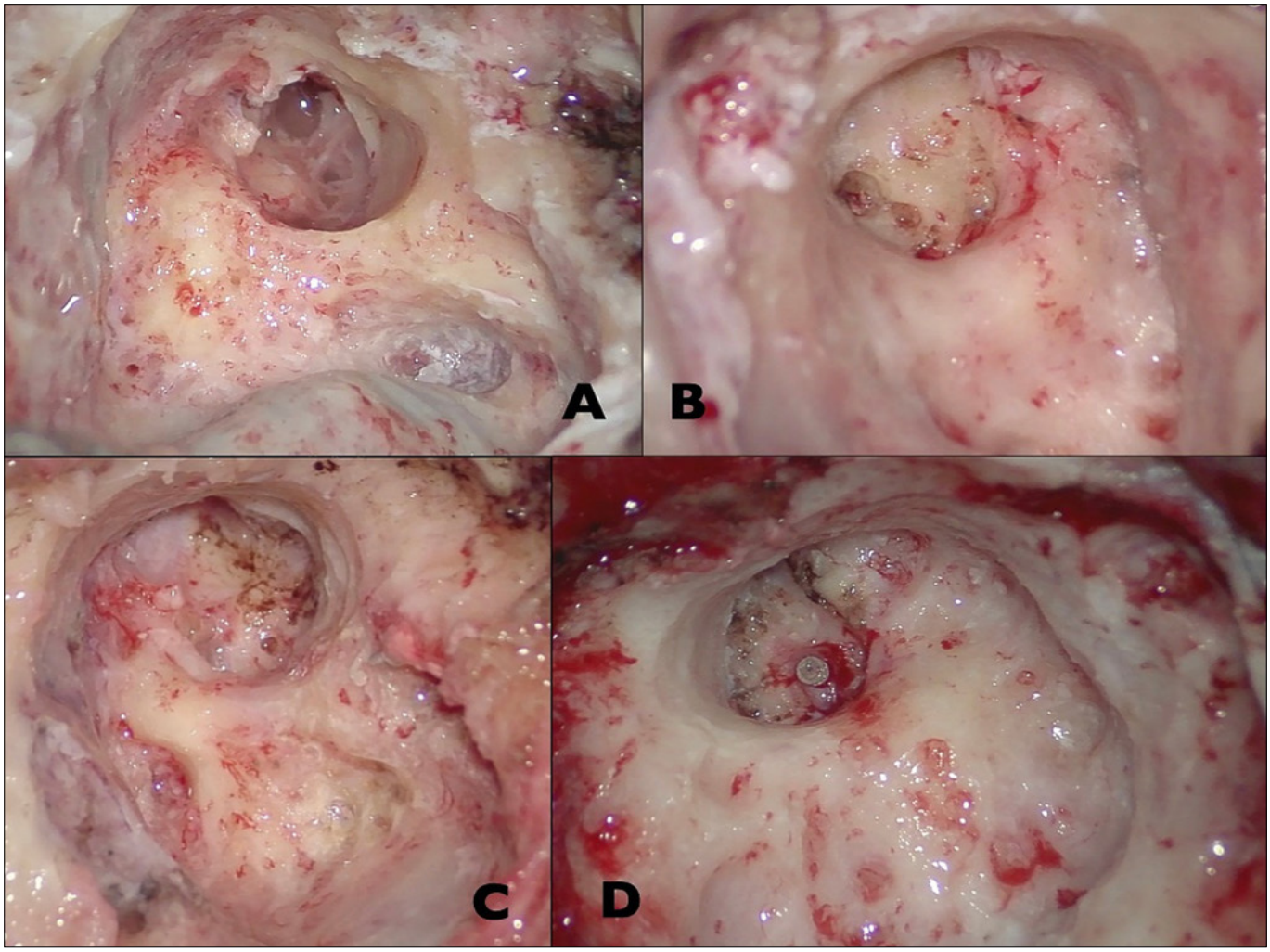

Figure 2. Final view of the bony cavity after cleaning of the pneumatisation and the mucosa (**A, B, C, D** - 4 different cases).

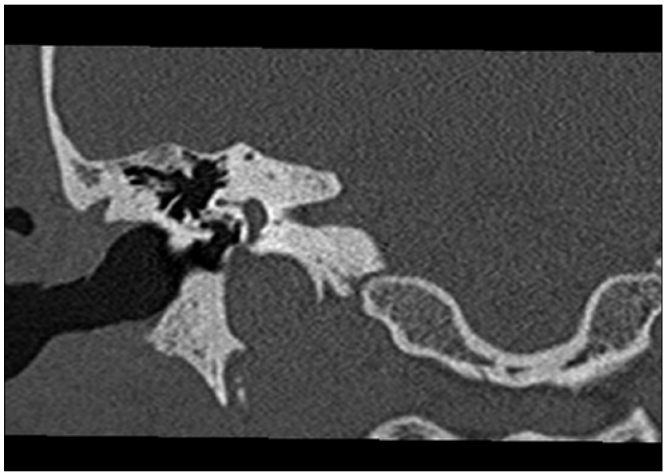

Figure 3. Coronal CT scan showing a superior protrusion of the jugular bulb covering completely the round window area; a promontorial cochleostomy had to be performed in order to reach the cochlear lumen.

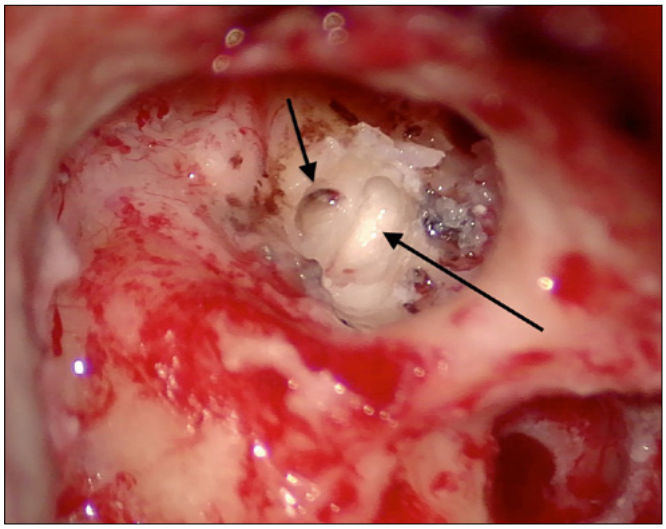

Figure 4. Intraoperative view of a severe cochlear ossification secondary to otosclerosis; after a promontorial drill-out, a cochlear lumen has been identified only at the level of the scala vestibuli (short arrow), while the scala tympani was completely ossified (long arrow).

Results

The study group was composed of 30 patients who underwent SP in combination with cochlear implantation as a single-stage procedure. Two patients were implanted bilaterally, resulting in a total of 32 surgically treated ears. Two additional cases (1 revision for complete array extrusion in an infected SP and 1 inner ear schwannoma) were excluded from the series because, intraoperatively, the cochlear drill-out was considered too destructive to achieve sufficient hearing restoration, even if a probe was partially inserted (both of them had a normal cochlea on the contralateral side). In 3 cases the surgery was started as a standard transmastoid approach and an intraoperative switch to SP was required due to unpredicted difficulties.

The group included 19 female (63%) and 11 male (37%) patients. The right ear was involved in 14 cases (44%), and the left ear in 18 (56%). The mean age at the time of surgery was 49 years (range 4-78 years). Of the 32 ears, 23 had already been operated at least once. Eleven ears already had a CI and were revision cases (9 previously treated in other centres). Among these, 9 were revision surgeries of a standard CI technique, 1 was a revision of a CI in a previous canal wall down and 1 was a revision of already a SP with CI. Table I shows the demographic characteristics, indications for SP and previous ear surgeries of the series. The indications for SP (sometimes multiple in the same patient) listed: cholesteatoma (10) (Fig. 5), chronic otitis media (3), previous radical cavity/canal wall-down mastoidectomies (4), severe cochlear obliteration (10), previous CI extrusion (2), previous extra-cochlear array positioning (1), anatomical variations (3), inner ear malformations (3), osteoradionecrosis (1).

All ears presented a preoperative pure tone average (PTA) > 90 dB with discrimination less than 10%. In 26 cases, the hearing aid could not be used in the ear-to-be-implanted for audiological or clinical reasons (i.e. infection, previous blind sac closure of the EAC, large meatoplasty, etc.).

The Neurelec Digisonic SP device was used in 3 cases, the Oticon ZTI CLA in 10, the Oticon ZTI EVO in 1, the Nucleus CI 24 RE (ST) in 2 and the Nucleus CI 512 CA in the remaining 16.

Three ears were implanted into the scala vestibuli and the remaining 27 into the scala tympani. In 2 cases, due to severe ossification, it was not possible to clearly identify the scala in which the array was positioned.

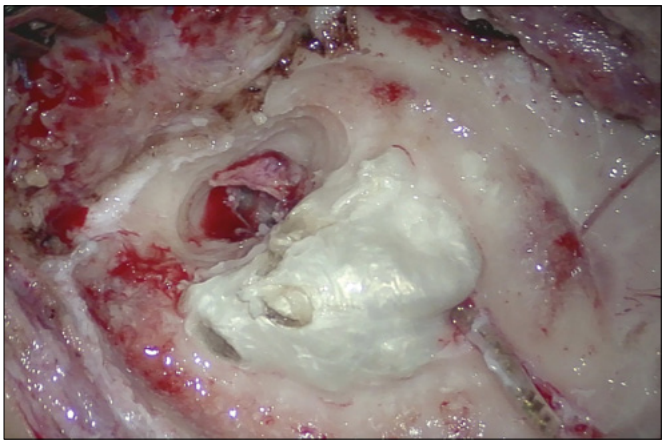

Figure 5. Extensive iatrogenic cholesteatoma secondary to a standard cochlear implantation.

Table I. Demographic characteristics, previous ear surgeries and indications for SP of the series.

Case	Sex	Age	Side	Previous ipsilateral ear surgery	Reason for SP
1	M	20	R	NO	Malformation
2	M	73	L	Stapedotomy, CI	Cholesteatoma
3	F	67	L	Radical mastoidectomy	Previous radical cavity
4	F	46	L	NO	Anatomical abnormalities (high JB)
5	M	57	L	CWD tympanoplasty, CI	Previous CWD, array extrusion, ossification
6	M	62	L	NO	Ossification
7	M	10	R	NO	Anatomical abnormalities (high JB)
8	M	55	R	Stapedotomy	Ossification
9	F	5	L	SP with CI	Incomplete array insertion, malformation, CSF leak
10	F	62	L	CWU tympanoplasty	COM
11	F	63	R	CI	Cholesteatoma,
12	F	71	L	Stapedotomy, CI	Ossification, previous CI malposition
13	F	78	L	Stapedotomy, CI	Cholesteatoma
14	F	48	R	CI with multiple revisions (SP during last revision)	Array and CI extrusion, blindsac closure breakdown, ossification
15	F	59	R	Stapedotomy and revision	Ossification
16	M	48	L	CWD tympanoplasty and revisions	Previous CWD, ossification
17	F	47	L	CWU tympanoplasty and revision	Cholesteatoma, ossification
18	F	37	L	SP	Cholesteatoma, previous SP
19	F	74	R	NO	Cholesteatoma
20	F	8	L	CI	Cholesteatoma, array extrusion
21	F	69	R	SP	Previous SP, cholesteatoma
22	F	66	R	CI and revision with SP	Previous SP, ossification
23	F	31	R	NO	Ossification
24	M	42	R	CWU tympanoplasty	Cholesteatoma
25	M	17	R	CI, myringoplasty	COM
26	F	72	R	NO	Ossification, COM
27	F	76	L	CWD tympanoplasty	Previous CWD, cholesteatoma
28	F	56	L	Stapedotomy	Ossification
29	F	31	L	CI	Posterior wall erosion, ossification
30	M	63	L	NO	Osteoradionecrosis
31	M	4	L	NO	Malformation
32	F	63	R	Stapedotomy and revision	Ossification

M: male; F: female; R: right; L: left; CI: cochlear implant; SP: subtotal petrosectomy; JB: jugular bulb; CWU: canal wall up; CWD: canal wall down; COM: chronic otitis media; CSF: cerebro-spinal fluid.

Full insertion of all the active electrodes was accomplished in 28 ears. In 3 patients the inserted electrodes were 18/20, 18/20 and 21/22, respectively. In the last case, in spite of an aggressive drilling of the basal turn, only 10/22 electrodes were inserted because of severe post-labyrinthitis obliteration.

The median value of the surgical time for the non-revision cases was 172.5 minutes, with an IQR of 60 minutes. When compared with a homogeneous control group of standard CI interventions, performed by the same surgeon during the same period (median value 117.5 min, IQR 48.75), the difference was statistically significant (p 0.0079).

After surgery, 1 patient experienced a subcutaneous haematoma in the area of the fat harvesting, requiring surgical revision of the abdominal wound. Another patient developed a delayed seroma in the same area, treated with a simple aspiration in the office at the time of implant activation The follow-up of the series ranged from 2 to 54 months (mean, 22 months with a SD of 14 months). One patient died because of cardiological problems 1 year after the surgery, 3 patients are not daily implant users (2 of them are lost at follow up), while 3 additional patients are followed-up in other centres near their hometown.

All patients but the children and the 2 lost to follow-up underwent the proposed radiological schedule. Presently, only 18 patients underwent a CT scan at 2 or more years after surgery. No residual cholesteatoma has been found to date.

The CI was activated between 20 and 30 days after surgery. All patients but 3 had all the inserted electrodes active, confirming the intraoperative impression. There was a patient with no active electrodes; this was a revision case where a middle ear infection was complicated with a labyrinthitis leading to complete modiolus destruction; the patient did not experience any auditory sensation, despite a complete electrode insertion. Due to the extreme heterogeneity of the patients' group (children, comorbidities, periverbal patients, revision surgery, different length of follow-up, etc.) the audiological performances ranged from sound detection to 100% of discrimination.

Discussion

The indications for performing SP in combination with CI have been described by many authors in the literature [1,2,9,18-22]. Nowadays, most authors agree that CI combined with SP is the best surgical choice in deafened patients with chronic otitis media, cholesteatoma or/and previous cavity [1,4,5,16,23]. In these situations, SP avoids disease recurrence and allows the creation of a closed and protected environment, significantly reducing the risk of infection and electrode array extrusion [3,15]. However, during the last years the scientific literature has documented a progressive increase in papers documenting the effectiveness of SP combined with cochlear implantation, even in patients with severe cochlear ossification/obliteration, inner ear malformations with high risk of CSF leak, fracture of the temporal bone with inner ear involvement and unfavourable anatomic conditions [1,2,9,10,13,16,17,19,21,24,25]. Some cases of revision surgery may also benefit from a larger and more comfortable approach. However, these indications are still not shared by all surgeons, probably because SP is not routinely performed in all otologic centres.

Most of the cases in our series presented more than one indication for adopting the technique. Under these circumstances, SP provides an excellent control of all the middle ear structures and, if required, offers the possibility to manage the carotid artery, the jugular bulb and, also, an anomalous course of the facial nerve. Unpredicted intraoperative difficulties may also suggest a switch from the classic approach to the SP, even if this increases surgical time.

The complete control of all the landmarks gives the possibility to perform safer surgical manoeuvres [1,6]. In particular, a better control of the round window area may increase the possibility of a correct and complete insertion even in presence of complex cases [8,12,16].

This was confirmed in our series by the absence of extracochlear array positioning and the high rate of electrodes insertion (only 4 cases of incomplete insertion). Even in all the otosclerosis cases, in spite of an aggressive drill-out of the basal turn, a complete electrode array insertion was possible in 100% of the patients.

The price to pay for these advantages is represented by the necessity of an additional abdominal incision with the consequent risk of complications (1 subcutaneous haematoma and 1 seroma in our series). These were the only complications directly connected to the surgical technique (the other was atrial fibrillation in a cardiopathic patient). However, these results may be achieved only if the technique is meticulously performed in every step, as confirmed by 3 patients in the series that had already undergone a SP (1 with and 2 without a simultaneous CI) and required revision surgery.

Another criticism of the technique is the prolonged surgical time, which was significant longer (p 0.0079) compared to standard CI interventions; however, the difference can be justified, at least partially, by the complexity of the SP cases. There is general consensus that SP and CI can be safely performed simultaneously in the majority of the cases [1,12,16]. It is still debated whether, in active purulent COM, cholesteatoma and previous cavity, SP should precede CI of several months (6 to 12), as recommended by most authors [3,9,21,22]. This staging strategy can reduce the risk of meningitis resulting from the insertion of an electrode in a potentially contaminated field [1,22] and reduce the risk of residual cholesteatoma. In agreement with other authors [2], we usually prefer to perform SP and CI in a single stage. We believe that SP usually permits a macroscopic total squamous epithelium and infected tissue removal, facilitated by the wide exposure. In addition, the staged strategy introduces a significant delay in the hearing rehabilitation process. We recommend a two-stage procedure only for special cases with surgical impression of incomplete disease removal (never encountered till now). In the osteoradionecrosis case included in the series, being the patient affected by bilateral occlusion of 2 carotid stents (100% and 50%), the infective risk was judged inferior of that of an additional surgery.

In most cases (without cholesteatoma or previous cavity) where the technique is correctly performed, the risk of skin entrapment is so low that, in our opinion, does not require a radiological follow-up. A CT scan is usually acquired within 3 months after surgery (not in children), and can be used as baseline in case a further investigation is required in the future.

In presence of radical cavity or COM with cholesteatoma, despite all efforts to meticulously remove all squamous epithelium, residual cholesteatoma can occur even many years after surgery [1,3,10,15]. Hence, prolonged follow-up in these patients is necessary. The most adopted protocol is

to follow the patients with a CT every 2 or 3 years for 10 years. Diffusion-weighted non-EPI MRI, which is considered the gold standard evaluation for residual cholesteatoma, is completely useless in the presence of a CI, because of the huge artefacts produced by this specific sequence. However, all the new generation implants allow the magnet to be removed and repositioned under local anaesthesia, immediately before and after the MRI. This procedure may be scheduled once (after 3 or 4 years), in order to stop any further evaluation. Even if the follow-up it too short to reach definitive conclusions, we have not recorded a single cholesteatoma entrapment to date.

Conclusions

The SP approach may be safely adopted in cochlear implantation surgery when facing a variety of difficult situations. Its adoption is strongly recommended in presence of cholesteatoma, chronic otitis or a previous cavity. In other situations, even if not mandatory, it may help in reducing clinical failures and partial insertions. The mean additional surgical time required, compared to the standard transmastoid approach, applied to uncomplicated cases, is around one hour. In order to reach these goals and avoid complications, the technique must be mastered perfectly in every single detail. Even if not adopted with the frequency reported in our series, we believe it should be part of the technical expertise/skill of every surgeon performing cochlear implants. The suggested strategy of staging seems not necessary if only in exceptional cases.

References

1. Free RH, Falcioni M, Di Trapani G, et al. The role of subtotal petrosectomy in cochlear implant surgery - a report of 32 cases and review on indications. Otol Neurotol 2013;34:1033-40. https://doi.org/10.1097/MAO.0b013e318289841b
2. Bernardeschi D, Nguyen Y, Smail M, et al. Middle ear and mastoid obliteration for cochlear implant in adults: indication and anatomical results. Otol Neurotol 2015;36:604-9. https://doi.org/10.1097/MAO.0000000000000702
3. Pasanisi E, Vincenti V, Bacciu A, et al. Multichannel cochlear implantation in radical mastoidectomy cavities. Otolaryngol Head and Neck Surg 2002;127:432-6. https://doi.org/10.1067/mhn.2002.129822
4. Hunter JB, O'Connell BP, Wanna GB. Systematic review and meta-analysis of surgical complications following cochlear implantation in canal wall down mastoid cavities. Otolaryngol Head Neck Surg 2016;155:555-63. https://doi.org/10.1177/0194599816651239
5. Sanna M, Dispenza F, Falcioni M, et al. Management of chronic otitis by middle ear obliteration with blind sac closure of the external auditory canal. Otol Neurotol 2008;29:19-22. https://doi.org/10.1097/MAO.0b013e31815dbb40
6. Rambo, JHT. Primary closure of the radical mastoidectomy wound: a technique to eliminate postoperative care. Laryngoscope 1958;68:1216-27. https://doi.org/10.1002/lary.5540680707
7. Fisch U. Microsurgery of the temporal bone. HNO 1977;25:193-7.
8. Coker NJ, Jenkins HA, Fisch U. Obliteration of the middle ear and mastoid cleft in subtotal petrosectomy: indications, technique, and results. Ann Otol Rhinol Laryngol 1986;95:5-11. https://doi.org/10.1177/000348948609500102
9. Issing PR, Shönermark MP, Winkelmann S, et al. Cochlear implantation in patients with chronic otitis: indications for subtotal petrosectomy and obliteration of the middle ear. Skull Base Surg 1998;8:127-31. https://doi.org/10.1055/s-2008-1058571
10. Bendet E, Cerenko D, Linder TE, et al. Cochlear implantation after subtotal petrosectomies. Eur Arch Otorhinolaryngol 1998;225:169-74. https://doi.org/10.1007/s004050050037
11. Adunka OF, Buchman CA. Cochlear implantation in the irradiated temporal bone. J Laryngol Otol 2007;121:83-6. https://doi.org/10.1017/S0022215106002180
12. Prasad CS, Roustan V, Sanna M, et al. Subtotal petrosectomy: Surgical technique, indications, outcomes, and comprehensive review of literature. Laryngoscope 2017;127:2833-42. https://doi.org/10.1002/lary.26533
13. Vashishth A, Fulcheri A, Prasad SC, et al. Cochlear implantation in cochlear ossification: retrospective review of etiologies, surgical considerations, and auditory outcomes. Otol Neurotol 2018;39:17-28. https://doi.org/10.1097/MAO.0000000000001613
14. Merkus P, Free RH, Mylanus EA, et al. Dutch Cochlear Implant Group (CI-ON) consensus protocol on postmeningitis hearing evaluation and treatment. Otol Neurotol 2010;31:1281-6. https://doi.org/10.1097/MAO.0b013e3181f1fc58
15. Vincenti V, Pasanisi E, Bacciu A, et al. Long-term results of external auditory canal closure and mastoid obliteration in cochlear implantation after radical mastoidectomy: a clinical and radiological study. Eur Arch Otorhinolaryngol 2014;271:2127-30. https://doi.org/10.1007/s00405-013-2698-3
16. Polo R, Del Mar Medina M, Arístegui M, et al. Subtotal petrosectomy for cochlear implantation: lessons learned after 110 cases. Ann Otol Rhinol Larynngol 2016;125:485-94. https://doi.org/10.1177/0003489415620427
17. Roland JT Jr, Coelho DH, Pantelides H, et al. Partial and double-array implantation of the ossified cochlea. Otol Neurotol 2008;29:1068-75. https://doi.org/10.1097/MAO.0b013e318188e8ea
18. Sanna M, Free R, Merkus P, et al. Surgery for cochlear and other auditory implants. First Edition. Stuttgart: Thieme; 2015.
19. Arndt S, Beck R, Shild C, et al. Management of cochlear implantation in patients with malformations. Clin Otolaryngol 2010;35:220-7. https://doi.org/10.1111/j.1749-4486.2010.02124.x
20. Sennaroglu L. Cochlear implantation in inner ear malformations - a review article. Cochlear Implants Int 2010;11:4-41. https://doi.org/10.1002/cii.416
21. Leung R, Briggs RJ. Indications for and outcomes of mastoid obliteration in cochlear implantation. Otol Neurotol 2007;28:330-4. https://doi.org/10.1097/01.mao.0000265187.45216.71
22. Szymański M, Ataide A, Linder T. The use of subtotal petrosectomy in cochlear implant candidates with chronic otitis media. Eur Arch Otorhinolaryngol 2016;273:363-70. https://doi.org/10.1007/s00405-015-3573-1
23. Ketelslagers K, Somers T, De Foer B, et al. Results, hearing rehabilitation, and follow-up with magnetic resonance imaging after tympanomastoid exenteration, obliteration, and external canal overclosure for severe chronic otitis media. Ann Otol Rhinol Laryngol 2007;116:705-11. https://doi.org/10.1177/000348940711600914
24. Balkany T, Bird PA, Hodges AV, et al. Surgical technique for implantation of the totally ossified cochlea. Laryngoscope 1998;108:988-92. https://doi.org/10.1097/00005537-199807000-00007
25. Greenberg SL, Shipp D, Lin VY, et al. Cochlear implantation in patients with bilateral severe sensorineural hearing loss after major blunt head trauma. Otol Neurotol 2011;32:48-54. https://doi.org/10.1097/MAO.0b013e3181ff73fd

ACTA OTORHINOLARYNGOLOGICA ITALICA 2020;40:457-462; doi: 10.14639/0392-100X-N0996

Otology

The effect of N-acetyl cysteine on biofilm layers in an experimental model of chronic otitis media

L'effetto della N-acetil cisteina sullo strato di biofilm in un modello sperimentale di otite media cronica

Elif Ersoy Çallıoğlu[1], Sami Berçin[2], Gülçin Başdemir[3], Muzaffer Kiriş[2], İlkan Tatar[4], Arzu Tuzuner[5], Tolga Oğuzhan[6], Tuba Müderris[7], Mustafa Fevzi Sargon[8], Mehmet Hakan Korkmaz[2]

[1] Ankara Bilkent City Hospital Otolaryngology Department, Ankara, Turkey; [2] Yıldırım Beyazıt University Ear Nose and Throat Department, Ankara, Turkey; [3] Okan University Pathology Clinics, İstanbul, Turkey; [4] Hacettepe University Anatomy Department, Ankara, Turkey; [5] Başkent University Ear Nose and Throat Clinics, Ankara, Turkey; [6] Istanbul Medicalpark Hospital Ear Nose and Throat Clinics, Istanbul, Turkey; [7] Izmir Atatürk Training and Investigation Hospital Microbiology Clinics, Izmir, Turkey; [8] Atılım University Anatomy Department, Ankara, Turkey

SUMMARY

Objectıve. The aim of this study was to investigate the efficacy of N-acetylcysteine (NAC) on biofilm layers and on the course of disease in chronic otitis media.

Methods. Twenty-five rats that were induced with chronic otitis media (COM) were separated into three groups. In Group 1 (N = 18), 0.2% ciprofloxacin + 0.1% dexamethasone sodium phosphate + 0.5 mg/ml NAC solution was locally injected to the right ear of the rats; in Group 2, (N=18) 0.2% ciprofloxacin + 0.1% dexamethasone sodium phosphate was locally injected to the left ear of the rats. No treatment was applied to either ear of rats in Group 3 (N = 5). Histopathological and scanning electron microscope (SEM) evaluations were performed in all groups.

Results. SEM revealed biofilm formation in all COM induced groups. No significant difference was seen between groups 1 and 2 in terms of suppuration levels, fibrosis, inner ear involvement, infection staging and biofilm formation ($p > 0.05$).

Conclusıons. In this study, while histopathological and SEM evaluation revealed no effect of 0.5 mg/ml NAC on the biofilm layer in COM-induced rats, further studies with NAC at different concentrations are still needed on different types of experimental animals.

KEY WORDS: chronic otitis, biofilm, N-acetylcysteine, rat

RIASSUNTO

Obıettıvo. *Lo scopo di questo studio è quello di valutare l'efficacia della N-acetilcisteina (NAC) sullo strato di biofilm e sul decorso della malattia nell'otite media cronica.*

Metodo. *Venticinque ratti con otite media cronica (COM) sono stati divisi in tre gruppi. Nel gruppo 1 (N = 18) sono stati iniettati 0,2% di ciprofloxacina + 0,1% di desametasone sodio fosfato + 0,5 mg / ml di soluzione NAC all'orecchio destro dei ratti; nel gruppo 2 (N = 18) sono stati iniettati localmente 0,2% di ciprofloxacina + 0,1% di desametasone sodio fosfato all'orecchio sinistro dei ratti. Nessun trattamento è stato applicato alle orecchie inoculate dei ratti nel gruppo 3 (N = 5, entrambe le orecchie). Sono state eseguite valutazioni istopatologiche e valutazioni al microscopio elettronico (SEM) mediante scansione.*

Rısultatı. *SEM ha documentato la formazione di biofilm in tutti i gruppi indotti con COM. Nessuna differenza statisticamente significativa è stata osservata tra i gruppi 1 e 2 in termini di livelli di suppurazione, fibrosi, coinvolgimento dell'orecchio interno, stadiazione dell'infezione e formazione di biofilm ($p > 0,05$).*

Conclusıone. *Anche se in questo studio la valutazione istopatologica e SEM non ha rivelato alcun effetto del 0,5 mg/ml NAC sullo strato di biofilm nei ratti indotti dalla COM, per arrivare a una conclusione migliore è necessario eseguire ulteriori studi con di NAC a diverse concentrazioni su differenti tipi di animali da esperimento.*

PAROLE CHIAVE: *otite cronica, biofilm, N-acetilcisteina, ratto*

Received: July 17, 2020
Accepted: September 21, 2020

Correspondence
Elif Ersoy Çallıoğlu
Ankara Bilkent City Hospital Otolaryngology Department, Ankara, Turkey
E-mail: elifersoy78@hotmail.com

Funding
The present study was supported financially by project bureau of Yıldırım Beyazıt University.

Conflict of interest
The Authors declare no conflict of interest.

How to cite this article: Ersoy Çallioğlu E, Berçin S, Başdemir G, et al. The effect of N-acetyl cysteine on biofilm layers in an experimental model of chronic otitis media. Acta Otorhinolaryngol Ital 2020;40:457-462. https://doi.org/10.14639/0392-100X-N0996

© Società Italiana di Otorinolaringoiatria e Chirurgia Cervico-Facciale

OPEN ACCESS

This is an open access article distributed in accordance with the CC-BY-NC-ND (Creative Commons Attribution-Non-Commercial-NoDerivatives 4.0 International) license. The article can be used by giving appropriate credit and mentioning the license, but only for non-commercial purposes and only in the original version. For further information: https://creativecommons.org/licenses/by-nc-nd/4.0/deed.en

Introduction

Biofilm is a community of micrororganisms residing in a gelatinous layer with polymeric structures and its production starts by attaching to a surface [1]. Biofilm formation may take place in lifeless surfaces *in vivo* or *in vitro*. The microorganisms in biofilms are more resistant to antimicrobial agents than planktonic cells, as they have barriers impeding contact with antimicrobial agents and decreasing sensitivity [2]. Biofilm has also the characteristic of protecting the organism from osmotic stress, phage debris, toxic compounds and antibiotics.

Various bacterial proteins (biofilm) are produced by bacteria in chronic otitis media (COM), which increase the adhesion and penetration of them into middle ear mucosa [3]. It is considered that in resistant COM, otorrhoea is possibly derived from biofilm layer [3]. In cases of COM in which otorrhoea and inflammation cannot be relieved in spite of medical treatment, surgical intervention is used as an alternative treatment which aim to destroy the damaged osteitic tissue.

N-acetyl cysteine (NAC) is a precursor of glutathione and produces neuroprotection by preventing oxidative damage [4,5]. In addition to its primary use, it is also utilised in chronic bronchitis, cancer, paracetamol intoxication and aspergilloma [6-8]. NAC exerts an eradicating effect on biofilm layer produced by various bacteria [9-12]. The effect of NAC, on COM associated biofilm layer produced by primary pathogen *P. aeruginosa*, has been demonstrated [12]. Although the effect of NAC on biofilm layer was demonstated in infections produced by *P. aeruginosa* in respiratory and renal systems, its effect in COM treatment is controversial. The aim of the present study was to investigate the effect of NAC on biofilm layer formation in COM produced in a rat model. We also investigated the role of NAC in preventing the involvement of the inner ear in COM.

Materials and methods

The present study was carried out with 30 healthy male Wistar albino rats at a weight of 180-220 gm with the approval of ethics committee of Ankara Training and Investigation Hospital (13 May 2014, No. 0018). The principles of Helsinki declaration for laboratory animals were applied. All animals were followed and cared in accordance with a protocol approved by institutional animal care group that was compliant with experimental ethical principles and animal protection laws in Turkey. Animals were isolated in standard cages throughout the experimental period and were given food and water ad libitum.

Surgical technique

The surgical procedure was carried out by the same surgeon in all rats under general anaesthesia using ketamine hydrochloride (90 mg/kg) and xylazine hydrocloride (10 mg/kg). After otoscopic examination and otoacoustic emission tests were performed, 30 rats with normal findings were included in the present study. As in previous studies with chronic otitis model [3,13,14], tympanic membranes of 25 rats (TM) were perforated with a proportion of 75% and 10^6 colony *P. aeruginosa* strains (strain - ATCC -27853) were inoculated into the middle ear via the perforation. The same inoculation procedure was repeated one week later. Subsequently, microscopic examination was carried out twice weekly for three weeks and rats were followed up without treatment. Three weeks after the last inoculation, rats were examined under sterile conditions and external ear cultures were obtained. Otomicroscopic examination of all rats revealed COM and purulent discharge in the outer ear canal. The cultures demonstrated the presence of *P. aeruginosa* infection in all rats. Meanwhile, 2 rats were lost due to malnutrition. Treatments were then started; to right ears of 18 rats, (Group 1) 0.2% ciprofloxacin + 0.1% dexamethasone sodium phosphate + 0.5 mg/ml NAC and to left ears 0.2% ciprofloxacin + 0.1% dexamethasone sodium phosphate was administered (Group 2). These medical treatments were administered for 4 weeks twice a day locally by injection in the external auditory canal. In Group 3, 10 ears of 5 rats were not administered any medical treatment after inoculation. In Group 4, 10 ears of 5 rats were investigated as a control group without undergoing any procedure. Animals were decapitated after deep anaesthesia with the same protocol.

Histomorphological evaluation

After temporal bones were removed, they were fixed in 10% formalin and after decalcification paraffin blocks were prepared. 4 µm sections from paraffin blocks were stained with haematoxylin-eosin, PAS and masson trichrome stains. In the sections examined with light microscope, lesions produced by infection in external ear, middle ear, inner ear and the presence of mast cells and suppuration to determine improvement levels and development of fibrosis. As the variation in quality and quantity of lesions made it difficult to obtain repeatable objective data, fibrosis and suppuration, which are more suitable for quantitative evaluations, were evaluated semiquantitatively (-, +, ++, +++). Inner ear involvement was shown as present or absent (+, -).

In addition, stage/level of infection was evaluated histomorphologically; lesions produced by varying combinations of different histomorphological findings were classifed into acute suppurative (suppuration/fibrosis: ++ or +++/- or +) (Fig. 1) or chronic suppurative (suppuration/fibrosis: ++ or

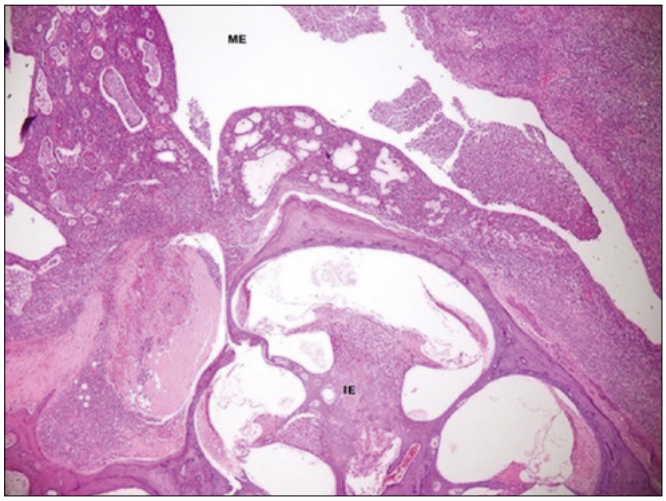

Figure 1. Group1 rats, acute suppurative inflammation in middle ear (ME); there is no involvement in inner ear (İE), routine histological characteristics (suppuration +++, fibrosis-).

+++/++ or +++) depending on the severity and proportion of suppuration and fibrosis.

Ears in which suppuration/fibrosis were (+/+), (+/-) or (-/+), were classified as healed/improved (Fig. 2), because none of the ears undergoing treatment procedures were completely healed (suppuration/fibrosis: -/-).

Scanning electron microscopic (SEM) evaluation

Fresh specimens obtained from 5 ears of each group were fixed in 2.5% glutaraldehyde for 24 hours, irrigated in phosphate buffer (pH 7.4), fixed with 1% ozmium tetroxide in phosphate buffer (pH 7.4) and dehydrated in increasing alcohol concentrations. After dehydration, specimens were dried and mounted on metal frames with double sided adhesive tape. Subsequently, Bio-Rad (Hercules, CA) gold thick layer 150-A ° k were sprayed to specimens. SEM images were obtained with JEOL SEM ASID-10 (Tokyo, Japan) electron miscrosope at 500X-3000X magnification range.

The presence of biofilm was determined using SEM morphological findings such as three dimensional structure, variability in the size of microorganisms embedded in polysaccaride matrix and residue of multiple layers of tissue and microorganisms. 3 x 3 mm specimens sampled from middle ear mucosa were examined. With this investigation, the presence of biofilm was evaluated and in biofilm positive specimens, similar to other studies in the literature [15], and the presence of biofilm in less than 25% of all visualised surface areas was classified as (+) between 25-50% as (++) and over 50% as (+++) SEM analysis.

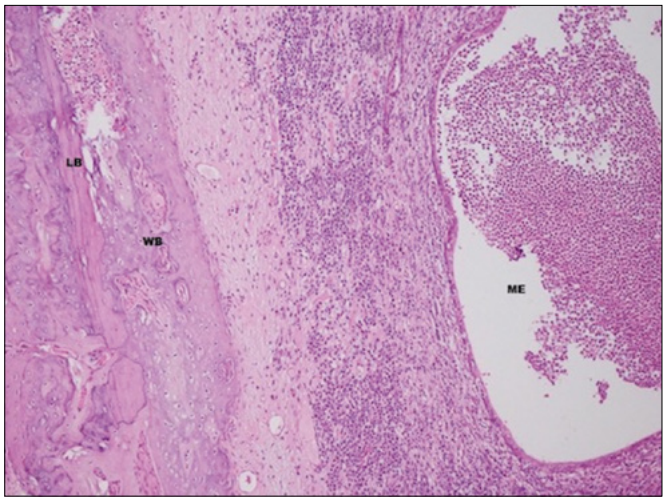

Figure 2. Group 1, residual necrotic lamellous bone (LB) fragments due to destruction in middle ear (ME) bone wall, caused by infection at the recovery process. Overlying new woven bone (WB) tissue and thin fibrous wall are seen on the surface of degenerated epithelium. Suppuration continues in the lümen (suppuration +, fibrosis +).

Statistical evaluation

Descriptive statistics were expressed with the number and percentage of cases both for nominal and ordinal variables. Nominal data were analysed with Fisher's exact test, while ordinal data were analysed with Mann Whitney U test. Data analysis was performed using IBM SPSS version 17.0 software (IBM Corporation, Armonk, NY, USA). A $p < 0.05$ was considered significant for all results.

Results

In all rats with experimental COM, cultures obtained three weeks after the last inoculation revealed the *P. aeruginosa* infection.

Histomorphological findings

Except for the control group, which did not undergo any procedure, in all ears and temporal bones varying degrees of supurative or chronic inflammation, granulation tissue, vascularisation, fibrous tissue development and partial appearance of cholesteatoma were detected. Mast cell involvement was observed in eustachian tubes and inner ears and for the most part ossicles and tympanic membrane were completely destroyed and were surrounded by suppuration and fibrosis, accompanied by inner ear involvement. Inner ear structures; cranial nerve VIII, spinal ganglions, cochlear and vestibulare bones were partially or completely destroyed and replaced b fibrous repair tissue filling the vestibulare and tympanic ducts.

It was observed that the inner ear was completely destroyed in a few ears in which suppuration disappeared and fibrosis

Table I. Histopathological findings of cases undergoing only treatment or NAC plus treatment.

	Group 2	Group 1	p-value
Suppuration			0.963†
-	4 (22.2%)	2 (11.1%)	
+	3 (16.7%)	8 (44.4%)	
++	4 (22.2%)	0 (0.0%)	
+++	7 (38.9%)	8 (44.4%)	
Fibrosis			0.963†
-	4 (22.2%)	2 (11.1%)	
+	5 (27.8%)	4 (22.2%)	
++	3 (16.7%)	11 (61.1%)	
+++	6 (33.3%)	1 (5.6%)	
Inner ear chacaracteristics			0.338‡
Normal	14 (77.8%)	17 (94.4%)	
Involved	4 (22.2%)	1 (5.6%)	
Infections stage			0.462†
Improved	5 (27.8%)	10 (55.6%)	
Acute suppurative	7 (38.9%)	1 (5.6%)	
Chronic suppurative	6 (33.3%)	7 (38.9%)	

† Mann Whitney U test; ‡ Fisher's Exact test.

was very mild. It was also found that inner ear involvement was more marked in groups that did not undergo treatment (Group 3) compared to the groups that underwent treatment (Group 1, Group 2) (Fig. 1). In the evaluation of osteoblastic and osteoclastic activities, no difference was found between Groups 1 and 2 (Fig. 2).

There was no significant difference between NAC+treatment group and only treatment group with respect to severity of suppuration and fibrosis, inner ear involvement or stage of infection ($p > 0.05$) (Tab. I). In group 3, no statistical comparison was performed with groups 1 and 2 since extensive suppuration, fibrosis, and inner ear involvement was detected in all ears.

In the control group, which did not undergo any procedure, suppuration, fibrosis and inner ear involvement were not observed.

SEM findings

In SEM imaging, biofilm formation was established in all groups. There was no significant difference between Groups 1 and 2 in terms of biofilm formation ($p > 0.05$) (Tab. II).

In the evaluation of SEM findings in Group 3, widespread biofilm areas were observed on the middle ear mucosa. As there was no treatment, together with polymorphonuclear leukocytes, many free bacteria, bacteria debris and ECM appearance were also observed (Fig. 3).

Table II. SEM findings in groups 1 and groups 2.

	Group 2	Group 1	p-value
SEM			0.690†
+	1 (20.0%)	2 (40.0%)	
++	4 (80.0%)	3 (60.0%)	
+++	0 (0.0%)	0 (0.0%)	

† Mann Whitney U test.

In SEM findings of Group 1 rats, widespread biofilm was observed along with polymorphonuclear leukocytes.



Figure 3. Group 1 rats, SEM appearance of biofilm layer.



Figure 4. SEM appearance of biofilm layer in Group 2 rats.



Figure 5. Control group SEM findings.

SEM findings were similar in Group 2 to those in Group 1. Widespread biofilm formation was observed along with blood components (Fig. 4).

In control group without chronic otitis (Group 4), the normal middle ear mucosa was observed without any biofilm formation (Fig. 5).

Discussion

To our knowledge, the present study is the first attempting to experimentally demonstrate the effect of NAC on biofilm formation in the middle ear and mastoid cells in COM, in terms of histopathological and SEM findings. In refractory COM, in spite of medical treatment to which primary pathogen, *P. aeruginosa*, is sensitive, otorrhoea and inflammation cannot be improved. NAC also exerts an eradicating effect on biofilm layers produced by various bacteria in addition to its other benefits [9-12,16,17]. The effect of NAC on primary pathogen of COM, i.e. *P. aeruginosa*, has been demonstrated in many in vivo and in vitro studies [12,16,17]. For this purpose, the efficacy of NAC has been investigated at different concentrations. In addition to other routes, NAC may also be administered locally. In the study by Özcan et al. [18], in which the effect of NAC in myringosclerosis in rats was investigated, 0.6 mg and 1.2 mg topical NAC was used, and it was demonstrated that it prevents the development of myringosclerosis. In the study by El-Feky et al. [16], aiming to determine the effect of the addition of NAC to ciprofloxacin treatment for biofilms on the surface of uretheral stents, 2-4 mg/ml NAC was used, and it was determined that the development of mature biofilms declined. Zhao et al. [12] added NAC at 0.5 mg /ml and 1 mg /ml to ciprofloxacin treatment and found that NAC decreased biofilm layer produced by *P. aeruginosa* and production of extrapolysaccharides. However, in that study, its effect on *P. aeruginosa* was investigated in patients with respiratory tract infections. Similar to this study, we used NAC at 0.5 mg/ml for eradication of biofilms. Herein, we found no significant difference between groups 1 and groups 2 with regard to severity of suppuration and fibrosis, involvement of inner ear, stage of infection or SEM findings ($p > 0.05$) (Figs. 1, 2). It may be thought that this is due to differences in experimental animals used, variations in dose, the infectious process in which NAC was used and different organs. In previous studies, NAC was used in vivo and in vitro in pseudomonal infections, and not in treatment of COM, which may also explain the discrepant results.

It has been demonstrated in various studies that NAC enhances osteoblastic activity and bone regeneration [19]. However, in the present study, in COM model, no difference was found between Group 1 and 2 in terms of osteoblastic and osteoclastic activity (Fig. 2).

There are few studies in the literature on the effect of NAC on COM treatment. In the only study carried out by Choe et al. [20], it was established that NAC with ciprofloxacin was effective in the treatment of refractory COM. Nevertheless, their study was performed with a small number of patients with no histopathological and SEM evaluation, and their conclusion was based upon solely clinical evaluation.

Severe and destructive lesions developing in all of the ears undergoing experimental treatment procedures made it difficult to evaluate the severity of histomorphological findings quantitatively, and hence to determine the grade of findings of infection and recovery. We hope that the present study will be a pioneer model that can guide future studies with biofilms and resistant infections. In future studies, lower microorganism concentrations can be used in conjunction with higher dosages of NAC. This method may better reveal the efficacy of NAC in the process of biofilm formation in COM.

Conclusions

Although there are many studies demonstrating the effect of NAC on biofilms, very few of them examined its efficacy in COM. In our study, we found no additional effect of topical NAC to the treatment of COM evaluated histopathologically and with SEM in the rat model. We suggest that further studies are required using different concentrations of NAC with different experimental animals in order to reach more definitive conclusions.

References

1. Leone S, Molinaro A, Alfieri F, et al. The biofilm matrix of Pseudomonas sp. OX1 grown on phenol is mainly constituted by alginate oligosaccharides. Carbohydr Res 2006;341:2456-61. https://doi.org/10.1016/j.carres.2006.06.011
2. O'Toole GA, Kaplan, HB. Biofilm formation as microbial development. Ann Rev Microbiol 2000;54:49-79. https://doi.org/10.1146/annurev.micro.54.1.49
3. Dohar JE, Hebda PA, Veeh R, et al. Mucosal biofilm formation on middle-ear mucosa in a nonhuman primate model of chronic suppurative otitis media. Laryngoscope 2005;115:1469-72. https://doi.org/10.1097/01.mlg.0000172036.82897.d4
4. Dodd S, Dean O, Copolov DL, et al. N-acetylcysteine for antioxidant therapy: pharmacology and clinical utility. Expert Opin Biol Ther 2008;8:1955-62. https://doi.org/10.1517/14728220802517901
5. Berk M, Copolov DL, Dean O, et al. N-acetyl cysteine for depressive symptoms in bipolar disorder a double-blind randomized placebo-controlled trial. Biol Psychiatry 2008;64:468-75. https://doi.org/10.1016/j.biopsych.2008.04.022
6. Riise GC, Qvarfordt I, Larsson S, et al. Inhibitory effect of N-acetylcysteine on adherence of Streptococcus pneumoniae and Haemophilus influenzae to human oropharyngeal epithelial cells in vitro. Respiration 2000;67:552-8. https://doi.org/10.1159/000067473
7. Stey C, Steurer J, Bachmann S, et al. The effect of oral N-acetylcysteine in chronic bronchitis: aquantitative systematic review. Eur Respir J 2000;16:253-62. https://doi.org/10.1034/j.1399-3003.2000.16b12.x
8. Kauffman CA. Quandary about treatment of aspergillomas persists. Lancet 1996;347:1640. https://doi.org/10.1016/s0140-6736(96)91481-6
9. Perez-Giraldo C, Rodriguez-Benito A, Moran FJ, et al. Influence of N-acetylcysteine on the formation of biofilm by Staphylococcus epidermidis. J Antimicrob Chemother 1997;39:643-6. https://doi.org/10.1093/jac/39.5.643
10. Marchese A, Bozzolasco M, Gualco L, et al. Effect of fosfomycin alone and in combination with N-acetylcysteine on E. coli biofilms. Int J Antimicrob Agents 2003;22:95-100. https://doi.org/10.1016/s0924-8579(03)00232-2
11. Schwandt LQ, Van Weissenbruch R, Stokroos I, et al. Prevention of biofilm formation by dairy products and N-acetylcysteine on voice prostheses in an artificial throat. Acta Otolaryngol 2004;124:726-31. https://doi.org/10.1080/00016480410022516
12. Zhao T, Liu Y. N-acetylcysteine inhibit biofilms produced by Pseudomonas aeruginosa. BMC Microbiol 2010;10:140. https://doi.org/10.1186/1471-2180-10-140
13. Dohar JE, Alper CM, Rose EA, et al. Treatment of chronic suppurative otitis media with topical ciprofloxacin. Ann Otol Rhinol Laryngol 1998;107(10 Pt 1):865-71. https://doi.org/10.1177/000348949810701010
14. Alper CM, Dohar JE, Gulhan M, et al. Treatment of chronic suppurative otitis media with topical tobramycin and dexamethasone. Arch Otolaryngol Head Neck Surg 2000;126:165-73. https://doi.org/10.1001/archotol.126.2.165
15. Saylam G, Tatar EC, Tatar I, et al. Association of adenoid surface biofilm formation and chronic otitis media with effusion. Arch Otolaryngol Head Neck Surg 2010;136:550-5. https://doi.org/10.1001/archoto.2010.70
16. El-Feky MA, El-Rehewy MS, Hassan MA, et al. Effect of ciprofloxacin and N-acetylcysteine on bacterial adherence and biofilm formation on ureteral stent surfaces. Pol J Microbiol 2009;58:261-7.
17. Onger ME, Gocer H, Emir D, et al. N-acetylcysteine eradicates Pseudomonas aeruginosa biofilms in bone cement. Scanning 2016;38:766-70. https://doi.org/10.1002/sca.21326
18. Ozcan C, Görür K, Cinel L, et al. The inhibitory effect of topical N-acetylcysteine application on myringosclerosis in perforated rat tympanic membrane. Int J Pediatr Otorhinolaryngol 2002;63:179-84. https://doi.org/10.1016/s0165-5876(01)00640-1
19. Yamada M, Tsukimura N, Ikeda T, et al. N-acetyl cysteine as an osteogenesis-enhancing molecule for bone regeneration. Biomaterials 2013;34:6147-56. https://doi.org/10.1016/j.biomaterials.2013.04.064
20. Choe WT, Murray MT, Stidham KR, et al. N-acetylcysteine as an adjunct for refractory ear infections. Otol Neurotol 2007;28:1022-5.

ACTA OTORHINOLARYNGOLOGICA ITALICA 2020;40:463-465; doi: 10.14639/0392-100X-N0820

Letter to the Editor

Vertigo and hearing loss during the COVID-19 pandemic – is there an association?

La vertigine e l'ipoacusia durante la pandemia COVID-19 – esiste un nesso?

Mahboobeh Karimi-Galougahi[1,2], Ali Safavi Naeini[1,2], Nasim Raad[1,2], Narges Mikaniki[3], Jahangir Ghorbani[1,2]

[1] Department of Otolaryngology, Masih Daneshvari Hospital, Tehran, Iran; [2] Chronic Respiratory Disease Research Center, National Research Institute of Tuberculosis and Lung Diseases, Shahid Beheshti University of Medical Sciences, Tehran, Iran; [3] Department of Otolaryngology, Iranshahr University of Medical Sciences, Sistan and Baluchestan, Iran

KEY WORDS: vertigo, hearing loss, sensorineural hearing loss, COVID-19, corona virus

PAROLE CHIAVE: *vertigine, ipoacusia, ipoacusia neurosensoriale, COVID-19, corona virus*

Dear Editor,

Concurrent with the global outbreak of coronavirus disease-2019 (COVID-19), exceeding numbers of new cases with smell and taste disorders have been reported from Asia and Europe [1], prompting the possibility of direct neuropathic effect of severe acute respiratory syndrome-coronavirus-2 (SARS-CoV-2) as the likely underlying mechanism. Post-viral olfactory dysfunction is a well-known disease entity caused by several families of viruses, including betacoronoviridae [2]. Akin to the effects of viruses on neural pathways of olfactory sense, post-viral vertigo or hearing loss are known sequelae of viruses that can cause vestibular neuritis or labyrinthitis [3]. For instance, the DNA of herpes simplex virus has been found in the vestibular nerve fibres in patients with vertigo secondary to vestibular neuritis [3].

Whether SARS-CoV-2 can invade the neural pathways involved in the balance and hearing is not known, but initial observations implicate the possibility. A recent study in asymptomatic patients with confirmed COVID-19 revealed increased high-frequency pure-tone thresholds while transient evoked otoacoustic emissions were significantly reduced, all in the absence of otologic symptoms [4]. While coronaviruses have neurotropic and neuroinvasive properties [5,6], after a search in the English literature we found no cases suggestive of the inner ear or vestibulocochlear nerve involvement during the SARS-CoV or Middle Eastern respiratory syndrome (MERS) outbreak.

Nevertheless, neurologic manifestations spanning the central nervous system, peripheral nervous system and skeletal muscles have been recently reported in hospitalised patients with COVID-19 [7]. Most neurologic manifestations occurred early in the illness and neurologic symptoms were the only presenting symptoms in some patients without other typical symptoms of COVID-19 [7]. The spectrum of neurologic syndromes known to be caused by COVID-19 encompasses encephalitis, meningitis, demyelination and Guillain-Barre syndrome [7,8]. Thus, SARS-CoV-2 neurotropism may make it possible to inflict a wide spectrum of neuropathic effects, potentially including effects on neural networks governing hearing and balance.

In addition to a direct cytopathic effect of the virus, inflammatory response,

Received: May 1, 2020
Accepted: May 18, 2020
Published online: June 10, 2020

Correspondence
Jahangir Ghorbani
Department of Otolaryngology, Masih Daneshvari Hospital, Neyavran, Daar Abad, Tehran, Iran
Tel. +98 21 26105242. Fax +98 21 26105242
E-mail: jghorbani@sbmu.ac.ir

Funding
None.

Conflict of interest
The Authors declare no conflict of interest.

How to cite this article: Karimi-Galougahi M, Naeini AS, Raad N, et al. Vertigo and hearing loss during the COVID-19 pandemic - is there an association? Acta Otorhinolaryngol Ital 2020;40:463-465. https://doi.org/10.14639/0392-100X-N0820

© Società Italiana di Otorinolaringoiatria e Chirurgia Cervico-Facciale

OPEN ACCESS

This is an open access article distributed in accordance with the CC-BY-NC-ND (Creative Commons Attribution-Non-Commercial-NoDerivatives 4.0 International) license. The article can be used by giving appropriate credit and mentioning the license, but only for non-commercial purposes and only in the original version. For further information: https://creativecommons.org/licenses/by-nc-nd/4.0/deed.en

Table I. Demographic and clinical characteristics of patients with acute hearing loss or vertigo and high clinical suspicion for/or confirmed coronavirus disease-2019 (COVID-19).

N	Demographic and clinical characteristics				General symptoms	Otologic or balance symptoms			Pure tone audiometry - bone (dB)					
	Sex	Age (years)	FH of COVD-19	PCR		Tinnitus	Vertigo	Laterality of hearing loss	500	1000	2000	3000	4000	8000
1	F	34	-	Pending	Dyspnoea, Cough	-	Slight	Right	0	0	0	20	60	90
2	M	22	-	+	Dyspnoea, Cough	-	-	Left	0	0	30	40	60	70
3	F	40	-	+	Dyspnoea, Cough, Malaise	+	-	Right	50	60	60	60	65	80
4	M	38	-	-	Dyspnoea, Cough, Fever	+	-	Right	40	50	55	60	70	80
5	F	23	+	+	Dyspnoea, Cough	+	+	Left	30	35	35	40	45	45
6	F	35	-	-	Dyspnoea, Cough, Fever	+	-	Right	40	40	45	45	50	60

dB: decibel, FH: family history, N: number, PCR: polymerase chain reaction

cytokine storm and cerebrovascular events [7,8], especially in the posterior circulation [9], and ototoxic drugs like azithromycin, hydroxychloroquine being used extensively during the nascent pandemic as therapeutic agents may also contribute to hearing or balance disorders associated with COVID-19. Anecdotally, during recent weeks, we have frequently encountered patients without previous otologic or neurologic problems who presented with true vertigo or sensorineural hearing loss. While initially none of these cases were tested for COVID-19 due to the scarcity of the screening tests and the priority given to the patients with typical symptoms or severe form of COVID-19, some had family members with recent history of COVID-19, with the universal concomitant presence of symptoms such as fever, cough and dyspnoea, pointing to high clinical suspicion for COVID-19 that in some patients (e.g., patient number 6 in Tab. I) led to diagnosis of COVID-19 on chest computed tomography.

Recently, we have been able to perform polymerase chain reaction (PCR) assay to confirm COVID-19 in a number of patients with acute-onset hearing loss and/or vertigo (Tab. I). Since these young patients (age range 22-40 years) had no previous relevant medical history and had not received any ototoxic drugs prior to their presentation, it is highly likely that these otologic symptoms are directly related to/caused by COVID-19, especially since pure tone audiometry revealed a sensory-neural mechanism for the unilateral hearing loss (Tab. I).

These recent confirmed cases of COVID-19, the anecdotal epidemiological correlations and bio-pathological mechanisms call for urgent studies to examine the association of new onset otologic symptoms with COVID-19 during the current pandemic. There are several important issues to address. First priority is in performing screening PCR tests, which are hoped to become more widely available than during the early phase of the pandemic, to establish a link, especially in cases with isolated hearing loss or balance disorder. Absent the availability of PCR assay, and if the hearing or balance problems are not associated with respiratory symptoms, it is debatable whether imaging such as chest computed tomography should be considered, although with an increasing number of "clinically silent" cases of pulmonary involvement with SARS-CoV-2 being recognised, this approach may be clinically justifiable. Last, apart from implications on the need for patient isolation, there are immediate therapeutic dilemmas including the use of local or systemic steroids and whether empiric antivirals should be considered.

References

1 Lechien JR, Chiesa-Estomba CM, De Siati DR, et al. Olfactory and gustatory dysfunctions as a clinical presentation of mild to moderate forms of the Coronavirus disease (COVID-19): a multicenter European study. Eur Arch Otorhinolaryngol 2020;277:2251-61. https://doi.org/10.1007/s00405-020-05965-1

2 Passioti M, Maggina P, Megremis S, et al. The common cold: potential for future prevention or cure. Curr Allergy Asthma Rep 2014;14:413. https://doi.org/10.1007/s11882-013-0413-5

3 Goddard JC, Fayad JN. Vestibular neuritis. Otolaryngol Clin N Am 2011;44:361-5. https://doi.org/10.1016/j.otc.2011.01.00

4 Mustafa MWM. Audiological profile of asymptomatic Covid-19 PCR-positive cases. Am J Otolaryngol 2020;41:102483. https://doi.org/10.1016/j.amjoto.2020.102483

5 Li YC, Bai WZ, Hashikawa T. The neuroinvasive potential of SARS-CoV2 may be at least partially responsible for the respiratory failure of COVID-19 patients. J Med Virol 2020;92:552-5. https://doi.org/10.1002/jmv.25728

6 Netland J, Meyerholz DK, Moore S, et al. Severe acute respiratory syndrome coronavirus infection causes neuronal death in the absence of encephalitis in mice transgenic for human ACE2. J Virol 2008;82:7264-75. https://doi.org/10.1128/JVI.00737-08

7 Mao L, Jin H, Wang M, et al. Neurologic manifestations of hospitalized patients with Coronavirus disease 2019 in Wuhan, China. JAMA Neurol 2020;77:683-90. https://doi.org/10.1001/jamaneurol.2020.1127

8 Ashrafi MR, Azizimalamiri R, Badv RZ, et al. Coronavirus, its neurologic manifestations, and complications. Iran J Pediatr Epub 2020;30:e102569. https://doi.org/10.5812/ijp.102569

9 Venhovens J, Meulstee J, Verhagen WIM. Acute vestibular syndrome: a critical review and diagnostic algorithm concerning the clinical differentiation of peripheral versus central aetiologies in the emergency department. J Neurol 2016;263:2151-7. https://doi.org/10.1007/s00415-016-8081-8

ACTA OTORHINOLARYNGOLOGICA ITALICA 2020;40:466-468; doi: 10.14639/0392-100X-N0884

Letter to the Editor

Looking at the day after COVID-19… what laryngeal sequelae should we expect?

Guardando all'era post COVID-19… quali sequele laringee dobbiamo attenderci?

Sara Torretta[1,2], Lorenzo Maria Gaini[1], Michele Gaffuri[1], Lorenzo Pignataro[1,2], Remo Accorona[1], Pasquale Capaccio[1,3]

[1] Fondazione IRCCS Ca' Granda Ospedale Maggiore Policlinico, Milan, Italy; [2] Università degli Studi di Milano, Department of Clinical Sciences and Community Health, Milan, Italy; [3] Università degli Studi di Milano, Department of Biomedical Surgical Dental Science, Milan, Italy

KEY WORDS: SARS-CoV-2, coronavirus, COVID-19, tracheotomy, dysphagia, laryngeal stenosis

PAROLE CHIAVE: *SARS-CoV-2, coronavirus, COVID-19, tracheotomia, disfagia, stenosi laringee*

Dear Editor,
airway management is crucial in effective treatment of COVID-19 patients with critical/severe disease. In the literature, the risk of nosocomial SARS-CoV-2 transmission ascribable to increased request for tracheostomy continues to be debated [1,2]; in addition, we have to take into account that, once the acute phase passes, we may have to face other problems, such as laryngo-tracheal sequelae following prolonged endotracheal intubation and tracheostomy [3]. Now that infectious spreading and contagion has been steadily decreasing in Italy, we observed an escalation in requests for ENT consultation for laryngeal complaints in COVID-19 patients who underwent endotracheal intubation or tracheostomy, independently of age, and were able to overcome the critical stage of disease at our frontline hospital in Milan, located in epicentre of the Italian COVID-19 epidemic. Several factors could be responsible for a remarkable prevalence of laryngeal dysfunction in post-acute COVID-19 patients:

- more time needed for respiratory weaning resulting in prolonged endotracheal intubation/tracheostomy maintenance to continuous positive airway pressure ventilation;
- the use of high-pressure ventilation to treat acute respiratory distress syndrome;
- Adoption of surgical and anaesthesiologic protocols aimed at reducing dispersal of infected aerosols during/after endotracheal intubation and tracheostomy performance [1,2], such as: the use of non-fenestrated and cuffed tubes with adequate cuff inflation, reduction/avoidance of tracheostomy change [1,2];
- poor pulmonary performance and hypoxaemia with increased respiratory rate, negatively affecting the respiration/swallowing balance;
- a possible reduced cortical/subcortical laryngeal coordination due to peripheral and/or central SARS-CoV-2 neuroinvasive propensity through a synapse-connected route [4,5], suspected on the grounds of documented neurological complaints and smell impairment [4].

On one hand, this scenario results in perpetuation of mucosal trauma and mechanical lesions/scaring leading to reduced laryngo-tracheal patency. On the other hand, laryngeal/hypopharyngeal sensation as well as airway protection are reduced; muscle weakness and atrophy related to disuse and critical illness

Received: May 26, 2020
Accepted: June 9, 2020
Published online: September 24, 2020

Correspondence
Sara Torretta
Department of Clinical Sciences and Community Health, Università degli Studi di Milano, Fondazione IRCCS Ca' Granda Ospedale Maggiore Policlinico, via F. Sforza 35, 20122 Milano, Italy
Tel. +39 02 50320245. Fax +39 02 50320248
E-mail: sara.torretta@unimi.it

Funding
None.

Conflict of interest
The Authors declare no conflict of interest.

How to cite this article: Torretta S, Gaini LM, Gaffuri M, et al. Looking at the day after COVID-19… what laryngeal sequelae should we expect? Acta Otorhinolaryngol Ital 2020;40:466-468. https://doi.org/10.14639/0392-100X-N0884

© Società Italiana di Otorinolaringoiatria e Chirurgia Cervico-Facciale

OPEN ACCESS

This is an open access article distributed in accordance with the CC-BY-NC-ND (Creative Commons Attribution-Non-Commercial-NoDerivatives 4.0 International) license. The article can be used by giving appropriate credit and mentioning the license, but only for non-commercial purposes and only in the original version. For further information: https://creativecommons.org/licenses/by-nc-nd/4.0/deed.en

myopathy and neuropathy with impairment in coordination of respiration/swallowing pattern may occur and predispose to swallowing disorders [6].

In the post-COVID era, we must be prepared to deal with an increased prevalence of patients with laryngo-tracheal sequelae, and to adequately manage them, also considering that the therapeutic approach can be troublesome and outcomes are not always predictable. In addition, traditional diagnostic and rehabilitative pathways have been reconsidered and applied only to urgent cases [7-9], and optimising non-instrumental swallowing assessment tools as an alternative to fiberoptic endoscopic evaluation is difficult to carry out in a short-time period. All of this may cause further difficulties in management.

A proposed follow-up schedule to be considered by ENT specialists for post-critical assessment of COVID-19 patients with documented or suspected laryngeal sequelae after intensive care management is presented in Figure 1.

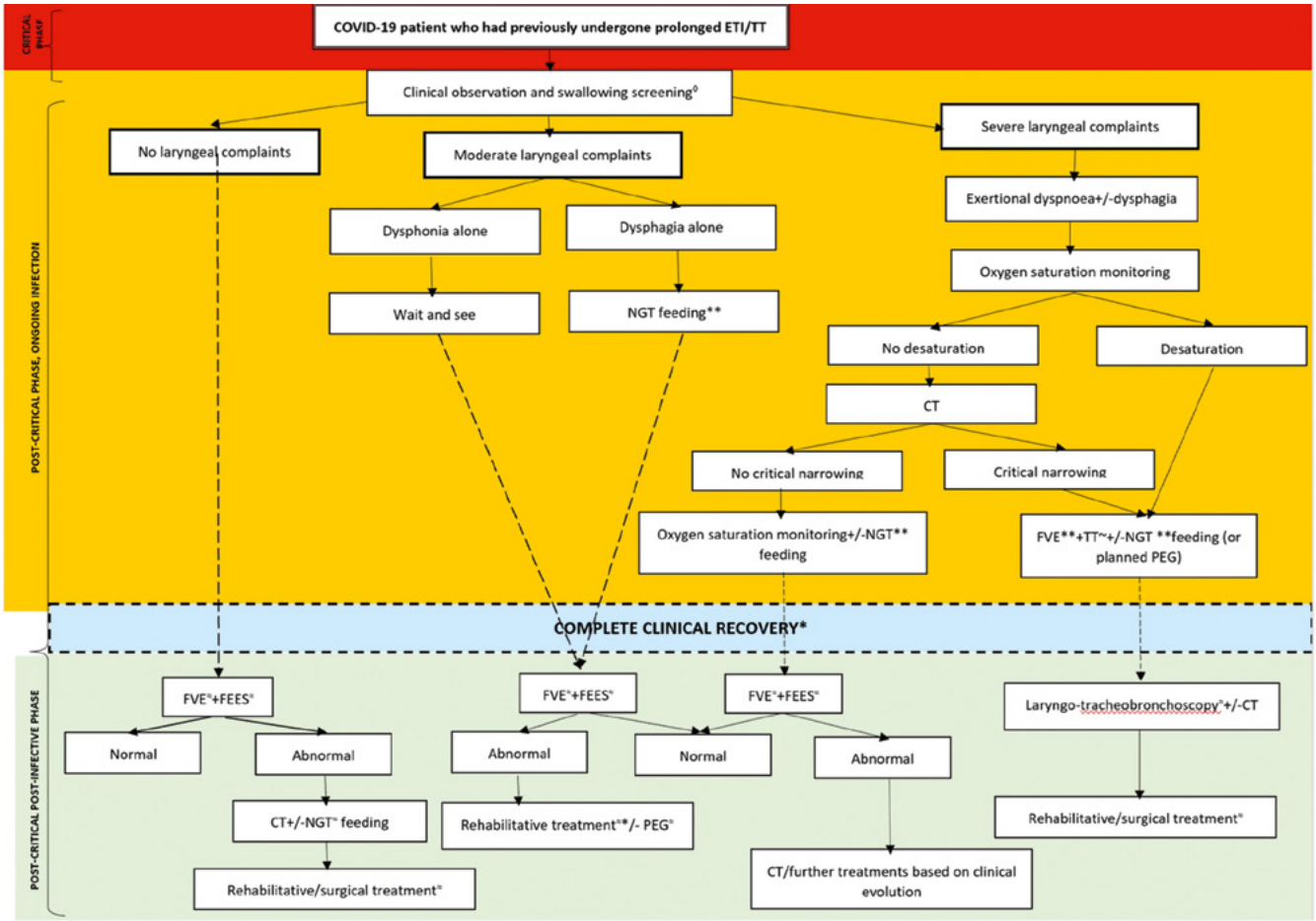

Legend:
COVID-19: coronavirus 2019 disease;
ETI: endotracheal intubation;
TT: temporary tracheostomy;
FEES: fiberoptic endoscopic evaluation of swallowing;
FVE: fiberoptic videoendoscopy;
NGT: nasogastric tube;
PEG: percutaneous endoscopic gastrostomy;
*Defined by negative findings obtained by two nasopharyngeal swabs, with the first one performed 14 days after hospital discharge, and the second one 48 hours after the former;
**Procedures to be performed with the use of high-level dedicated personal protective equipment.[7-9]
~Performed according to international guidelines and safety protocols.[1,2]
◊ Based on screening tools[10] and precociously (1-5 days after extubation) administered by the nursing staff in order to minimize contacts.[5,8]
" Procedures to be performed with the use of standard/high-level dedicated personal protective equipment.[7]

Figure 1. Proposal of a follow-up schedule for post-critical assessment of COVID-19 patients with documented or suspected laryngeal sequelae after intensive care management.

References

1. Sommer DD, Engels PT, Weitzel EK, et al. Recommendations from the CSO-HNS taskforce on performance of tracheotomy during the COVID-19 pandemic. J Otolaryngol Head Neck Surg 2020;49:23. https://doi.org/10.1186/s40463-020-00414-9
2. David AP, Russell MD, El-Sayed IH, et al. Tracheostomy guidelines developed at a large academic medical center during the COVID-19 pandemic. Head Neck 2020;42:1291-6. https://doi.org/10.1002/hed.26191
3. Goldsmith T. Evaluation and treatment of swallowing disorders following endotracheal intubation and tracheostomy. Int Anesthesiol Clin 2000;38:219-2. https://doi.10.1097/00004311-200007000-00013
4. Yashavantha Rao HC, Jayabaskaran C. The emergence of a novel coronavirus (SARS-CoV-2) disease and their neuroinvasive propensity may affect in COVID-19 patients. J Med Virol 2020;92:786-90. https://doi.org/10.1002/jmv.25918
5. Dziewas R, Warnecke T, Zürcher P, et al. Dysphagia in COVID-19 - multilevel damage to the swallowing network? Eur J Neurol 2020;27:e46-7. https://doi.org/10.1111/ene.14367
6. Kiekens C, Boldrini P, Andreoli A, et al. Rehabilitation and respiratory management in the acute and early post-acute phase. "Instant paper from the field" on rehabilitation answers to the Covid-19 emergency. Eur J Phys Rehabil Med 2020;56:323-6. https://doi.org/10.23736/S1973-9087.20.06305-4
7. Ku PKM, Holsinger FC, Chan JYK, et al. Management of dysphagia in the patient with head and neck cancer during COVID-19 pandemic: practical strategy. Head Neck 2020;42:1491-6. https://doi.org/10.1002/hed.26224
8. Frajkova Z, Tedla M, Tedlova E, et al. Postintubation dysphagia during COVID-19 outbreak-contemporary review. Dysphagia 2020;28:1-9. https://doi.org/10.1007/s00455-020-10139-6
9. Mattei A, Amy de la Bretèque B, Crestani S, et al. Guidelines of clinical practice for the management of swallowing disorders and recent dysphonia in the context of the COVID-19 pandemic. Eur Ann Otorhinolaryngol Head Neck Dis 2020;137:173-5. https://doi.org/10.1016/j.anorl.2020.04.011
10. Zuercher P, Moret CS, Dziewas R, et al. Dysphagia in the intensive care unit: epidemiology, mechanisms, and clinical management. Crit Care 2019;23:103. https://doi.org/10.1186/s13054-019-2400-2

ACTA OTORHINOLARYNGOLOGICA ITALICA 2020;40:469-470

In Memoriam of

Oskar Schindler

We could remember Professor Schindler as an unforgettable university professor, as the founder of scientific societies such as the European Phoniatric Union in 1971, the Italian Society of Phoniatrics and Speech Therapy in 1985, the Italian Study Group of Dysphagia in 2004, of the scientific popularizer with books that have marked the scientific culture, but among the many aspects that we could list in remembering him, the first that comes to mind is that of a generous person: he had the rare ability to share with everyone, regardless of the role covered, his experiences, simply for the pleasure of sharing and discussion. The term 'maieuta' could be used for him thanks to its ability to make those around him grow.

Born in Torre Pellice (TO) in 1936 and graduated in Medicine and Surgery in 1961, Oskar Schindler specialised in Otolaryngology in 1964. In 1981 he was appointed Associate Professor and, in 2001, Full Professor in Audiology and Phoniatrics at the University of Turin. From 1997 to 2008 he was Director of the S.C. of Audiology and Phoniatrics at the Molinette Hospital in Turin. Subsequently he maintained teaching in the various degree courses of the University of Turin.

Universally recognised among the creators of Italian Phoniatrics, we remember his intense teaching activity in ENT and in all the related specialties such as Audiology, Phoniatrics, Speech Therapy, Audiometry, Audioprosthesis, NPI, Neurophysiopathology, Otorhinolaryngology, Geriatrics and Physiotherapy, learning various courses of degree and in specialisation schools, followed and loved by students who appreciated his storytelling talent, his ability to improvise, and his profound humanity.

A great traveler, he spoke German, French, English and Spanish perfectly and had contacts with scholars from all over the world who had led him to lecture abroad, in Europe and Latin America.

Already at the end of the 60s of the last century he had the merit of considering hearing, voice and speech disorders as more complex phenomena and a strongly multidisciplinary character, connoting these disorders in the area of physiopathology of human communication, using the central concept of communication as a very broad and ductile semantic field, which proceeds dialectically from a purely linguistic pole (auditory-verbal-phonatory), to multimodal communication that runs through different channels (optical-mimic-gestural , optical, graphic-plastic), with more or less sophisticated and complex methods.

This intuition from the end of the 1970s has had a very strong impact on the Italian speech therapy area with the progressive extension of skills to all age groups of the population, including the elderly, and the progressive expansion of pathological pictures of rehabilitation interest.

© Società Italiana di Otorinolaringoiatria
e Chirurgia Cervico-Facciale

OPEN ACCESS

This is an open access article distributed in accordance with the CC-BY-NC-ND (Creative Commons Attribution-Non-Commercial-NoDerivatives 4.0 International) license. The article can be used by giving appropriate credit and mentioning the license, but only for non-commercial purposes and only in the original version. For further information: https://creativecommons.org/licenses/by-nc-nd/4.0/deed.en

At the end of the 80s, thanks to international and interdisciplinary collaborations, he was one of the founders of the deglutological science, considered as the study of the physiopathology of swallowing publishing, in 2000, the first edition of the text of Deglutology and since 2004 the creation of the University Master in Deglutology at the University of Turin, a master which still continues with an increasing demand for participation.
The profound personal culture and the interest in the different sectors of knowledge led Oskar Schindler to interact with the neighboring medical fields (ENT, audiology, neurology, psychiatry, child neuropsychiatry, dietology and clinical nutrition, physiatry, etc.) and non-medical (speech therapy, acoustics, linguistics, anthropology, ethology, pedagogy and teaching, sociology, etc.). In this sense he was a great stimulus, collaborating with many social agencies in the city of Turin and in Piemonte and in the rest of Italy.
When the news of his disappearance spread, all the people of his students huddled in a virtual embrace of messages and phone calls, as if it were the loss of a family member; certainly we have all lost a great father and friend who guided us in knowledge and professional rigor but he was also close to us with encouragement and advice.
We are left with his precious teachings and the task of continuing our work as he taught us to do.

Roberto Albera, Massimo Spadola Bisetti

Notiziario SIO

CONSIGLIO DIRETTIVO SIO (2020-2021)

Paludetti G.	Presidente	(Scad. Maggio 2021)
Cuda D.	Vice-Presidente	(Scad. Maggio 2021)
Danesi G.	Vice-Presidente	(Scad. Maggio 2022)
Succo G.	Segretario	(Scad. Maggio 2022)
Ruscito P.	Tesoriere	(Scad. Maggio 2022)
Ralli G.	Bibliotecario	(Scad. Maggio 2021)
Rigante M.	Segretario del Presidente	(Scad. Maggio 2021)
Boscolo Rizzo P.	Consigliere	(Scad. Maggio 2021)
Bussi M.	Past President	(Scad. Maggio 2021)
Bruschini L.	Consigliere	(Scad. Maggio 2021)
Cocuzza S.	Consigliere	(Scad. Maggio 2021)
De Campora L.	Consigliere	(Scad. Maggio 2021)
Fiorella ML.	Consigliere	(Scad. Maggio 2021)
Magnani M.	Consigliere	(Scad. Maggio 2021)
Miani C.	Consigliere	(Scad. Maggio 2021)
Panetti G.	Consigliere	(Scad. Maggio 2021)
Radici M.	Consigliere	(Scad. Maggio 2022)
Trimarchi M.	Consigliere	(Scad. Maggio 2021)

Coordinatore del controllo di qualità SIO

Della Vecchia L. (Scad. Maggio 2021)

Responsabile sito Web SIO

Capasso P. (Scad. Maggio 2021)

Referente Privacy SIO

Pisani P. (Scad. Maggio 2021)

Comitato Scientifico SIO

Coordinatore Comitato Scientifico SIO
Cassandro E. (Scad. Maggio 2021)

Segretario Comitato Scientifico SIO
Della Vecchia L. (Scad. Maggio 2021)

Membri Comitato Scientifico SIO

Paludetti G.	Presidente SIO	(Scad. Maggio 2021)
Succo G.	Segretario SIO	(Scad. Maggio 2022)
Ansarin M.	Direttore responsabile Rivista	(Scad. Maggio 2022)
Cassandro E.	Comitato Audiol/foniat/Vestibol	(Scad. Maggio 2021)
Camaioni A.	Comitato Laringologia	(Scad. Maggio 2021)
Castelnuovo P.	Comitato Rinologia	(Scad. Maggio 2021)
Passali D.	Comitato Dist. Resp. sonno	(Scad. Maggio 2021)
Piemonte M.	Comitato Day surgery	(Scad. Maggio 2021)
Danesi G.	Comitato Otologia/Otoneurologia	(Scad. Maggio 2021)
Nicolai P.	Comitato Oncologia/Ch. Ricostruttiva	(Scad. Maggio 2021)

© Società Italiana di Otorinolaringoiatria e Chirurgia Cervico-Facciale

OPEN ACCESS

Organo di Consulenza SIO

Ansarin M., Camaioni A., Casolino D., Cassandro E., Conticello S., Coppo L., De Benedetto M., De Campora E., Filipo R., Fiorella R., Laudadio P., Leone C.A., Nicolai P., Ottaviani A., Pagella F., Passali D., Paludetti G., Piemonte M., Puxeddu P., Radici M., Ralli G., Rinaldi Ceroni A., Sartoris A., Scasso F., Serra A., Sperati G., Spriano G., Vicini C.

Comitato permanente per l'aggiornamento dello statuto e del regolamento

Paludetti G.	Presidente SIO	(Scad. Maggio 2021)
Lauriello M.	Segretario AUORL	(Scad. Maggio 2021)
De Campora L.	Segretario AOOI	(Scad. Maggio 2022)
Succo G.	Segretario SIO	(Scad. Maggio 2022)
Berrettini S., Bussi M., Quaranta N.	AUORL	(Scad. Maggio 2021)
Ghidini A., Frosini P., Viti C.	AOOI	(Scad. Maggio 2021)

Revisori dei conti SIO

Salzano F	(Scad. Maggio 2022)
Sessa M.	(Scad. Maggio 2022)

Collegio dei Proibiviri SIO

Camaioni A.	(Scad. Maggio 2022)
Filipo R.	(Scad. Maggio 2022)
Leone CA.	(Scad. Maggio 2022)
Serra A.	(Scad. Maggio 2022)
Spriano G.	(Scad. Maggio 2022)

Delegati

EUFOS	Marsella P.	(Scad. Maggio 2021)
	Martini A.	(Scad Maggio 2021)
IFOS	Piemonte M.	(Scad. Maggio 2021)
	Galli J.	(Scad Maggio 2021)
UEMS	Miani C.	(Scad. Maggio 2021)
	Motta Ga.	(Scad Maggio 2021)
EHNS	Calabrese L.	(Scad. Maggio 2021)
	Motta Ga.	(Scad Maggio 2021)

Temi scientifici 2020-2022

Relazione ufficiale 2021

"Patologie di confine in Otorinolaringoiatria e loro trattamento" *a cura di Gaetano Paludetti*

Acknowledgements to our reviewers

The Editor-in-Chief and the Editorial Board of *Acta Otorhinolaryngologica Italica* are extremely grateful to all the colleagues who, during 2020, together with the Scientific Committee, kindly reviewed the scientific papers submitted for publication, contributing to a meticulous selection of the material and appropriate re-elaboration of the manuscripts:

Albera Andrea
Alicandri Ciufelli Matteo
Allevi Fabiana
Alterio Daniela
Aluffi Paolo
Aprile Federico
Arosio Alberto Daniele
Asprella Libonati Giacinto
Astolfi Laura
Bandi Francesco
Barbieri Marco
Bellocchi Gianluca
Bellussi Luisa Maria
Bertolin Andy
Bianchin Giovanni
Biglioli Federico
Boccuzzi Simone
Bonali Marco
Borsetto Daniele
Boscolo Rizzo Paolo
Bossi Paolo
Bossolesi Paolo
Bottero Sergio
Bovo Roberto
Brescia Giuseppe
Briner Hans Rudolf
Brotto Davide
Bruschini Luca
Canale Andrea
Canevari Frank Rikki
Cantone Elena
Cantù Giulio
Canzi Pietro
Capaccio Pasquale
Cassano Michele
Castelluccio Andrea
Cavalot Andrea
Cazzador Diego
Chiesa Fausto
Chiocca Susanna
Cingi Cemal
Ciniglio Mario
Cocchi Roberto
Cocuzza Salvatore
Comacchio Francesco
Constantinidis Jannis
Corvò Renzo
Cossu Rocca Maria
Covelli Edoardo
Cristofari Eliana
Crosetti Erika
Dallan Iacopo
De Benedetto Luigi
De Benedetto Michele
De Seta Daniele
De Virgilio Armando
De Vito Andrea
Dispenza Francesco
Fadda Gianluca
Falcioni Maurizio
Farneti Paolo
Farneti Daniele
Fattori Bruno
Favaretto Niccolò
Felisati Giovanni
Ferrari Marco
Forli Francesca
Franchella Sebastiano
Galli Jacopo
Gallo Oreste
Gallo Stefania
Garzaro Massimiliano
Genovese Elisabetta
Georgalas Christos
Ghidini Angelo
Giordano Leone
Giourgos Georgios
Gramellini Giulia
Grandi Cesare
Greco Antonio
Gufoni Mauro
Herman Philippe
Konstantinidis Iordanis
Landis Basile
Lauriello Maria
Leemans C. René
Lenzi Riccardo
Leone Federico
Lombardi Davide
Lucidi Daniela
Luzzi Sabino
Macchi Alberto
Maffini Fausto Antonio
Magnani Massimo
Magnetto Marianna
Magrini Stefano
Malvezzi Luca
Manfrin Marco
Manzoni Marco Federico
Marchese-Ragona Rosario
Marioni Gino
Marzetti Andrea
Mattavelli Davide
Mattoscio Domenico
Meco Cem
Melis Andrea
Mercante Giuseppe
Mesolella Massimo
Mevio Nicolò
Miani Cesare
Minghetti Domenico
Molteni Gabriele
Montevecchi Filippo
Mozzanica Francesco
Murri Alessandra
Nardone Massimiliano
Neri Giampiero
Nicolai Piero
Ottaviano Giancarlo
Paderno Alberto
Pagella Fabio Giuseppe
Palladino Remo
Pasquini Ernesto
Passali Giulio Cesare
Pecci Rudi
Pellini Raul
Peretti Giorgio
Petrone Paolo
Piantanida Renato
Piazza Cesare
Piemonte Marco
Pipolo Carlotta
Presutti Livio
Preti Andrea
Pusateri Alessandro
Puxeddu Roberto
Quaglieri Silvia
Quaranta Nicola
Rampinelli Vittorio
Ricci Maccarini Andrea
Romano Giuseppe
Russi Elvio
Salamanca Fabrizio
Schindler Antonio
Schreiber Alberto
Seccia Veronica
Seregni Ettore
Sesenna Enrico
Soloperto Davide
Sorrenti Giovanni
Sorrentino Flavia
Sorrentino Tommaso
Spadola Bisetti Massimo
Succo Giovanni
Swift Andrew
Teggi Roberto
Tomazic Peter Valentin
Torroni Andrea
Tucci Filippo Maria
Turri-Zanoni Mario
Vadalà Giuseppe
Varini Alessandro
Verillaud Benjamin
Volpi Luca
Zabrodsky Michal

© Società Italiana di Otorinolaringoiatria e Chirurgia Cervico-Facciale

OPEN ACCESS