

"Step by step" treatment of lateral semicircular canal canalolithiasis under videonystagmoscopic examination

Riabilitazione "step by step" della canalolitiasi del canale semicircolare laterale sotto controllo videonistagmoscopico

G. ASPRELLA LIBONATI, G. GAGLIARDI, D. CIFARELLI, G. LAROTONDA
Department of Otorhinolaryngology and Head-Neck Surgery, Hospital of Matera, Italy

Key words

Vertigo • Benign paroxysmal positional vertigo • Canalolithiasis • Lateral semicircular canal • Therapy • Liberatory manoeuvres

Parole chiave

Vertigine • Vertigine parossistica posizionale benigna • Canalolitiasi • Canale semicircolare laterale • Terapia • Manovre liberatorie

Summary

Aim of the work was to describe a new physical therapeutic approach for benign paroxysmal positional vertigo determined by canalolithiasis of the lateral semicircular canal. A review is made of the literature, and personal experience is reported. A total of 55 cases were observed, 40 geotropic forms, 15 apogeotropic forms. Liberatory manoeuvres were carried out observing the nystagmus during videonystagmoscopic examination, thus attempting to solve the problem in the first treatment session. Monitoring the patient under videonystagmoscopic examination, progression of the otolithic mass towards the non-ampullary segment is documented by the appearance of a nystagmus directed towards the healthy side (and, therefore, inhibitory, due to ampullofugal deflection of the ampullary cupula) during the individual steps of the rehabilitation treatment. Of the 40 geotropic forms, 30 were successfully treated with the Vannucchi-Asprella technique, and the other 10 with the Vannucchi-Asprella manoeuvre followed by a Lempert barbecue rotation. Of the 15 apogeotropic forms, 6 were solved with the Vannucchi-Asprella manoeuvre, 2 with the Vannucchi-Asprella technique followed by Lempert, 6 with the inverted Gufoni technique, followed by Lempert, 1 transformed into geotropic with inverted Gufoni plus Lempert and then resolved by means of a Vannucchi-Asprella manoeuvre. In all cases, therapeutic success was achieved in the first session. Treatment of benign paroxysmal positional vertigo of the lateral semicircular canal does not allow every case to be fully solved at the first attempt with any technique proposed up to now, in particular, for the apogeotropic forms. Being aware of the different techniques, choosing that most appropriate for the patient's "physical" needs, and, above all, verifying under videonystagmoscopic examination the progression in an ampullofugal direction of the otolithic mass during treatment enable excellent therapeutic results to be obtained in the treatment of benign paroxysmal positional vertigo of the lateral semicircular canal, by modifying the rehabilitation strategy while it is being carried out. Videonystagmoscopic examination monitoring of the nystagmus during treatment of benign paroxysmal positional vertigo of the

Riassunto

Lo scopo del lavoro è quello di esporre una nuova metodologia di approccio riabilitativo per la vertigine parossistica posizionale benigna da canalolitiasi del Canale Semicircolare Laterale. Dopo una revisione della letteratura, viene riportata l'esperienza degli Autori. Sono stati osservati 55 casi, di cui 40 forme geotrope e 15 apogeotrope. Le manovre riabilitative sono state eseguite osservando sempre il nistagmo sotto videonistagmoscopia, cercando così di raggiungere la risoluzione già nel corso della prima seduta terapeutica: infatti monitorizzando il paziente in videonistagmoscopia, il progredire in senso ampullifugo dell'ammasso otolitico è testimoniato dalla comparsa di un nistagmo diretto verso il lato sano (quindi inibitorio, da deflessione ampullifuga della cupola ampollare) durante l'esecuzione dei singoli step del trattamento riabilitativo. Delle 40 forme inizialmente geotrope, 30 hanno risolto con tecnica di Vannucchi-Asprella, altre 10 con manovra di Vannucchi-Asprella seguita con barbecue rotation sec. Lempert. Delle 15 forme apogeotrope, 6 hanno risolto con la manovra di Vannucchi-Asprella, 2 hanno risolto con tecnica di Vannucchi-Asprella seguita con Lempert, 6 sono giunte a guarigione con tecnica di Gufoni invertita, seguita con Lempert, 1 ha trasformato in geotropo dopo Gufoni invertita più Lempert ed ha quindi risolto con successiva manovra di Vannucchi-Asprella. In tutti i pazienti è stato conseguito il successo terapeutico nel corso della prima seduta. La riabilitazione della vertigine parossistica posizionale benigna da canalolitiasi del canale semicircolare laterale, come deducibile dalla revisione della letteratura, non consente una piena risoluzione di tutti i casi alla loro prima osservazione con nessuna delle tecniche sino ad ora proposte dai vari Autori, ed in particolare per le forme apogeotrope. Possedere buona dimestichezza con diverse tecniche, scegliere la più adatta alle esigenze "fisiche" del paziente e, soprattutto, verificare in videonistagmoscopia la progressione in senso ampullifugo dell'ammasso otolitico durante la riabilitazione, consente di ottimizzare il risultato terapeutico nel trattamento della vertigine parossistica posizionale benigna del canale semicircolare laterale, modificando la strategia riabilitativa in corso di esecuzione. Il controllo del nistagmo in videonistagmoscopia durante la riabilitazione delle vertigine parossistica posizionale benigna da canalolitiasi del canale semicircolare la-

lateral semicircular canal, is taking the place of the rigid schematism of the manoeuvres proposed, so far, allowing the treatment programme to be adapted to the individual case, thus enabling a solution to be reached in the first rehabilitation session by means of tailored therapy.

Introduction

Benign paroxysmal positional vertigo (BPPV) due to canalolithiasis of the lateral semicircular canal (LSC) is a nosologic entity that has been known for over 15 years, the first mention in the literature being made in 1985¹; the Authors describe the typical clinical picture of a BPPV of the LSC, characterised by a bidirectional horizontal geotropic nystagmus, bipositional in the lateral right and left positions.

In 1989, Pagnini et al.² reported 15 cases of BPPV of the LSC, classifying it as a true, autonomous nosologic entity. These Authors described the evolution, the symptomatological and semeiological features, advancing a hypothesis regarding the pathogenetic mechanism of the typical paroxysmal positional nystagmus (PPNy). This mechanism is explained with the endolymphatic currents induced by movement in the posterior segment of the LSC of detritus probably of otoconial origin. In rotating the pathological side, the particles sediment towards the ampulla on account of gravity, generating an utriculopetal, and, therefore, an excitatory, endolymphatic current, and the consequent nystagmus (Ny) towards the involved ear, therefore, geotropic. On rolling over to the opposite side, the particles move towards the non-ampullary segment, with an utriculofugal, and, therefore, inhibitory, endolymphatic current. The Ny generated will, therefore, again be geotropic, directed towards the lower ear, that is, towards the healthy side. The Authors stress a greater intensity of Ny on the impaired side, explained by the second law of Ewald³, which postulates that the response to an excitatory stimulus is always more intense than that following an inhibitory stimulus. This was also the first report of forms originating as apogeotropic PPNy and then transforming spontaneously into geotropic.

In 1994, Pagnini et al.⁴ reported ten other cases of BPPV of the LSC with purely bidirectional horizontal PPNy, originating as apogeotropic; they describe the semeiotic and physiopathological features, thus identifying a variant of BPPV of the LSC. An inversion of the PPNy in geotropic takes place in all the patients, in the course of the first or a later session. The Authors suggest that this behaviour of the Ny may be related to a different collocation of the otoconial mass inside the LSC. In fact, if one considers division of the LSC into two halves, the simple or posterior segment and the ampullary or anterior segment, it is not difficult to imagine the different ways the otolithic

terale, superando il rigido schematismo delle manovre proposte sino ad oggi in letteratura, consente di adattare "step by step" il programma riabilitativo al singolo caso, così da permettere, attraverso una terapia individualizzata, il raggiungimento della risoluzione già dalla prima seduta riabilitativa.

mass moves in its gravitational sedimentation in the lateral position, according to the canal segment it is in. Lying on the impaired side causes detritus in the ampullary segment to move away from the cupula, resulting in an inhibitory ampullofugal endolymphatic current, leading to apogeotropic PPNy, directed towards the unstimulated ear. Turning the head to the opposite side causes the particles to fall towards the ampulla, with an excitatory discharge, and a PPNy directed towards the pathological side, therefore, once again, apogeotropic. The transformation of the Ny from apogeotropic to geotropic is explained by the migration of the otoconial mass in the posterior segment of the LSC, with a consequent inversion of direction, with respect to the cupula, in the movement of the detritus, induced by gravitational pull with the lateral rotations of the head. The PPNy of greatest intensity in the apogeotropic variant is observed in the supine position on the uninvolved side, and this is in keeping with the second law of Ewald, in that excitatory stimulation from an ampullopetal endolymphatic current occurs when the diseased ear is uppermost.

In 1996, Nuti et al.⁵ reported findings in a study on 123 patients suffering from BPPV of the LSC, from which they extrapolated 5 typical cases to illustrate possible clinical variants of the syndrome, examining the semeiotic aspects of the nystagmi observed and proposing a physiopathological explanation for these in view of the canalolithiasis theory.

Patients and Methods

Cases related to 2001 are herewith reported: 55 of BPPV due to canalolithiasis of the LSC were treated, 40 geotropic and 15 apogeotropic forms.

The rehabilitation techniques used were, in the geotropic forms (Fig. 1), the Vannucchi-Asprella manoeuvre (Fig. 2) and the Lempert (Fig. 3); in the apogeotropic forms (Fig. 4). The Gufoni technique (Fig. 5) was also used in several cases.

The therapeutic approach was tailored to suit the needs of the individual patient's physical condition: arthrosis, obesity, recent injuries, plaster casts, multiple neurovegetative disorders.

The rehabilitation manoeuvres were always carried out while monitoring the nystagmus under videonystagmoscopic control, in order to monitor the progression of the otolithic mass away from the ampulla, which was confirmed by the appearance of a nystag-

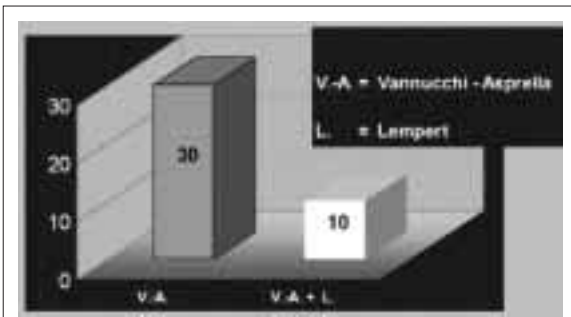


Fig. 1. Geotropic forms: liberatory manoeuvres carried out.

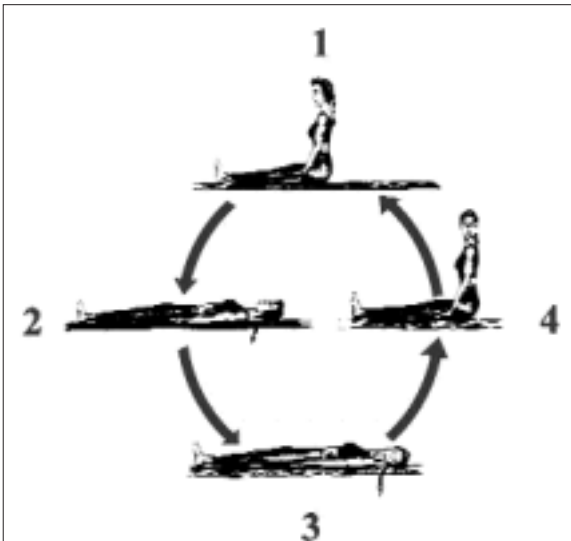


Fig. 2. Vannucchi-Asprella liberatory manoeuvre for BP-PV of right LSC: 1. patient is brought from seated to supine position, with head straight; 2. head is briskly turned 90° towards healthy side; 3. patient is brought back to sitting position, keeping head to side, then slowly turns it forward. This sequence is repeated for a minimum of 5 times.

mus directed towards the healthy side (and, therefore, inhibitory, due to the ampullofugal deflection of the ampullary cupula) during execution of the single steps of therapy.

Results

Of the 40 geotropic forms (Fig. 1), 30 were successfully treated with the Vannucchi-Asprella technique at the first session. The manoeuvre was repeated until the horizontal nystagmus directed towards the healthy side disappeared when changing from a sit-

ting to a supine position, and immediately after the sudden latero-rotation of the head towards the healthy side, with the patient lying supine. This finding was interpreted as indicative of a likely resolution of the problem. In 16 cases, this occurred after the first 3-4 manoeuvres (although, as a precautionary measure, a minimum of 5 manoeuvres were always carried out); in 6 other cases, this occurred after 5-6 manoeuvres, while 8-10 manoeuvres were required in the remaining 8 patients (Table I).

In 10 cases (Table I), after the disappearance of the horizontal nystagmus towards the healthy side, occurring, on average, after 3-4 manoeuvres, a horizontal nystagmus appeared, directed towards the pathological side, when returning to a seated, position. This finding was interpreted as indicative of an ampullopetal reflux of the otoconial mass, brought closer by the rotatory steps to the utricular orifice, without, however, passing through it. It was, therefore, decided to continue with a further 90° lateral rotation of the head with the patient supine on the healthy side, with a Lempert barbecue rotation technique (Fig. 3). The reappearance of a horizontal nystagmus directed towards the healthy side while this technique was being carried out, was taken as indicative of an ampullofugal progression of the otoliths. Verification with a diagnostic manoeuvre, at the end of the session confirmed that the problem had been solved.

In the apogeotropic forms (Fig. 4), transformation into a geotropic form was attempted in 8 cases with the Vannucchi-Asprella manoeuvre towards the healthy side. In 6 of these cases, a nystagmus directed towards the healthy side (and, therefore, geotropic) was detected after a sudden homolateral latero-rotation of the head in the supine position, indicative of a

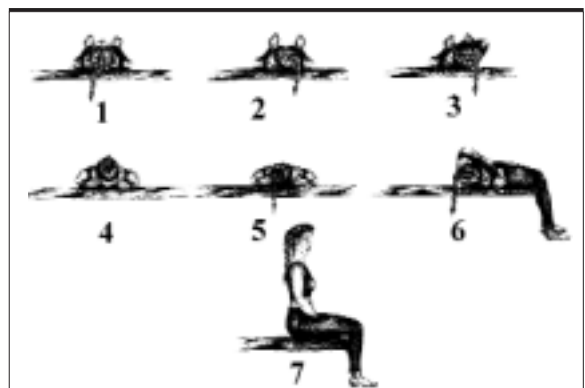


Fig. 3. Lempert's liberatory manoeuvre for BPPV of right LSC: starting from supine position with head straight, 3 sudden 90° rotations of head towards healthy side are imparted, rolling patient over each time and finally returning him/her to seated position.

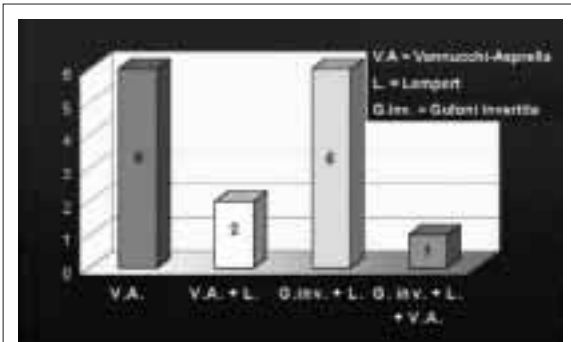


Fig. 4. Apogeotropic forms: liberatory manoeuvres carried out.

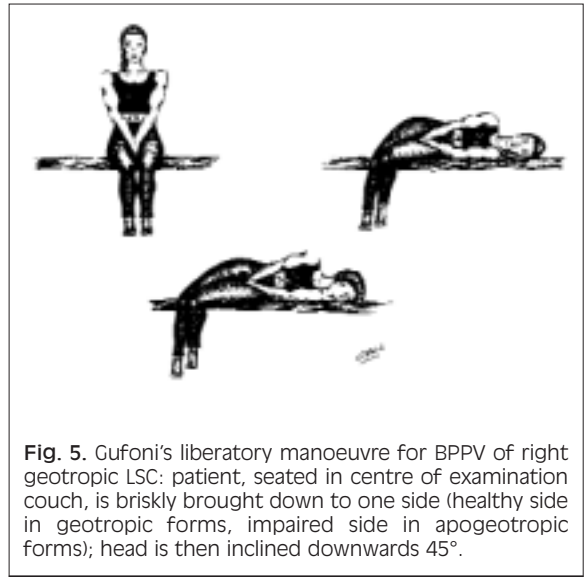


Fig. 5. Gufoni's liberatory manoeuvre for BPPV of right geotropic LSC: patient, seated in centre of examination couch, is briskly brought down to one side (healthy side in geotropic forms, impaired side in apogeotropic forms); head is then inclined downwards 45°.

probable transformation from apogeotropic to geotropic. In these 6 patients, the Vannucchi-Asprella technique was repeated 5 more times with disappearance of the nystagmus in the passage from seated to supine, and after latero-rotation of the head, and consequently, eliminating the problem, later confirmed during the diagnostic manoeuvre. In the other 2 patients, whose geotropic nystagmus persisted after the Vannucchi-Asprella manoeuvre had been carried out 10 times, treatment continued from the step with a 90° latero-rotated position of the head towards the healthy side with the Lempert technique, achieving resolution in this way (Table I).

In 7 other cases of apogeotropic BPPV of the LSC, after failure of the other techniques, transformation was attempted with the inverted Gufoni manoeuvre (Fig. 5): the patient, in a seated position, was rapidly turned onto the pathological side. In all 7 patients, we observed an apogeotropic horizontal nystagmus, indicating an ampullofugal progression of the otolith mass. It was decided to continue by swinging the patient's legs onto the examination couch, with a Lem-

pert barbecue rotation technique. In 6 patients, at every 90° step, we observed a nystagmus directed towards the healthy side, indicating a further progression of the otoconial aggregate in an ampullofugal direction. Verification with the Pagnini diagnostic manoeuvre confirmed that treatment had been successful. One of these 7 patients, with an initially apogeotropic form, when returning to the pathological side (last step of the Lempert technique) suddenly presented a violent nystagmus towards the side involved, and, therefore, geotropic, indicating that a transformation from apogeotropic in geotropic had occurred, but not a solution of the problem. This was later achieved by carrying out the Vannucchi-Asprella technique 8 times (Table. I).

In all 55 patients, therapeutic success was achieved during the first treatment session.

Table I. Geotropic and apogeotropic forms: number and type of manoeuvres carried out to achieve resolution of problem. V.A.: Vannucchi-Asprella manoeuvre; inv. G.: inverted Gufoni manoeuvre; L.: Lempert manoeuvre.

Geotropic forms	Apogeotropic forms
16 cases: solution after 3-4 V.A. manoeuvres	6 cases: solution after 5-6 V.A. manoeuvres
6 cases: solution after 5-6 V.A. manoeuvres	2 cases: solution with L. after transformation in geotropic with V.A.
8 cases: solution after 8-10 V.A. manoeuvres	6 cases: solution with inv. G. followed by L.
10 cases: solution after 3-4 V.A. manoeuvres followed by L. manoeuvre	1 case: solved with 8 V.A. manoeuvres after transformation in geotropic with inv. G. + L.

Discussion

Over the last few years, there has been a proliferation of therapeutic proposals regarding the treatment of BPPV of the LSC.

After early attempts at mobilisation of the otolithic mass with head shaking in the supine position⁶, showing unsatisfactory results, other Authors⁷⁻⁹, over the next few years, suggested rehabilitation techniques, defined as “barbecue rotation”. The latter are based on the principle of exerting an ampullofugal impetus to the otolithic mass in the canal by having the supine patient carry out rapid head rotations towards the healthy side, in single 90° steps, in order to exploit the inertial lag of the otoconia, free to float in the canal endolymph. The overall angle of rotation varied from 180° to 360°. In 1994, Vannucchi et al.¹⁰ proposed an innovative treatment technique for BPPV of the LSC. Convinced that the pathogenic mechanism was engendered by canalolithiasis, the Authors set up a procedure based on slow gravitational sedimentation of the otolithic particles outside the non-ampullary segment of the LSC. The method, which is simple and applicable in any patient, consists in forced immobility on the healthy side for at least 12 hours, in order to maintain the simple segment of the LSC in a vertical position, with the non-ampullary aperture facing downwards; verification is effected after 72 hours. The Authors using the newly proposed technique in 13 patients, reported a cure rate of BPPV of the LSC in 93% of cases.

In 1995¹¹, Epley proposed a technique of canaloliths repositioning for BPPV of the LSC, without, however, supplying a study documenting his results.

In 1995¹², Fife reported findings in four patients suffering from BPPV of the LSC, unsuccessfully treated with the Baloh manoeuvre.

In 1997, Vannucchi et al.¹³ verified the efficacy of the therapeutic technique entailing a forced liberatory position lying on the healthy side (FLP), comparing the results obtained in three groups of patients: 1) 35 treated with FLP; 2) 24 treated with head shaking in a supine position; 3) 15 in whom no therapy was effected. In the first group, the Authors reported a solution of BPPV of the LSC, in 72 hours, in over 90% of the cases, vs 17% in the second group and 26% in the untreated patients; furthermore, they reported a statistical significance in the therapeutic results of FLP.

In 1998, Gufoni¹⁴ proposed a new technique: starting from a seated position with the patient's legs dangling from the side of the examination couch, the patient is asked to lie down rapidly on one side (on the healthy side in the geotropic form, on the pathological side in the apogeotropic form); the head is then turned downwards by 45°, waiting 2-3 minutes; finally, the patient is returned to the starting position.

The results described in a later report show a 90% cure rate in these cases.

In the same year, Vannucchi and Asprella¹⁴ proposed a variant of the barbecue rotation manoeuvre: from a supine position, the patient rapidly turns his/her head 90° towards the healthy side; then, while keeping the head turned, he/she returns to a seated position and brings the head back in axis with the body; and, finally, he/she returns to the supine position. This sequence is repeated at least 5 times. The following year, Asprella, Libonati and Gufoni¹⁶ reported that 3 cases out of 4 treated with this method were successfully solved. Using the same technique, Galletti et al.¹⁵ reported a 100% cure rate in a study on 10 patients (8 geotropic and 2 apogeotropic forms). In 1999, Asprella et al.¹⁶ proposed a mixed liberatory technique in which three rapid positionings were followed by a brief forced recumbent position.

In that same year, Mosca¹⁷ published a personal therapeutic approach, outlining a variant for the apogeotropic forms and reporting success in 83% of cases.

A review of the literature, therefore, reveals a considerable variety of rehabilitation manoeuvres, each theoretically valid, aimed at achieving the ampullofugal endocanal progression ampullofugal of the otoconial detritus, at times with angular accelerations (barbecue rotation techniques), at times with sudden linear accelerations (Gufoni and Mosca liberatory techniques), at times through slow gravitational sedimentation (Vannucchi FLP), or, even, with combined methods (Asprella liberatory manoeuvre). None of the techniques proposed, so far, have, however, led to a complete solution, in every case, at the first session, particularly as far as concerns the apogeotropic forms.

Despite the wide range of treatment techniques available, we prefer manoeuvres that are both well tolerated by the patient and effect a prompt solution. Indeed, for the geotropic forms, we usually prefer barbecue rotation techniques as proposed by Vannucchi-Asprella and Lempert. For apogeotropic forms, transformation into geotropic was achieved in some cases, using the Vannucchi-Asprella manoeuvre towards the healthy side. The line of conduct was chosen in order to apply sudden, repeated angular accelerations to the lateral semicircular canal involved and its content (endolymphatic column and otolithic mass). Due to the inertial lag of the otoliths, the specific weight of which is greater than that of the endolymph, a gradual progression of the former in the opposite direction from the rotation imparted to the head with the liberatory manoeuvre is thus obtained, exactly in the same way as in the geotropic forms, the only difference being a different point of endocanal departure of the otoconia (from the ampullary segment in the apogeotropic forms, from the non-am-

pullary segment in the geotropic forms). In other words, in turning the head, and, therefore, the LSC, clockwise, the otoconial detritus proceeds in a counterclockwise direction, and vice versa.

This explains the sudden cure in some of the apogeotropic forms (6 cases) after repeating the Vannucchi-Asprella manoeuvre, towards the healthy side, several times. In the other initially apogeotropic forms, it was necessary to combine the different liberatory techniques in various ways (Vannucchi-Asprella + Lempert; inverted Gufoni + Lempert) in order to reach a complete solution in the first session, by means of VNS monitoring of the ampullofugal progression of the otoconial mass.

On the grounds of our experience, we, therefore, propose that, on the basis of our knowledge of the different rehabilitation techniques, the choice should be

made bearing in mind the “physical” needs of the patient; albeit, we also stress the importance of checking, during therapy, the effective ampullofugal progression of the otolithic mass by means of VNS monitoring of the nystagmus evoked, using the well-known laws of Ewald in the interpretation.

Conclusions

VNS monitoring of the nystagmus during treatment for BPPV due to canalolithiasis of the LSC, in overcoming the rigid schematism of the manoeuvres previously proposed in the literature, allows the rehabilitation programme to be adapted step by step to the individual case, thus leading always to a complete solution during the first treatment session.

References

- 1 Cipparrone L, Corridi G, Pagnini P. *Cupulolithiasi*. In: *Giornata Italiana di Nistagmografia Clinica. Nistagmografia e patologia vestibolare periferica*. Milano: C.S.S. Boots-Formenti; 1985. p. 36-53.
- 2 Pagnini P, Nuti D, Vannucchi P. *Benign paroxysmal vertigo of the horizontal canal*. *ORL J Otorhinolaryngol Relat Spec* 1989;51:161-70.
- 3 Ewald R. *Physiologische Untersuchungen über das Endorgan des Nervous Octavus*. Weisbaden: Bergmann; 1892.
- 4 Pagnini P, Vannucchi P, Nuti D. *Le nystagmus apogeotropique dans la vertige paroxystique positionnelle benign du canal semicirculaire horizontal*. *La Revue d'Otoneurologie Française* 1994;12:304-7.
- 5 Nuti D, Vannucchi P, Pagnini P. *Benign paroxysmal positional vertigo of the horizontal canal: a form of canalolithiasis with variable clinical features*. *J Vestib Res* 1996;6:173-84.
- 6 Vannucchi P, Giannoni B, Nuti D. *La cupulolithiasi del canale semicircolare orizzontale: aspetti clinici*. In: *XII Giornata Italiana di Nistagmografia Clinica. La cupulolithiasi*. Milano: C.S.S Formenti; 1992. p. 81-91.
- 7 Baloh RW, Jacobson K, Honrubia V. *Horizontal semicircular canal variant of benign positional vertigo*. *Neurology* 1993;43:2542-9.
- 8 Lempert T. *Horizontal benign positional vertigo*. *Neurology [Letter]* 1994;44:2213-4.
- 9 Baloh RW. *Horizontal benign positional vertigo*. *Neurology [Reply]* 1994;44:2213-4.
- 10 Vannucchi P, Giannoni B, Giuffreda P, Paradiso P, Pagnini P. *The therapy of benign paroxysmal positional vertigo of the horizontal semicircular canal*. In: Versino M, Zambambieri D, editor. *International Workshop on Eye Movements*. Pavia: Fondazione IRCCS; 1994. p. 321-4.
- 11 Epley JM. *Positional vertigo related to semicircular canalolithiasis*. *Otolaryngol Head Neck Surg* 1995;112:154-61.
- 12 Fife TD. *Horizontal canal benign positional vertigo. Advancing the science of vestibular diagnostics*. ENG Report. Schaumburg: ed. ICS Medical; 1995. p. 1-4.
- 13 Vannucchi P, Giannoni B, Pagnini P. *Treatment of horizontal semicircular canal benign paroxysmal positional vertigo*. *J Vestib Res* 1997;7:1-6.
- 14 Vannucchi P, Giannoni B. *La terapia della vertigine posizionale del canale semicircolare laterale. Tecniche a confronto*. In: *VII Giornata di Vestibologia Pratica*. Milano: C.S.S Formenti; 1998. p. 61-73.
- 15 Galletti F, Freni F, Leo L. *Terapia della VPPB da litiasi del canale semicircolare orizzontale*. In: *XVIII Giornate Italiane di Otoneurologia. Aspetti diagnostici riabilitativi della patologia vestibolare: stato dell'arte*. Milano: Grunenthal-Formenti; 2001. p. 163-72.
- 16 Asprella Libonati G, Gufoni M. *Vertigine parossistica da CSL: manovre di barbecue ed altre varianti*. In: *XVI Giornate Italiane di Otoneurologia. Revisione critica di venti anni di vertigine parossistica posizionale benigna (VPPB)*. Milano: C.S.S Formenti; 1999. p. 321-36.
- 17 Mosca F. *La vertigine parossistica da canale laterale. Proposta di un metodo di trattamento*. *Acta Otorhinolaryngol Ital* 1999;1:144-9.

■ Received April 15, 2002.
Accepted August 2, 2002.

■ Address for correspondence: Dr. G. Asprella Libonati, Unità Operativa di Otorinolaringoiatria e Chirurgia Cervico-Facciale, Presidio Ospedaliero, 75100 Matera, Italy. Fax: +39 0835 243381. E-mail: asprella@tin.it