

CASE REPORT

Effects of laryngeal tuberculosis on vocal fold functions: case report

Gli effetti della tubercolosi laringea sulla funzionalità vocale: caso clinico

E. ÖZÜDOGRU, H. ÇAKLI, E.E. ALTUNTAS¹, M.K. GÜRBÜZ
 Osmangazi University Medical Faculty, Department of Otorhinolaryngology Eskişehir;
¹ Department of Otorhinolaryngology, Tokat General Hospital, Tokat, Turkey

Key words

Larynx • Laryngeal tuberculosis • Voice quality

Parole chiave

Laringe • Tubercolosi laringea • Qualità vocale

Summary

Laryngeal tuberculosis is the most common granulomatous disease of the larynx. In this study, the videostroboscopic findings and vocal assessments of a 28-year-old female with laryngeal and pulmonary tuberculosis were evaluated. Although it can be treated successfully, tuberculosis of the larynx may cause irreversible changes in voice quality which is very important for vocal professionals.

Riassunto

La tubercolosi laringea è la più comune fra le malattie granulomatose della laringe. In questo studio, i risultati videostroboscopici e la qualità della voce di una donna di 28 anni con tubercolosi polmonare e laringea sono stati valutati prima, durante e dopo il trattamento. È stato osservato che anche se il trattamento ha successo, la tubercolosi laringea determina cambiamenti irreversibili della qualità della voce, con conseguenze significative soprattutto per i professionisti vocali.

Introduction

Laryngeal tuberculosis (LT) is the most common granulomatous disease of the larynx and has usually been considered to result from pulmonary tuberculosis (PT), although it might be localized in the larynx as a primary lesion without any pulmonary involvement¹⁻⁵. LT may cause hoarseness, dysphagia and odynophagia⁶⁻⁸. The granulomatous lesions of LT may involve all parts of the larynx due to haematogenic and lymphatic spreading of the mycobacteria^{1,9}. The diagnosis of LT may be difficult on account of the non-pathognomonic complaints and physical findings, especially in those patients without pulmonary disease. Moreover, the change in manifestations of tuberculosis, in patients with human immune deficiency virus (HIV) infection, may make LT more difficult to diagnose¹⁰.

The infection begins with exudation in the subepithelial space followed by round cell infiltration and heals with fibrosis in LT¹¹. Fibrotic changes in the layers of the lamina propria of the vocal folds may negatively affect the vibrations and cause irreversible changes in the quality of the voice.

Aim of the present study was to investigate the permanent effects of LT on vocal fold vibratory functions and voice quality.

Case report

A 28-year-old female presented with a 3-month history of sore throat, dysphagia, hoarseness, weight loss and right earache. No tumoural lesions involving the right arytenoid, right pyriform sinus and interarytenoid region were detected at fiberoptic laryngoscopic examination. The right true and false cords were oedematous, movements of the vocal cords were normal, non-linear free edge and loss of vibration were found in the right true vocal cord at videostroboscopy. The glottic closure was incomplete during phonation. Laboratory tests were in agreement with iron deficiency anaemia, the plain chest X-ray and computed tomography (CT) showed bilateral lesions in the upper zones. The bacteriologic examination of the sputum was positive for acid-fast bacteria. Laryngeal biopsy tissue was collected to exclude the co-existence of PT and hypopharyngeal carcinoma. Histopathological examinations of the biopsy specimen revealed a chronic inflammatory process. Anti-tuberculous treatment, consisting of isoniazid, rifampisin, ethambutol and mefazid, was started and maintained for 9 months. Videostroboscopic examinations were performed with a Karl Storz 8020 videostroboscope unit (Tuttligen, Germany) before, during and after treatment. The find-

ings emerging from these examinations are outlined in Table I.

Videostroboscopic views of the larynx are illustrated in Figures 1 and 2.

The vocal assessment programme of Dr. Speech Software (Tiger DRS Inc. Seattle, WA, USA) was used for computer-assisted voice quality estimations. In this programme, the hoarseness, harshness and breathiness of the voice have been classified from 0 [normal] to 3 [worst]. The findings of voice quality characteristics are listed in Table II.

Comment

The effective use of isolation and the advances of antituberculous chemotherapy have led to a decrease in the incidence of tuberculosis. Albeit, the presence of Acquired Immuno Deficiency Syndrome (AIDS) or other immunosuppressive diseases and long-term use of corticosteroid drugs may result in the increased incidence of tuberculosis^{5,9}. The most common sites of LT in the larynx are, respectively, the interarytenoid region, the arytenoid cartilages, the posterior surface

Table I. Videostroboscopic findings of patient during follow-up period.

Videostroboscopic findings	Before treatment	2 nd month of treatment	6 th month of treatment	8 th month of treatment	After treatment
Fundamental frequency (F ₀)	199 Hz	211 Hz	266 Hz	205 Hz	245 Hz
Glottal closure	Irregular shape	Irregular shape	Spindle shape gap	Spindle shape gap	Spindle shape gap
Free edges of vocal folds	Right	Non-linear	Non-linear	Linear	Linear
	Left	Linear	Linear	Linear	Linear
Vibration	Right	Absent	Absent	Minimal	Minimal
	Left	Present	Present	Present	Present
Amplitude of horizontal (lateromedial) excursions	Right	Zero	Zero	Smaller than left	Smaller than left
	Left	Normal	Normal	Normal	Normal
	Right	Absent	Absent	Absent	Smaller than left
Mucosal wave	Left	Normal	Normal	Normal	Normal
Supraglottic vibration	Absent	Absent	Absent	Absent	Absent
Epiglottic oedema	Present	Absent	Absent	Absent	Absent
Oedema of arytenoid region	Present	Decreased	Markedly decreased	Absent	Absent
Interarytenoid involvement	Present	Decreased	Markedly decreased	Absent	Absent

Table II. Findings of voice quality characteristics of patient in follow-up period.

Voice quality characteristics	Before treatment	2 nd month of treatment	6 th month of treatment	8 th month of treatment	After treatment
Jitter%	0.2	0.2	0.3	0.6	0.5
Shimmer%	2.9	3.1	3.4	5.2	4.1
SD F ₀ (Hz)	4	3.9	3.7	3.1	2.8
NNE (dB)	- 9.3	- 9.4	- 9.1	- 8.4	- 4.7
Hoarse voice	+ 3	+ 2	+ 2	+ 2	+ 1
Harsh voice	+ 1	+ 1	+ 1	+ 2	0
Breathy voice	+ 2	+ 2	+ 2	+ 3	+ 3

SD F₀: Standard deviation of fundamental frequency. NNE: Normalized noise energy.

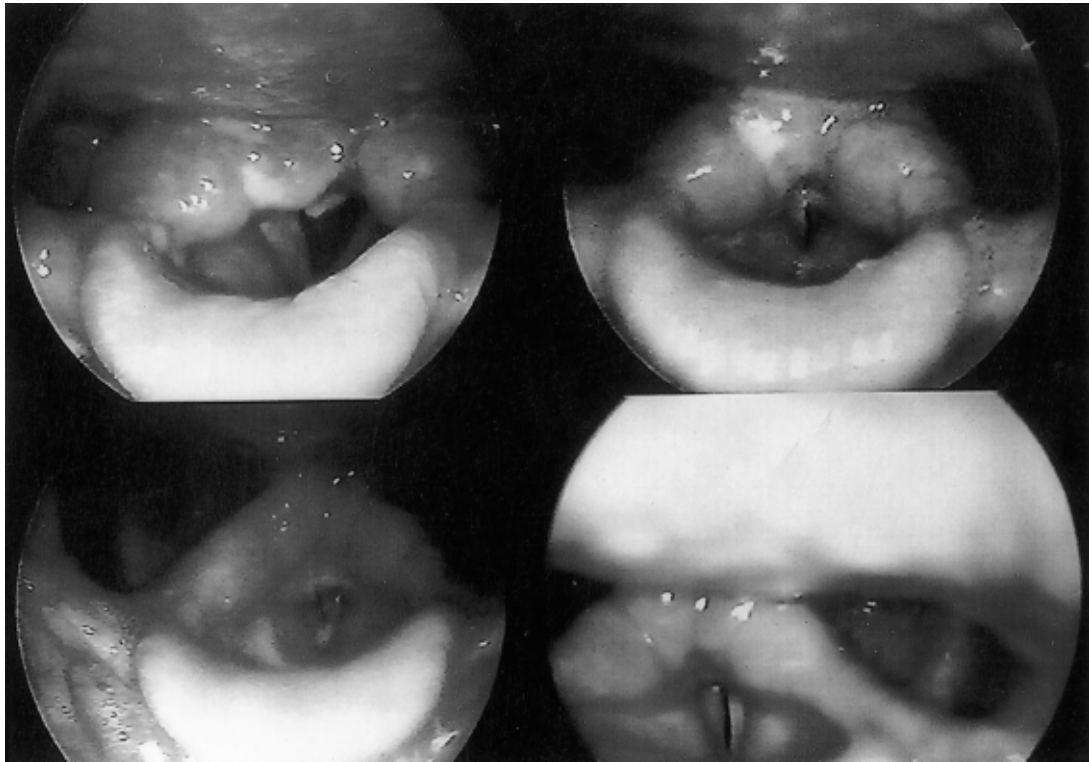


Fig. 1. Videostroboscopic views: a. and b. Before treatment (at top), c. the 2nd month of treatment (lower left), d. 6th month of treatment (lower right).

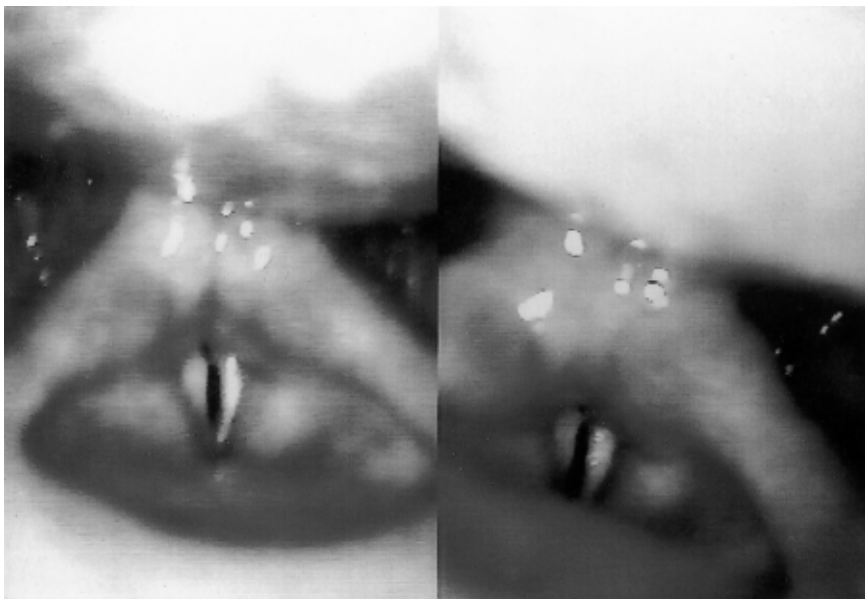

Fig. 2. Videostroboscopic views: a. 8th month of treatment (left), b. 2 months after treatment (right).

of the true vocal cords and the laryngeal surface of the epiglottis^{8,12}. The case described here presented with lesions on the right arytenoid, right sinus pyriformis and interarytenoid region. The right true vocal cord had an oedematous and erythematous appearance. According to Hirano¹³, the greater mass of the vocal fold causes the smaller Fo and LT increases the mass of vocal folds. Fo was 199 Hz before treatment, increasing to 245 Hz during the post-treatment period, in our case.

Glottal closure is one of the important events affecting voice quality. During phonation, as the subglottal pressure increases against the closed glottis, the vocal cords, bilaterally, are blown apart and the glottis opens. After maximal opening, the subglottal pressure starts to drop and the vocal cords move medially to close the glottis¹³. These consecutive opening and closing phases create the vibratory cycle. Sliding movements of the pliable mucosa cover (epithelial and superficial lamina propria), the rather stiff body (vocalis muscle), are essential for vibrations¹³. LT starting in the sub-epithelial space and healing with fibrosis negatively affects this sliding movement of the vocal folds and lessens the amplitude of latero-medial excursions during phonation. Thus the vibration loss prevents complete glottal closure. Glottal closure presented an irregular shape for two months of treatment due to the non-linear free edge and increased mass of involved vocal cord, in our case. Later, it became spindle-shaped along the entire length

of the glottis and maintained this position also in the post-treatment period. At the end of treatment, minimal increasing occurred in the amplitude of horizontal excursions of the involved cord but was not adequate for complete glottal closing.

The mucosal wave travelling laterally on the surface of the vocal fold at, and after, maximum opening of the vibratory cyclus is an important feature of vibration. Normally, it crosses at least half of the entire width of the visible part of the vocal cord during normal pitch and loudness¹³. The mucosal wave was absent, in the post-treatment period, in our case.

In the computer-assisted voice quality evaluation, the harshness disappeared and the hoarseness decreased to 1 degree after treatment. These changes resulted from disappearance of the oedema of the involved cord and the tumoural masses, on the other parts of the larynx, and these produced a marked subjective improvement in voice quality. Albeit, breathiness became worse on account of a continuous glottic gap along the vibratory cyclus.

Conclusion

Although it can be treated successfully, tuberculosis of the larynx may cause irreversible fibrotic changes in the lamina propria of the vocal fold involved and may cause a permanent breathy voice. This condition is very important in vocal professionals.

References

- 1 Shin JE, Nam SY, Yoo SJ, Kim SY. *Changing trends in clinical manifestations of laryngeal tuberculosis*. Laryngoscope 2000;110:1950-3.
- 2 Thaller SR, Gross JR, Pilch BZ, Goodman ML. *Laryngeal tuberculosis as manifested in the decades 1963-1983*. Laryngoscope 1987;97:848-50.
- 3 Kruschinski C, Welkoborsky HJ. *Tuberculosis of the larynx associated with orofacial granulomatosis in childhood*. Otolaryngol Head Neck Surg 2005;132:967-9.
- 4 Richter B, Fradis M, Kohler G, Ridder GJ. *Epiglottic tuberculosis: differential diagnosis and treatment. Case report and review of the literature*. Ann Otol Rhinol Laryngol 2001;110:197-201.
- 5 Egeli E, Oghan F, Alper M, Harputluoglu U, Bulut I. *Epiglottic tuberculosis in patient treated with steroids for Addison's disease*. Tohoku J Exp Med 2003;201:119-25.
- 6 Krecicki T, Krecicka MZ, Zatoski T, Jankowska R, Skrzydlewska KA, Kaczmarek BS. *Laryngeal tuberculosis*. Lancet Infect Dis 2004;4:57.
- 7 Levenson MJ, Ingerman M, Grimes C, Robbett WF. *Laryngeal tuberculosis: review of twenty cases*. Laryngoscope 1984;94:1094-7.
- 8 Agarwal P, Bais AS. *A clinical and videostroboscopic evaluation of laryngeal tuberculosis*. J Laryngol Otol 1998;112:45-8.
- 9 Soda A, Rubio H, Salazar M, Ganem J, Berlanga D, Sanchez A. *Tuberculosis of the larynx: clinical aspects in 119 patients*. Laryngoscope 1989;99:1147-50.
- 10 Singh B, Balwally AN, Nash M, Har-El G, Lucente FE. *Laryngeal tuberculosis in HIV infected patients: a difficult diagnosis*. Laryngoscope 1996;106:1238-40.
- 11 Broek PV. *Acute and chronic laryngitis*. In: Kerr AG, editor. *Scott Brown's Otolaryngology. Sixth edn*. Oxford: Butterworth-Heinemann Reed Educational and Professional Publishing Ltd; 1997. p. 1-20.
- 12 Rutter MJ, Cotton RT. *Laryngeal Stenosis*. In: Bailey BJ, Calhoun RT, editors. *Head and Neck Surgery Otolaryngology. Third edn*. Philadelphia: Lippincott Williams and Wilkins Co; 2001. p. 881-93.
- 13 Hirano M, Bless DM. *Videostroboscopic examination of the larynx. First edn*. California: San Diego Singular Publishing Group Inc; 1993.

■ Received: February 16, 2005
Accepted: September 16, 2005

■ Address for correspondence: Dr. E. Özüdoğru, Osmangazi Üniversitesi Tıp Fakültesi Kulak Burun Boğaz AD, 26480, Eskişehir, Turkey. Fax +90 222 2393774. E-mail: hcakli@ogu.edu.tr.