

Predictive factors of neck metastases in laryngeal squamous cell carcinoma. Towards an integrated clinico-molecular classification

Fattori predittivi di metastatizzazione linfonodale nei carcinomi squamocellulari nella laringe: verso una classificazione integrata clinico-molecolare

G. ALMADORI, F. BUSSU, G. PALUDETTI

Institute of Otolaryngology, Sacred Heart Catholic University, Rome, Italy

Key words

Laryngeal carcinoma • Neck metastases • Molecular markers

Parole chiave

Carcinoma laringeo • Metastasi linfonodali • marcatori molecolari

Summary

Our group has 25 years' experience in the use of molecular predictive markers in head and neck cancer, on a large patient population, enrolled from a single institution, with a long follow-up, and, most of all, homogeneous regarding histology (squamous cell carcinoma) and site (larynx). Among the most frequent malignancies in the US, cancers of the larynx and uterine corpus are the only types not showing an increase in 5-year Survival Rates over the last 30 years. As far as concerns laryngeal squamous cell carcinoma, we can identify several potential reasons for this failure, the most relevant probably lies in the neck. For this reason, a key issue in laryngeal oncology is to assess metastatic potential of squamous cell carcinoma at diagnosis. Nevertheless, the combination of clinical and histological parameters is not sufficiently reliable in the prediction of lymph node metastases. Molecular characterization, by the study of molecular predictive factors, is a clinical approach aimed to define homogeneous subgroups for clinical metastatic behaviour. Defining invasiveness by means of studies on selected molecular markers (among which the most reliable is probably Epidermal Growth Factor Receptor (EGFR)) may be useful in the choice of the most appropriate treatment on both T and on N.

Riassunto

Viene discussa l'esperienza monocentrica dell'uso di fattori predittivi molecolari su una casistica numerosa ed omogenea di pazienti con carcinomi laringei. Questi carcinomi non hanno avuto un miglioramento prognostico significativo negli ultimi trent'anni. La causa è verosimilmente riferibile alle ricadute sul collo. Per questo risulta indispensabile caratterizzare la aggressività biologica della neoplasia integrando informazioni desunte dallo studio di marcatori predittivi clinici e molecolari. Fra questi il più affidabile è probabilmente il fattore EGFR.

25 years' experience

Our group has 25 years' experience in the use of molecular predictive markers in head and neck cancer, on a large patient population, enrolled from a single institution, with a long follow-up, and, most of all, homogeneous regarding histology (squamous cell carcinoma – SCC) and site (larynx)¹⁻¹¹.

In our opinion, this may be a definite advantage, avoiding the bias derived from collecting together all head and neck SCCs. In fact, although the larynx is considered a site of the head and neck, several peculiarities, of both a clinical and a molecular nature, can

be highlighted. The statistics of the American Cancer Society classify larynx as part of the respiratory system, separately from the oral cavity and pharynx¹². As for the incidence, the male/female ratio is markedly higher than in the other sites of the head and neck¹². Differences in chromosomal pattern and carcinogenic progression between laryngeal squamous cell carcinoma (LSCC) and the other head and neck squamous cell carcinomas (HNSCCs) have been detected by comparative genomic studies¹³. In particular, p53 is normally expressed in LSCC more frequently and p53 gene has a mutation pattern more closely resembling lung SCCs than other HNSCCs¹⁴.

Improving survival in LSCC: a missed target

LSCCs represent the vast majority (approximately 96%) of laryngeal malignancies¹⁵. Other histologic types have not been taken into consideration in the present report.

Of the most frequent malignancies in the US, cancers of the larynx and the uterine corpus are the only types not presenting an increase in the Five-year Survival Rates during the last 30 years¹². As for LSCC, we can identify several potential reasons for this failure, probably the most relevant lying in the neck:

- TNM classification appears, in some cases, inadequate. For example, it has been observed that regrouping cases in stages III and IV into locally advanced disease *vs.* regional metastasis appears to predict survival better¹⁵. In fact, neck metastasis remains the first cause of treatment failure and death in LSCC¹⁶. Thus, in our opinion, the treatment of the neck should be the primary concern of every head and neck oncologist;
- despite the multiplicity of clinical prognostic factors, the only consistent clinical predictors for disease control and disease-specific survival in LSCC are T and, to a greater extent, N¹⁷⁻¹⁹. The prognostic stratification of LSCC patients is inadequate since similar patients, affected by tumours with similar clinico-pathological parameters, and undergoing the same treatment, may differ considerably in prognosis. This is probably due to the extreme biological heterogeneity of LSCCs and contributes to a lack of consistency in treatment planning²⁰;
- an example of this lack of consistency is the management of cervical lymph nodes, which is the most important component of the overall treatment strategy, especially for supraglottic tumours. Surgery remains the mainstay of neck treatment since it provides comprehensive clearance of all grossly enlarged lymph nodes and allows accurate histological information to be obtained also concerning micrometastases in the clinically negative neck. Nevertheless, while the indications for comprehensive surgical clearance of the neck, for clinically palpable metastatic lymph nodes (cN+), are obvious, the indications for elective selective treatment of cN0 neck appear less clear^{19 21-23}.

Clinical predictive markers of neck node metastases

For the above-mentioned reasons, a key issue in head and neck, and laryngeal oncology in particular, is to assess the metastatic potential of SCCs at diagnosis.

Differences in the natural histories of the various SCCs of the larynx, as for neck metastasis, are related, according to our present knowledge, to the anatomy and to the lymphatic drainage patterns of the respective subsite(s).

The paucity of lymphatic drainage of the true vocal cords, in all areas other than the posterior commissure, makes metastasis of early lesions extremely unlikely. As for the rare primitive subglottic cancers, the incidence of cervical metastasis, in this group of cancers, is reported to be 20-30%, but that figure is somewhat obscured by the fact that the primary drainage pattern of these lesions is to the less detectable pre-tracheal and para-tracheal nodes. The incidence of metastasis may, therefore, be significantly higher^{24 25}.

Albeit, neck node metastasis is mainly a 'supraglottic issue'. In fact, because of the profuse lymphatic network of the supraglottic larynx, carcinomas of this area metastasize frequently to the cervical lymph nodes, and failure of treatment is usually a result of metastasis rather than local disease²⁶⁻²⁸. The incidence of patients with clinically positive lymph nodes at the time of diagnosis is 23-50% for all supraglottic sites and stages combined²⁹⁻³². A substantial number of those patients with clinically negative necks are found to have histologic disease, as demonstrated when neck dissection is performed, or, if left untreated, they convert to clinically positive necks^{33 34}. In supra-glottic cancers, the probability of cervical metastasis and the probability of delayed contralateral metastasis increase in direct proportion to the size of the primary lesion (i.e., the T stage)³⁵⁻³⁷. Lindberg²⁶ reported impressive overall metastatic rates with various supraglottic carcinomas: 63% of T1, 70% of T2, 79% of T3, and 73% of T4 cases metastasized.

In patients with supraglottic lesions presenting with a clinically positive cervical node 2 cm in diameter or more, the possibility for contralateral neck metastasis is 40% or higher²⁴. The epiglottis is particularly prone to bilateral metastasis, and even in smaller lesions of that site, the incidence of contralateral metastasis is > 20%³⁸.

Nevertheless, it has been observed that the localization of SCCs does not totally account for their clinical behaviour. In fact, glottic tumours extending or recurring in the supraglottic region have a markedly lower proclivity to neck metastasis than primitive supraglottic SCCs.

Other "spatial" factors influencing metastatic tendency have been hypothesized to be location (central *vs.* marginal), volume, T-stage, growth modalities (exophytic *vs.* endophytic).

Nevertheless, the combination of these parameters is not adequately reliable in the prediction of lymph node metastases. In fact, clinically homogeneous LSCCs can be characterized by a different behaviour.

Histological predictive markers of neck node metastases

Histopathological features of tumours have been evaluated with the aim to assess correlations with metastatic potential.

It has been observed that primitive supraglottic lesions are more likely to be non-keratinizing and poorly differentiated, and they have more aggressive local behaviour in general³⁵. Those lesions of the vocal cords, on the other hand, are more often well differentiated and tend to be less aggressive locally. Although the degree of cellular differentiation is not thought to be the most significant fact in tumour grading, it has been reported to correlate with the probability of cervical metastasis³⁹⁻⁴², which, in turn, has a strong impact on survival⁴³. On the other hand, several molecular markers of differentiation have so far been studied in relation with propensity to neck metastasis and relapse-free survival, with often very promising results⁴⁴⁻⁴⁸ (see below). Other local characteristics, such as tumour-host interface^{35,40}, peritumour inflammatory response⁴⁹, and vascular and perineural invasion⁵⁰, also seem important in determining performance. Finally, the actual tumour thickness and depth of invasion almost certainly have an influence on metastasis and, ultimately, on survival. A variety of studies have attempted to standardize the predictive value of thickness in SCCs of the upper aerodigestive tract with the probability of cervical metastasis and, therefore, prognosis^{49,51-54}. Although head and neck oncologists, for some time, intuitively favoured a direct correlation between the two, a number of studies have failed to demonstrate a statistically significant association between tumour thickness and nodal metastasis^{38,50,55}. Furthermore, it should be pointed out that those studies demonstrating a correlation between thickness and metastasis generally focused on sites other than the larynx, and because of the anatomic complexity and embryologic uniqueness of the larynx, one cannot necessarily transpose such data from other head and neck organs. In conclusion, histopathologic parameters are not employed, at present, in treatment planning and prognostic assessment in laryngeal cancer, also because of the difficulties in the standardization of methods and, therefore, the low reproducibility of results. Furthermore, in our opinion, a notable biological heterogeneity can hide behind up histologically homogeneous SCCs of the larynx and after all accounts for the different clinical behaviours.

Molecular characterization

Molecular, by the study of molecular predictive factors, is a clinical approach aimed to define more ho-

mogeneous groups of patients for treatment selection; it represents an attempt to overcome the well-known lack of consistency in the choice of treatment and to eventually improve overall survival. Even if a plethora of reports have attempted to evaluate their potential clinical role, no molecular marker contributes, at present, to the clinical decision-making process.

The perfect marker for molecular characterization of LSCC may not always be present in malignant cells, but invariably associated with precise biological features and a predictable clinical behaviour, and easily detectable by a standardized, reliable and simple assay on a small sample, such as a biopsy specimen. So far, no such marker has been described.

In previous reports^{10,56}, we hypothesized that the search for three or four well-defined characterizing biological markers might allow us to classify tumours as positive (Mc+) or negative (Mc-), at molecular characterization.

TNM staging would thus become TNM-Mc staging. This would result in a better prognostic stratification of patients and the most suitable individualized ("à la carte") treatment could be selected. It would prevent overtreatment of Mc- patients and, most importantly, the undertreatment of Mc+ patients, which has probably contributed to the above-mentioned failure in improving LSCC prognosis in the last 30 years.

Furthermore, by means of selected and specific molecular markers, we can try to separately assess some specific biological/clinical features of tumours, such as aggressiveness, invasiveness, radio- and chemosensitivity. Here, we define tumour aggressiveness as the tendency to local disease progression. Invasiveness is the intrinsic tendency of tumours to metastasise. Our group evaluated several potential markers of invasiveness (Table I) (see below). These obviously have a great impact on prognosis and would lead to modifications in therapeutic decisions, offering information to define the most suitable management of the neck, both in N0 and N+.

In fact, management of cervical lymph nodes represents a vitally important component of the overall approach to patients with LSCC. Surgery remains the mainstay of treatment for cervical lymph nodes since it provides comprehensive clearance of all grossly enlarged lymph nodes and allows accurate histological information to be obtained concerning micrometastases in the clinically negative neck. Nevertheless, while the indication for comprehensive surgical clearance of the neck with clinically palpable metastatic lymph nodes (cN+) is obvious, the indication for elective selective treatment of clinically negative neck (cN0) is less clear^{21-23,57}.

– In Mc-, "a wait and see" (observation) approach to cN0 tumours and even selective, rather than

Table 1. Molecular markers of invasiveness evaluated on patients from a single institution.

Molecular marker	Function in the normal cells	Alterations in tumour cells
Epidermal Growth Factor Receptor	Receptor for growth factors (TGF and EGF) with tyrosine kinase activity. Upstream activator of MAPkinase pathway and of other pathways involved in cell growth, cell migration, block of apoptosis (Fig. 1).	Frequently and early overexpressed in LSCC, mainly by post-translational mechanisms. At present, the most reliable biological marker for molecular characterization. Marker of aggressiveness ^{4 7} and of invasiveness ¹ .
Overexpression and amplification of cyclin D1 gene (<i>CCND1</i>)	Cyclin D1 gene transcriptional activity normally strictly depends on mitogen stimulation, and leads to cell commitment to mitosis through START checkpoint.	Early <i>CCND1</i> overexpression is often detectable without evidence of gene amplification, it can be used for molecular epidemiology but it seems to retain a lower prognostic value, if compared with <i>CCND1</i> amplification, marker of aggressiveness in LSCC ⁵ . Its role as marker of invasiveness is still unproven.
Cathepsin D	Lytic enzyme active in extracellular matrix rearrangement.	Overexpression is often detectable in tumour cells, where it seems to contribute to invasiveness ⁸ .
S100-A2 Ca ²⁺ binding protein	Increasing levels of expression during differentiation of squamous epithelial cells; absent in basal layers.	Underexpression in cancer cells, inversely proportional to tumour differentiation. Starting from data concerning NSCLC, a role as a real oncosuppressor has been hypothesized ⁴⁴ . It may act as a marker both of aggressiveness and of invasiveness.
Methyl-p-hydroxyphenyllactate esterase (MEPHLase) activity	Enzyme involved in the metabolism of methyl-p-hydroxyphenyllactate, ligand of type II EBS, with a role in growth and differentiation of several tissues (breast, uterus), normally expressed in larynx.	In LSCC, a low activity is associated with poor differentiation, and shorter overall survival and metastasis-free survival ⁶⁵ .
Type 2 cyclooxygenase 2 (Cox-2)	Enzyme involved in arachidonic acid metabolism and autacoid synthesis, induced by various stimuli in several cell types. Inhibited by FANS.	Cox-2 activity seems to promote tumour neoangiogenesis. Nevertheless, evidence exists showing that low Cox-2 expression indicates poor differentiation and higher

comprehensive, ipsilateral neck dissection, without elective contralateral neck dissection, in cN1 tumours, could be justified.

- In Mc+, the clinically negative neck would be managed by a more aggressive approach involving elective bilateral neck dissection or elective irradiation, also considering that invasive tumours may be prone to N2 recurrences, with a markedly lower salvageability than N1¹⁶. In cN1 patients, comprehensive ipsilateral neck dissection, with elective selective contralateral neck dissection might be hypothesized. Adjuvant radiotherapy could be recommended also in tumours with histologically negative resection margins, and/or in stage pN1 without extracapsular spread. On the other hand, in N1 patients a planned neck dissection treated by chemoradiation may be recommended. Extracapsular spread and N2-3 spread have been shown to be important prognostic indicators for distant metastasis (DM), in large retrospective reviews⁵⁸⁻⁵⁹. Although induction chemotherapy did not improve loco-regional recurrence, a trend suggesting decreased rates of distant metastases was seen for patients treated with some chemotherapy protocols⁶⁰⁻⁶³. Positive markers of invasiveness might further suggest the indication for induction or adjuvant chemotherapy in order to decrease DMs, which, in some subsets of advanced disease, are also a relevant issue.
- Several features of SCCs have been evaluated, at molecular level, in order to assess their correlation with clinical behaviour in terms of aggressiveness, chemo-radiosensitivity and, in particular, invasiveness.

Among the markers evaluated so far, some appear to be potentially reliable and suitable, from a clinical viewpoint.

Characterizing molecular markers of invasiveness

In the last few years, cDNA microarrays, which can be a powerful tool from which large amounts of genetic information can be obtained, have already been used for an initial attempt at molecular classification based on patterns of global gene expression in HN-SCC⁶⁴⁻⁶⁵. However, thus far, this technology can only be applied to frozen tissues, because RNA is destroyed during the formalin-fixation process. Therefore, one would need a frozen tumour bank in conjunction with a powerful clinical database and complex statistical analytical ability to make use of this expensive technology.

The Epidermal Growth Factor Receptor (EGFR) belongs to the Type I receptor tyrosine kinase family.

This family includes four members: EGFR (also known as *erbB1/HER1*), *erbB-2/Neu/HER2*, *erbB-3/HER3* and *erbB-4/HER4*. EGFR is a 170 kDa transmembrane glycoprotein with great homology with the avian erythroblastosis virus-transforming protein *v-erbB*. The effects of EGFR activation lead to generation of intracellular second messengers and different biological responses, such as cell proliferation, gene transcription and other cellular activities through several downstream signalling pathways⁶⁶⁻⁶⁷. There is provocative evidence supporting a strong role for EGFR expression (and, to a lower extent, for its ligand, tumour growth factor alpha TGF α) in predicting prognosis of LSCC, as it adversely influences both overall, relapse-free and, in particular, regional metastasis-free, survival in LSCC¹ (Fig. 1). Such a strong predictive value is retained by EGFR independently of treatment (surgery, chemotherapy and radiation)^{1,4,7,68-71} and, in our opinion, EGFR the most reliable prognostic molecular marker, at present.

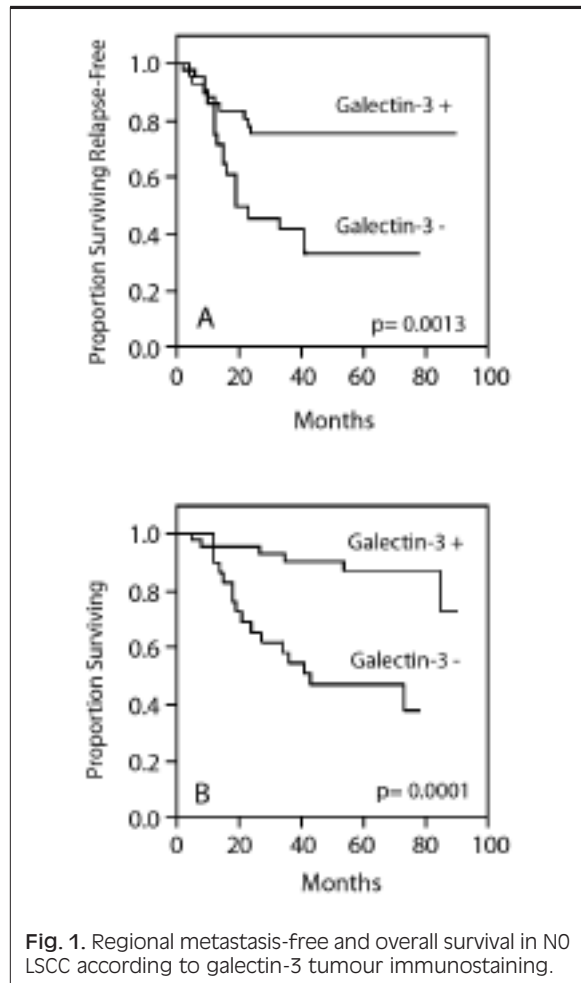


Fig. 1. Regional metastasis-free and overall survival in NO LSCC according to galectin-3 tumour immunostaining.

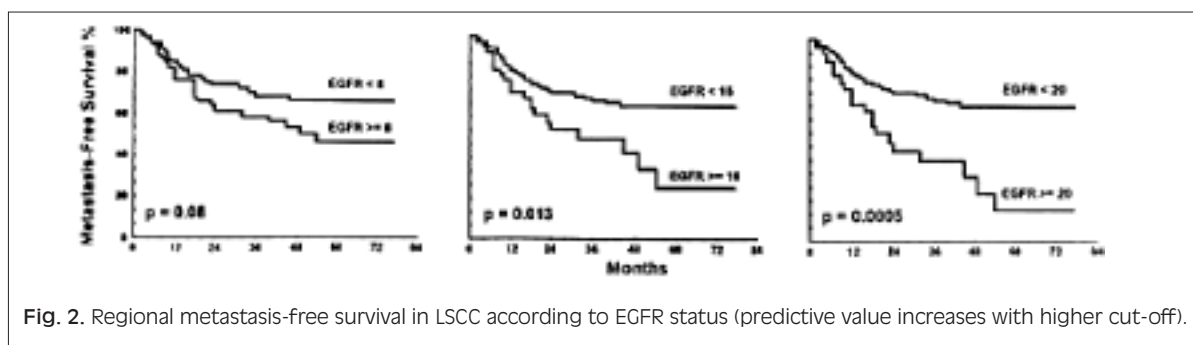


Fig. 2. Regional metastasis-free survival in LSCC according to EGFR status (predictive value increases with higher cut-off).

Moreover an overexpression of EGFR is associated with an increased degradation of the extracellular matrix by metalloproteases and cathepsin D, which plays an important role in tumour growth, invasion and metastasis, as well as in tumour-induced angiogenesis^{8 11 72}, and is potentially correlated with invasiveness.

Markers of epithelial differentiation, such as laminin-5, galectin-3, Cox-2, have been evaluated in order to integrate the classical histological evaluation and have shown a predictive value of neck node relapse (Fig. 2)⁴⁶⁻⁴⁸. S100 A2, which also seems to have a role as predictor of neck node relapse in N0 necks, has been recently hypothesized not merely as a differentiation marker, but as a real oncosuppressor with a prognostic significance stronger than the simple histopathological grading^{44 45}.

Alterations of p53 protein expression and mutations of p53 gene have been extensively studied for the evaluation of their predictive role. P53 alterations have been proposed as independent predictors of recurrence in LSCC^{73 74}, but this prognostic value seems controversial¹⁴, especially in surgically treated patients⁷⁵. P53 overexpression, detected by immunohistochemistry (IHC) in a high percentage of LSCCs⁷⁶, was hypothesized to correlate well with p53 mutation⁷⁷, but a recent study documented significant disagreement between p53 IHC and genotyping data⁷⁸. P53 gene mutation has been hypothesized to be more reliable than IHC overexpression for characterization and it has been reported to predict the response to radiotherapy in LSCC patients⁷⁸. This is consistent with the biological role of p53, which mediates apoptosis associated with DNA damage. Nevertheless, evidence of a correlation

with overall, and most of all, regional metastasis-free survival is still lacking^{14 75}.

Other promising markers of invasiveness in LSCC may be nm23-H1 protein^{79 80}, PCNA^{81 82}, p27⁸³, CD44H⁸⁴.

However, various problems have prevented the clinical application of molecular markers for tumour characterization. First of all, the perfect marker for molecular characterization, as described above, remains to be demonstrated. In particular, detection assays must be practical and reliable and should be readily available. The inconsistency of assay methods for the most studied factors, as well as patient and treatment heterogeneity, all contribute to the impossibility to draw definitive conclusions. It is necessary to further evaluate the most promising molecular marker proposed for clinical practice both by a metanalysis of data present in the literature and by multidisciplinary and multicentric clinical trials.

Conclusion

At present, we are probably at a crossroad: the time for the integration of molecular markers in prognostic assessment and treatment selection, as already observed, for example, in breast cancer, is probably very close. Moreover, this perspective appears very intriguing inasmuch as it may be the key to overcoming the above-mentioned lack of consistency in treatment selection, in particular for neck management^{21 23}, which remains the most controversial issue both in N0 (in particular if the primary tumour is supraglottic) and in N+ LSCCs.

References

- Almadori G, Cadoni G, Galli J, Ferrandina G, Scambia G, Exarchakos G, et al. *Epidermal growth factor receptor expression in primary laryngeal cancer: an independent prognostic factor of neck node relapse*. Int J Cancer 1999;84:188-91.
- Scambia G, Panici PB, Battaglia F, Ferrandina G, Almadori G, Paludetti G, et al. *Receptors for epidermal growth factor and steroid hormones in primary laryngeal tumours*. Cancer 1991;67:1347-51.
- Scambia G, Catozzi L, Benedetti PP, Ferrandina G, Almadori G, Paludetti G, et al. *Expression of ras oncogene p21 protein in normal and neoplastic laryngeal tissues*:

- correlation with histopathological features and epidermal growth factor receptors. *Br J Cancer* 1994;69:995-9.
- 4 Maurizi M, Scambia G, Benedetti PP, Ferrandina G, Almadori G, Paludetti G, et al. *EGF receptor expression in primary laryngeal cancer: correlation with clinico-pathological features and prognostic significance*. *Int J Cancer* 1992;52:862-6.
 - 5 Bellacosa A, Almadori G, Cavallo S, Cadoni G, Galli J, Ferrandina G, et al. *Cyclin D1 gene amplification in human laryngeal squamous cell carcinomas: prognostic significance and clinical implications*. *Clin Cancer Res* 1996;2:175-80.
 - 6 Hohaus S, Cavallo S, Bellacosa A, Genuardi M, Galli J, Cadoni G, et al. *Telomerase activity in human laryngeal squamous cell carcinomas*. *Clin Cancer Res* 1996;2:1895-900.
 - 7 Maurizi M, Almadori G, Ferrandina G, Distefano M, Romanini ME, Cadoni G, et al. *Prognostic significance of epidermal growth factor receptor in laryngeal squamous cell carcinoma*. *Br J Cancer* 1996;74:1253-7.
 - 8 Maurizi M, Almadori G, Cadoni G, Scambia G, Ottaviani F, Ferrandina G, et al. *Cathepsin D concentration in primary laryngeal cancer: correlation with clinico-pathological parameters, EGFR status and prognosis*. *Int J Cancer* 1996;69:105-9.
 - 9 Almadori G, Cadoni G, Cattani P, Posteraro P, Scarano E, Ottaviani F, et al. *Detection of human papilloma virus DNA in laryngeal squamous cell carcinoma by polymerase chain reaction*. *Eur J Cancer* 1996;32A:783-8.
 - 10 Almadori G, Bussu F, Cadoni G, Galli J, Paludetti G, Maurizi M. *Molecular markers in laryngeal squamous cell carcinoma: towards an integrated clinicobiological approach*. *Eur J Cancer* 2005;41:683-93.
 - 11 Ferrandina G, Scambia G, Benedetti PP, Almadori G, Paludetti G, Cadoni G, et al. *Cathepsin D in primary squamous laryngeal tumours: correlation with clinico-pathological parameters and receptor status*. *Cancer Lett* 1992;67:133-8.
 - 12 Jemal A, Siegel R, Ward E, Murray T, Xu J, Smigal C, et al. *Cancer statistics, 2006*. *CA Cancer J Clin* 2006;56:106-30.
 - 13 Huang Q, Yu GP, McCormick SA, Mo J, Datta B, Mahimkar M, et al. *Genetic differences detected by comparative genomic hybridization in head and neck squamous cell carcinomas from different tumour sites: construction of oncogenetic trees for tumour progression*. *Genes Chromosomes Cancer* 2002;34:224-33.
 - 14 Bosch FX, Ritter D, Enders C, Flechtenmacher C, Abel U, Dietz A, et al. *Head and neck tumour sites differ in prevalence and spectrum of p53 alterations but these have limited prognostic value*. *Int J Cancer* 2004;111:530-8.
 - 15 Shah JP, Karnell LH, Hoffman HT, Ariyan S, Brown GS, Fee WE, et al. *Patterns of care for cancer of the larynx in the United States*. *Arch Otolaryngol Head Neck Surg* 1997;123:475-83.
 - 16 Shah JP, Patel KJ. *Head and Neck Surgery and Oncology*. 3rd Ed., Edinburgh: Mosby 2003.
 - 17 Licitra L, Bernier J, Grandi C, Locati L, Merlano M, Gatta G, et al. *Cancer of the larynx*. *Crit Rev Oncol Hematol* 2003;47:65-80.
 - 18 Franchin G, Minatel E, Gobitti C, Talamini R, Vaccher E, Sartor G, et al. *Radiotherapy for patients with early-stage glottic carcinoma: univariate and multivariate analyses in a group of consecutive, unselected patients*. *Cancer* 2003;98:765-72.
 - 19 Spector JG, Sessions DG, Haughey BH, Chao KS, Simpson J, El Mofty S, et al. *Delayed regional metastases, distant metastases, and second primary malignancies in squamous cell carcinomas of the larynx and hypopharynx*. *Laryngoscope* 2001;111:1079-87.
 - 20 Ferlito A, Bradley PJ, Rinaldo A. *What is the treatment of choice for T1 squamous cell carcinoma of the larynx?* *J Laryngol Otol* 2004;118:747-9.
 - 21 Ferlito A, Rinaldo A, Silver CE, Gourin CG, Shah JP, Clayman GL, et al. *Elective and therapeutic selective neck dissection*. *Oral Oncol* 2006;42:14-25.
 - 22 Ferlito A, Rinaldo A, Silver CE, Shah JP, Suarez C, Medina JE, et al. *Neck dissection: then and now*. *Auris Nasus Larynx* 2006;33:365-74.
 - 23 Wei WI, Ferlito A, Rinaldo A, Gourin CG, Lowry J, Ho WK, et al. *Management of the N0 neck – reference or preference*. *Oral Oncol* 2006;42:115-22.
 - 24 Som ML. *Conservation surgery for carcinoma of the supraglottis*. *J Laryngol Otol* 1970;84:655-78.
 - 25 Harrison DF. *The pathology and management of subglottic cancer*. *Ann Otol Rhinol Laryngol* 1971;80:6-12.
 - 26 Lindberg R. *Distribution of cervical lymph node metastases from squamous cell carcinoma of the upper respiratory and digestive tracts*. *Cancer* 1972;29:1446-9.
 - 27 Crissman JD. *Laryngeal keratosis and subsequent carcinoma*. *Head Neck Surg* 1979;1:386-91.
 - 28 Levendag P, Vikram B. *The problem of neck relapse in early stage supraglottic cancer – results of different treatment modalities for the clinically negative neck*. *Int J Radiat Oncol Biol Phys* 1987;13:1621-4.
 - 29 Ogura JH, Sessions DG, Spector GJ. *Conservation surgery for epidermoid carcinoma of the supraglottic larynx*. *Laryngoscope* 1975;85:1808-15.
 - 30 Kirchner JA, Owen JR. *Five hundred cancers of the larynx and pyriform sinus. Results of treatment by radiation and surgery*. *Laryngoscope* 1977;87:1288-303.
 - 31 Hansen HS. *Supraglottic carcinoma of the aryepiglottic fold*. *Laryngoscope* 1975;85:1667-81.
 - 32 Shah JP, Tollefsen HR. *Epidermoid carcinoma of the supraglottic larynx. Role of neck dissection in initial surgical treatment*. *Am J Surg* 1974;128:494-9.
 - 33 Ogura JH, Biller HF, Wette R. *Elective neck dissection for pharyngeal and laryngeal cancers. An evaluation*. *Ann Otol Rhinol Laryngol* 1971;80:646-50.
 - 34 Putney FJ. *Elective vs. delayed neck dissection in cancer of the larynx*. *Surg Gynecol Obstet* 1961;112:736-42.
 - 35 McGavran MH, Bauer WC, Ogura JH. *The incidence of cervical lymph node metastases from epidermoid carcinoma of the larynx and their relationship to certain characteristics of the primary tumour. A study based on the clinical and pathological findings for 96 patients treated by primary en bloc laryngectomy and radical neck dissection*. *Cancer* 1961;14:55-66.
 - 36 Biller HF, Davis WH, Ogura JH. *Delayed contralateral cervical metastases with laryngeal and laryngopharyngeal cancers*. *Laryngoscope* 1971;81:1499-502.
 - 37 Ogura JH, Spector GJ, Sessions DG. *Conservation surgery*

- for epidermoid carcinoma of the marginal area (aryepiglottic fold extension). *Laryngoscope* 1975;85:1801-7.
- 38 Morton RP, Ferguson CM, Lambie NK, Whitlock RM. *Tumour thickness in early tongue cancer*. *Arch Otolaryngol Head Neck Surg* 1994;120:717-20.
- 39 Lauerma S. *Treatment of laryngeal cancer. A study of 638 cases*. *Acta Otolaryngol Ital* 1967;(Suppl 225):1.
- 40 Kashima HK. *The characteristics of laryngeal cancer correlating with cervical lymph node metastasis*. *Can J Otolaryngol* 1975;4:893-902.
- 41 Reid AP, Robin PE, Powell J, McConkey CC, Rockley T. *Staging carcinoma: its value in cancer of the larynx*. *J Laryngol Otol* 1991;105:456-8.
- 42 Hirabayashi H, Koshii K, Uno K, Ohgaki H, Nakasone Y, Fujisawa T, et al. *Extracapsular spread of squamous cell carcinoma in neck lymph nodes: prognostic factor of laryngeal cancer*. *Laryngoscope* 1991;101:502-6.
- 43 Spiro RH, Alfonso AE, Farr HW, Strong EW. *Cervical node metastasis from epidermoid carcinoma of the oral cavity and oropharynx. A critical assessment of current staging*. *Am J Surg* 1974;128:562-7.
- 44 Lauriola L, Michetti F, Maggiano N, Galli J, Cadoni G, Schafer BW, et al. *Prognostic significance of the Ca(2+) binding protein S100A2 in laryngeal squamous-cell carcinoma*. *Int J Cancer* 2000;89:345-9.
- 45 Lee SW, Tomasetto C, Swisshelm K, Keyomarsi K, Sager R. *Down-regulation of a member of the S100 gene family in mammary carcinoma cells and reexpression by azadeoxycytidine treatment*. *Proc Natl Acad Sci USA* 1992;89:2504-8.
- 46 Nordemar S, Kronenwett U, Auer G, Hogmo A, Lindholm J, Edstrom S, et al. *Laminin-5 as a predictor of invasiveness in cancer in situ lesions of the larynx*. *Anticancer Res* 2001;21:509-12.
- 47 Piantelli M, Iacobelli S, Almadori G, Iezzi M, Tinari N, Natoli C, et al. *Lack of expression of galectin-3 is associated with a poor outcome in node-negative patients with laryngeal squamous-cell carcinoma*. *J Clin Oncol* 2002;20:3850-6.
- 48 Ranelletti FO, Almadori G, Rocca B, Ferrandina G, Ciabattani G, Habib A, et al. *Prognostic significance of cyclooxygenase-2 in laryngeal squamous cell carcinoma*. *Int J Cancer* 2001;95:343-9.
- 49 Mohit-Tabatabai MA, Sobel HJ, Rush BF, Mashberg A. *Relation of thickness of floor of mouth stage I and II cancers to regional metastasis*. *Am J Surg* 1986;152:351-3.
- 50 Close LG, Brown PM, Vuitch MF, Reisch J, Schaefer SD. *Microvascular invasion and survival in cancer of the oral cavity and oropharynx*. *Arch Otolaryngol Head Neck Surg* 1989;115:1304-9.
- 51 Spiro RH, Huvos AG, Wong GY, Spiro JD, Gnecco CA, Strong EW. *Predictive value of tumour thickness in squamous carcinoma confined to the tongue and floor of the mouth*. *Am J Surg* 1986;152:345-50.
- 52 Rasgon BM, Cruz RM, Hilsinger RL Jr, Sawicki JE. *Relation of lymph-node metastasis to histopathologic appearance in oral cavity and oropharyngeal carcinoma: a case series and literature review*. *Laryngoscope* 1989;99:1103-10.
- 53 Platz H, Fries R, Hudec M, Min TA, Wagner RR. *The prognostic relevance of various factors at the time of the first admission of the patient. Retrospective DOSAK study on carcinoma of the oral cavity*. *J Maxillofac Surg* 1983;11:3-12.
- 54 Cheng KC, Cahill DS, Kasai H, Nishimura S, Loeb LA. *8-Hydroxyguanine, an abundant form of oxidative DNA damage, causes G-T and A-C substitutions*. *J Biol Chem* 1992;267:166-72.
- 55 Ravasz LA, Hordijk GJ, Slootweg PJ, Smit F, Tweel IV. *Uni- and multivariate analysis of eight indications for post-operative radiotherapy and their significance for local-regional cure in advanced head and neck cancer*. *J Laryngol Otol* 1993;107:437-40.
- 56 Almadori G, Galli J, Cadoni G, Bussu F, Scarano E, Maurizi M. *Prospects and therapeutic decisions in the light of biological findings in laryngeal cancer*. *Acta Otorhinolaryngol Ital* 2000;20:407-12.
- 57 Ferlito A, Rinaldo A, Robbins KT, Silver CE. *Neck dissection: past, present and future?* *J Laryngol Otol* 2006;120:87-92.
- 58 Leemans CR, Tiwari R, Nauta JJ, van der Waal I, Snow GB. *Regional lymph node involvement and its significance in the development of distant metastases in head and neck carcinoma*. *Cancer* 1993;71:452-6.
- 59 Myers JN, Greenberg JS, Mo V, Roberts D. *Extracapsular spread. A significant predictor of treatment failure in patients with squamous cell carcinoma of the tongue*. *Cancer* 2001;92:3030-6.
- 60 Brockstein BE. *Reduction of distant metastases in head and neck cancer with concomitant chemotherapy*. *J Clin Oncol* 2000;18:3320-1.
- 61 No Authors listed. *Induction chemotherapy plus radiation compared with surgery plus radiation in patients with advanced laryngeal cancer. The Department of Veterans Affairs Laryngeal Cancer Study Group*. *N Engl J Med* 1991;324:1685-90.
- 62 Lefebvre JL, Chevalier D, Luboinski B, Kirkpatrick A, Collette L, Sahnoud T. *Larynx preservation in pyriform sinus cancer: preliminary results of a European Organization for Research and Treatment of Cancer phase III trial. EORTC Head and Neck Cancer Cooperative Group*. *J Natl Cancer Inst* 1996;88:890-9.
- 63 Al-Sarraf M, LeBlanc M, Giri PG, Fu KK, Cooper J, Vuong T, et al. *Chemoradiotherapy vs. radiotherapy in patients with advanced nasopharyngeal cancer: phase III randomized Intergroup study 0099*. *J Clin Oncol* 1998;16:1310-7.
- 64 Belbin TJ, Singh B, Barber I, Socci N, Wenig B, Smith R, et al. *Molecular classification of head and neck squamous cell carcinoma using cDNA microarrays*. *Cancer Res* 2002;62:1184-90.
- 65 Leethanakul C, Patel V, Gillespie J, Shillitoe E, Kellman RM, Ensley JF, et al. *Gene expression profiles in squamous cell carcinomas of the oral cavity: use of laser capture microdissection for the construction and analysis of stage-specific cDNA libraries*. *Oral Oncol* 2000;36:474-83.
- 66 Song JI, Grandis JR. *STAT signaling in head and neck cancer*. *Oncogene* 2000;19:2489-95.
- 67 Prenzel N, Fischer OM, Streit S, Hart S, Ullrich A. *The epidermal growth factor receptor family as a central element for cellular signal transduction and diversification*. *Endocr Relat Cancer* 2001;8:11-31.
- 68 Wen QH, Miwa T, Yoshizaki T, Nagayama I, Furukawa M, Nishijima H. *Prognostic value of EGFR and TGF-alpha in early laryngeal cancer treated with radiotherapy*. *Laryngoscope* 1996;106:884-8.

- ⁶⁹ Gupta AK, McKenna WG, Weber CN, Feldman MD, Goldsmith JD, Mick R, et al. *Local recurrence in head and neck cancer: relationship to radiation resistance and signal transduction*. Clin Cancer Res 2002;8:885-92.
- ⁷⁰ Rubin GJ, Melhem MF, Gooding WE, Day R, Holst VA, Wagener MM, et al. *Levels of TGF- α and EGFR protein in head and neck squamous cell carcinoma and patient survival*. J Natl Cancer Inst 1998;90:824-32.
- ⁷¹ Dassonville O, Formento JL, Francoual M, Ramaioli A, Santini J, Schneider M, et al. *Expression of epidermal growth factor receptor and survival in upper aerodigestive tract cancer*. J Clin Oncol 1993;11:1873-8.
- ⁷² Johansson N, Kahari VM. *Matrix metalloproteinases in squamous cell carcinoma*. Histol Histopathol 2000;15:225-37.
- ⁷³ Narayana A, Vaughan AT, Gunaratne S, Kathuria S, Walter SA, Reddy SP. *Is p53 an independent prognostic factor in patients with laryngeal carcinoma?* Cancer 1998;82:286-91.
- ⁷⁴ Osman I, Sherman E, Singh B, Venkatraman E, Zelefsky M, Bosl G, et al. *Alteration of p53 pathway in squamous cell carcinoma of the head and neck: impact on treatment outcome in patients treated with larynx preservation intent*. J Clin Oncol 2002;20:2980-7.
- ⁷⁵ Alsner J, Sorensen SB, Overgaard J. *TP53 mutation is related to poor prognosis after radiotherapy, but not surgery, in squamous cell carcinoma of the head and neck*. Radiother Oncol 2001;59:179-85.
- ⁷⁶ Anwar K, Nakakuki K, Imai H, Naiki H, Inuzuka M. *Overexpression of p53 protein in human laryngeal carcinoma*. Int J Cancer 1993;53:952-6.
- ⁷⁷ Maestro R, Dolcetti R, Gasparotto D, Doglioni C, Pelucchi S, Barzan L, et al. *High frequency of p53 gene alterations associated with protein overexpression in human squamous cell carcinoma of the larynx*. Oncogene 1992;7:1159-66.
- ⁷⁸ Taylor D, Koch WM, Zahurak M, Shah K, Sidransky D, Westra WH, et al. *Immunohistochemical detection of p53 protein accumulation in head and neck cancer: correlation with p53 gene alterations*. Hum Pathol 1999;30:1221-5.
- ⁷⁹ Lee CS, Redshaw A, Boag G. *nm23-H1 protein immunoreactivity in laryngeal carcinoma*. Cancer 1996;77:2246-50.
- ⁸⁰ Gunduz M, Ayhan A, Gullu I, Onerci M, Hosal AS, Gursel B, et al. *nm23 protein expression in larynx cancer and the relationship with metastasis*. Eur J Cancer 1997;33:2338-41.
- ⁸¹ Liu M, Lawson G, Delos M, Jamart J, Ide C, Coche E, et al. *Predictive value of the fraction of cancer cells immunolabeled for proliferating cell nuclear antigen or Ki67 in biopsies of head and neck carcinomas to identify lymph node metastasis: comparison with clinical and radiologic examinations*. Head Neck 2003;25:280-8.
- ⁸² Franchi A, Gallo O, Boddi V, Santucci M. *Prediction of occult neck metastases in laryngeal carcinoma: role of proliferating cell nuclear antigen, MIB-1, and E-cadherin immunohistochemical determination*. Clin Cancer Res 1996;2:1801-8.
- ⁸³ Pruneri G, Pignataro L, Carboni N, Buffa R, Di Finizio D, Cesana BM, et al. *Clinical relevance of expression of the CIP/KIP cell-cycle inhibitors p21 and p27 in laryngeal cancer*. J Clin Oncol 1999;17:3150-9.
- ⁸⁴ Spafford MF, Koeppe J, Pan Z, Archer PG, Meyers AD, Franklin WA. *Correlation of tumour markers p53, bcl-2, CD34, CD44H, CD44v6, and Ki-67 with survival and metastasis in laryngeal squamous cell carcinoma*. Arch Otolaryngol Head Neck Surg 1996;122:627-32.
- ⁸⁵ Maurizi M, Ferrandina G, Almadori G, Scambia G, Cadoni G, D'Agostino G, et al. *Prognostic significance of methyl-p-hydroxy-phenyllactate-esterase activity in laryngeal squamous cell carcinoma*. Br J Cancer 1998;77:1253-9.

■ Received: September 25, 2006
Accepted: October 15, 2006

■ Address for correspondence: Prof. G. Almadori, Istituto di Otorinolaringologia, Università Cattolica del Sacro Cuore, Roma, Italy. E-mail: giovanni.almadori@rm.unicatt.it