

## CASE REPORT

# Tracheotomy-related posterior tracheal wall rupture, trans-tracheal repair

*Rottura della parete posteriore della trachea da tracheotomia.  
Riparazione trans-tracheale*

A. DEGANELLO, M.C. SOFRA<sup>1</sup>, F. FACCIOLLO<sup>2</sup>, G. SPRIANO

Department of Otolaryngology Head and Neck Surgery, Azienda Ospedaliero-Universitaria "Careggi", Firenze;

<sup>1</sup>Department of Anesthesiology; <sup>2</sup>Department of Thoracic Surgery, National Cancer Institute "Regina Elena", Rome, Italy

## SUMMARY

Laceration of the membranous part of the tracheo-bronchial tree is a rare complication that can occur after single lumen intubation, double-lumen intubation, percutaneous and surgical tracheotomy. The case of a 76-year-old male is presented in whom a posterior tracheal wall laceration, related to tracheotomy, was diagnosed and immediately treated at the end of a head and neck operation. A 6 cm long laceration started 1.5 cm below the tracheotomy level and ended 2 cm above the carina. The tear was closed from distal to proximal area via the tracheotomy opening with PDS 4/0 interrupted sutures using a thoracoscopic needle-holder. This original surgical technique is described in detail. In tracheotomy related tears, the fact that an opening in the trachea already exists and that the lesion rarely extends beyond the carina, should guide the surgeon to make every effort to repair the laceration through this already existing access.

KEY WORDS: Trachea • Tracheotomy • Complication • Tracheal rupture • Surgical treatment

## RIASSUNTO

*La rottura della pars membranacea tracheo-bronchiale è un'evenienza rara che si può riscontrare in seguito ad intubazioni con tubi a singolo o doppio lume ed in seguito a tracheotomie percutanee o chirurgiche. Viene presentato il caso di un paziente di 76 anni trattato chirurgicamente per un carcinoma del cavo orale. Al termine dell'intervento una lacerazione della pars membranacea tracheale, dovuta alla tracheotomia, è stata prontamente diagnosticata e trattata. La rottura tracheale era situata in posizione mediana, si estendeva per 6 cm, iniziava 1,5 cm sotto il livello dell'apertura tracheotomica e terminava 2 cm al di sopra della carena. La riparazione transtracheale da distale a prossimale è stata eseguita con filo PDS 4/0 a punti staccati utilizzando un passafili toracoscopico. L'originale tecnica chirurgica viene descritta dettagliatamente. Nel trattamento delle lesioni iatrogene della pars membranacea dovute alla tracheotomia, il fatto che esista già un accesso diretto alla trachea e che la lesione non si estenda ai bronchi, deve spingere il chirurgo a fare ogni sforzo per riparare la breccia attraverso l'apertura tracheotomica.*

PAROLE CHIAVE: Trachea • Tracheotomia • Complicazioni • Rottura della trachea • Trattamento chirurgico

Acta Otorhinolaryngol Ital 2007;27:258-262

## Introduction

Laceration of the membranous part of the tracheobronchial tree is a rare complication that can occur after single lumen intubation, double-lumen intubation, percutaneous and surgical tracheotomy. The exact incidence of this complication cannot be reasonably estimated since the large number of intubations and tracheotomies performed daily, on a worldwide basis, is unknown. When diagnosis is made, surgical repair should be performed immediately in order to minimize the risk of life-threatening events such as respiratory insufficiency, mediastinal emphysema, mediastinitis, compressive pneumothorax, that may lead to cardio-pulmonary failure.

## Case report

The case of a 76-year-old male is presented in whom a posterior tracheal wall laceration, related to tracheotomy, was

diagnosed and immediately treated at the end of a head and neck operation.

The patient represented a high operative risk with reduced life expectancy (ASA IV), the medical record was positive for chronic obstructive airway disease, diabetes mellitus, renal insufficiency, obesity, anaemia and ischaemic cardiopathy for which the patient had undergone triple aorto-coronary bypass and aortic valve substitution 4 years before the head and neck operation. The patient presented with a cT4aN2b retromolar trigone squamous cell carcinoma on the left hand side and because of the severe co-morbidity the patient was initially treated with elective external beam radiotherapy. Surgical indication was given due to failure of the local radiotherapy: tumour restage rT4aN0.

Informed consent was obtained after appropriate counselling regarding the technical aspects of surgery and the high general anaesthesia-related risks.

Pre-medication was carried out with midazolam 0.02 mg/kg and ondansetron 0.1 mg/kg.

General anaesthesia was induced by fentanyl 1 mcg/kg and propofol 2 mg/kg, both given intravenously, and maintained with 2% sevoflurane and oxygen/air mixture. Regional surface anaesthesia of the base of the tongue, posterior tracheal wall of the pharynx and vocal cords was obtained using 2% lidocaine and muscle relaxation using cis-atracurium besylate 0.2 mg/kg.

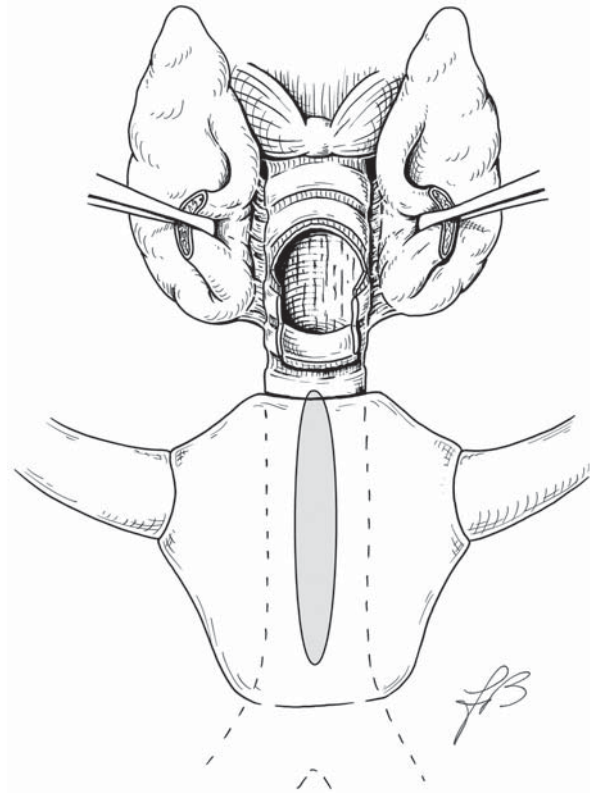
Oro-tracheal intubation was performed in a single attempt, placing a single lumen n. 8 tube. Oxygen saturation value of 99%, End Tidal CO<sub>2</sub> value of 33% and airway pressure value of 18 mbar demonstrated the lack of any problem in the intubation.

Through a horizontal cervical incision (3 cm in length) passing 1.5 cm above the jugulum, the anterior tracheal wall was easily exposed, without any bleeding, just below the thyroid isthmus, the trachea was opened between the second and third tracheal ring, an inferior based tracheal flap according to the Björk technique was created and sutured to the inferior skin edge of the cervical incision. After withdrawing the tube, a cuffed cannula n. 8 was introduced smoothly using the obturator, without any difficulty and no bleeding. Ventilation through the cannula was impossible, a suction tube was easily passed through the cannula but still there was no CO<sub>2</sub> return, so the cannula was removed to check if any damage had occurred in the trachea. At visual inspection, through the tracheotomy opening, everything looked normal without bleeding, so at this moment, there was no explanation as to why ventilation resulted impossible, however a cuffed cannula n. 10 was placed (always using the obturator), again without any difficulty and no bleeding. The patient was then effectively ventilated through the cannula, with normal airway resistances, during the entire operation which took 4 hours. Surgery included modified radical neck dissection type II with *en bloc* segmental mandibular resection, and *pectoralis major* flap reconstruction. Whilst the patient was waking up, the Anaesthesiologist claimed difficulty in passing the suction tube through the cannula but no problems with the patient's ventilation were experienced, albeit immediate bronchoscopy was performed, at the operating table.

Bronchoscopy was carried out first through the cannula then directly through the stoma after removing the cannula and a 6 cm long, full thickness, longitudinal tear was revealed in the posterior wall of the trachea, at a median position. The laceration started 1.5 cm below the tracheotomy level and ended 1.5 cm above the carina. Chest X-ray findings were normal except for the presence of a minimal pneumomediastinum at the right hand side, and clinically no subcutaneous emphysema developed. Oesophagoscopy showed no injuries.

## Surgical technique

A single lumen tube was introduced endoscopically through the tracheotomy opening with the tip of the tube touching the carina. The Björk flap was left in place, the tracheotomy skin incision was enlarged 2 cm both sides, the sterno-hyoid and sterno-thyroid muscles were divided, the thyroid isthmus was bound and divided to expose the anterior tra-



**Fig. 1.** Thyroid isthmus is divided and a complete separation between second and third tracheal ring is created maintaining continuity of trachea only via posterior wall.

cheal wall. At the tracheotomy opening, a complete separation between the second and third tracheal ring was created maintaining continuity of the trachea only via the posterior wall to gain exposure to the laceration (Fig. 1).

The tube was removed, the patient was sedated with a target-controlled infusion of propofol (target 1.5 mcg/ml) and kept spontaneously breathing with extra oxygen provided (FiO<sub>2</sub> = 50%) with a tube n. 4 maintained in correspondence to the tracheotomy. Local anaesthesia with 10% spray lidocaine, at the tracheotomy opening, was given to minimize coughing.

A Langenback retractor was introduced through the tracheal opening to retract the anterior tracheal wall, this manoeuvre allowed the surgical exposure to be increased and, at the same time, the edges of the tear were mechanically brought closer together.

The tear was then closed from distal to proximal area via the tracheotomy opening with PDS 4/0 interrupted sutures (8 stitches) using a thoracoscopic needle-holder (Fig. 2).

The needle was passed through the external layer of the anterior wall of the oesophagus, then through the edges of the tear, so that each knot (with the exception of the most proximal one) remained outside the lumen and the anterior wall of the oesophagus sealed the suture (Fig. 3).

Once the needle had been passed, each surgical knot was ligated outside the tracheotomy, then the extremities of the wire were kept outside the tracheal lumen and the knot was pushed towards the laceration by the needle holder. To firmly tie the knot, one side of the wire was grabbed by the needle holder, very close to the knot, while the other end




Fig. 2. Thoracoscopic needle holder allows needle to easily pass into the narrow tracheal lumen.

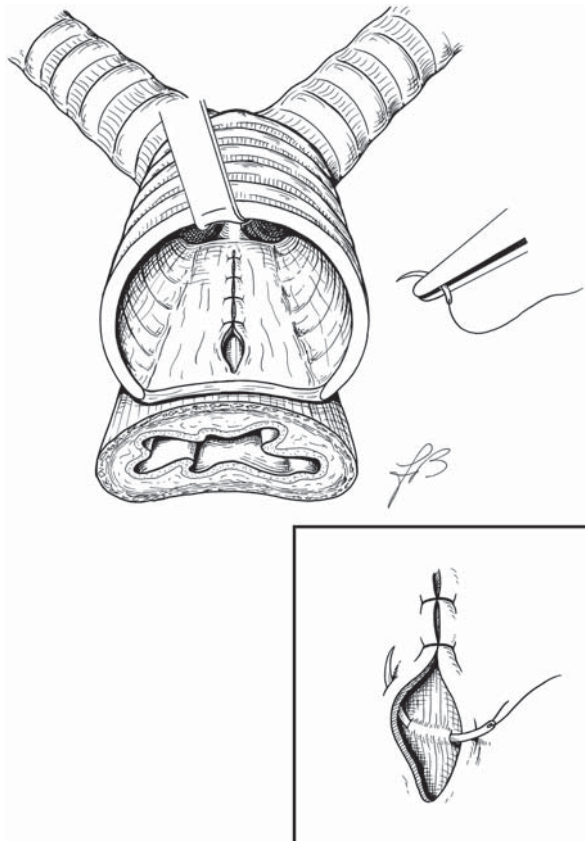


Fig. 3. Needle is passed through external layer of anterior wall of oesophagus, then through edges of tear.

was simply held by the surgeon's hand, outside the tracheotomy. The needle holder also helped by pressing upon the oesophagus and, therefore, the knot resulted in an extra-tracheal position. The last surgical knot (the most proximal) was eventually located in the intra-tracheal area and the needle was passed under the ligature of the second most proximal knot.

A very soft sylastic cannula without cuff and without inner-cannula was positioned to avoid further damage to the trachea, and the patient awoke, breathing spontaneously, and was then monitored, in the intensive care unit, for 4 days.

## Results

The patient received wide spectrum antibiotics for 3 weeks, a control chest X-ray and computed tomography of the thorax showed no pneumomediastinum. Endoscopic visualization through the tracheotomy, after temporary removal of the cannula (that was then cleaned and sterilized), was performed daily for 2 weeks, showing no dehiscence in the suture. On post-operative day 5, the extremely soft cannula was replaced by a conventional micro-fenestrated cannula n. 6 without a cuff but with an inner-cannula to allow easier management of toilette of the cannula, on day 18, the patient was able to keep the cannula closed for 48 hours, so the patient was decannulated on day 20.

## Discussion

Posterior tracheal wall laceration is an uncommon, although well recognized, potentially fatal injury. Even if the membranous part of the trachea is very friable and susceptible to tearing, especially in elderly patients and in short women<sup>1</sup>, iatrogenic laceration is a relatively infrequent event. Chronic obstructive airway disease has been suggested as a possible risk factor since enlargement of the trachea by coughing results in an increase in the surface of the membranous portion which could explain the risk of damage in this already vulnerable area<sup>2</sup>. Over inflation of the cuff and direct trauma, caused by difficult intubation or in emergency procedures, are recognized as aetiologic factors, but even in "atraumatic" airway entry procedures, tracheal lacerations may occur<sup>1-3</sup>.

Diagnosis is usually made by tracheo-bronchoscopy that follows the onset of symptoms and allows the entity and location of the rupture to be established.

Clinical symptoms occur either immediately, during mechanical ventilation (pneumomediastinum, compressive pneumothorax, extensive subcutaneous emphysema), or arise in the post-operative period (respiratory distress, mediastinitis and tracheal stenosis).

In our case (to our knowledge, the only one in the literature), fortunately, the diagnosis was made before any major symptom occurred, the patient was in such poor general conditions that, probably, development of related symptoms could have been fatal.

Several specific risk factors could have played a role, in this patient: the fibrosis related to the previous cardiothoracic surgery and the previous radiotherapy, together with the chronic obstructive airway disease that stretches the posterior tracheal wall. The presence of the extensive fibrosis might have prevented the development of severe pneumothorax by sealing the mediastinum. After this experience, we do recommend endoscopic control, if any problem occurs during airway entry in patients at risk.

Most publications report a single or a few case reports in which the laceration occurred mainly after intubation or percutaneous tracheotomy<sup>4</sup>.

In our patient, the mechanism of the rupture remains unclear. It is possible that the oro-tracheal tube caused a direct trauma in the posterior wall without the tube going into the false passage, this is actually possible, but unlikely; maybe the cuff inflation of the tube did provoke the tear, but usually traumatic ruptures caused by overinflation of the balloon are localized in the corner between the posterior wall and trachea rings. In this case, the laceration was in a median position.

Even if the cannulas were always introduced using the obturator and without any difficulty, the most probable explanation is a direct trauma to the posterior tracheal wall during introduction of the cannula n. 8. Probably, due to the fragility of the posterior wall, the obturator of the cannula perforated the *pars membranacea* thus creating a false passage directly between the posterior wall of the trachea and the anterior wall of the oesophagus. Inflation of the cuff might have increased the length of the rupture, the suction tube was easily passed in the mediastinum but ventilation was impossible. The cuff of the second cannula, larger in size (n. 10), probably filled the rupture thus allowing effective ventilation during the entire operation.

In 1978, Jacobs et al.<sup>5</sup> first reported two similar cases of posterior tracheal wall laceration as a complication of tracheotomy, both without entrance in the oesophagus, which were repaired directly through the same tracheotomy. Both patients were female and previously irradiated. In this report, both patients developed pneumothorax which oriented the diagnosis, the ruptures, 3 cm and 5 cm long, started at tracheotomy level so that they were rather proximal and could easily be recognized and managed through the tracheotomy opening.

In our patient, the fact that laceration started 2 cm below the tracheotomy level prevented direct visualization of the tear, diagnosis was then made only after tracheo-bronchoscopy and the repair required an extended tracheotomy access to gain distal sufficient exposure.

Non-surgical treatment can be considered in small (length < 2 cm) uncomplicated tears, in stable patients, since, under these conditions, healing can be achieved with minimal risks and discomfort for the patient<sup>6</sup>. Surgery is, neverthe-

less, the treatment of choice for the large majority of patients and should be performed promptly to avoid feared complications such as descendent mediastinitis<sup>7</sup>.

During the eighties and early nineties, posterior wall lacerations were treated mainly with a right thoracotomy, and, occasionally, through a lateral cervical approach. In 1995, Angelillo-Mackinlay<sup>8</sup> described the trans-cervical trans-tracheal approach, in a posterior tracheal wall laceration, after oro-tracheal intubation, in which a midline incision is made in the anterior wall of the trachea to expose the posterior wall.

In our opinion, if the injury occurs while performing a tracheotomy, the surgical repair through the same tracheotomy should be the gold standard on account of its limited invasiveness and lack of major morbidity. The tear caused by tracheotomy always lies proximal to the carina, the complete separation of the trachea rings, at the tracheotomy opening provides a sufficient surgical exposure to perform a surgical repair up to the carina. The use of the external part of the anterior oesophageal wall as a re-enforcement patch in the repair can be very helpful in sealing the laceration, a naso-gastric feeding tube is required, for at least a week, to minimize peristalsis. The surgeon must be aware of the well-recognized pressure conflict that can arise between the naso-gastric feeding tube and the cuff of the cannula, this is a major risk factor for developing tracheo-oesophageal fistulas. Thus, after the repair of the laceration, the best option is to place a non-cuffed cannula, as soft as possible, if a cuffed cannula is needed, for ventilation purposes, then the pressure in the cuff has to be maintained as low as possible.

If the aetiology is not related to tracheotomy, the rupture should not extend to the bronchi and if the patient does not require tracheotomy after surgical repair, a trans-tracheal closure, with a longitudinal opening of the anterior tracheal wall is an excellent option.

## Conclusions

Immediate surgical repair remains the standard treatment of posterior tracheal wall lacerations. The surgical approach has always been codified upon the extension and location of the tear, in general a thoracotomy is required to manage ruptures extending in the bronchial tree, otherwise a left cervical approach or a trans-tracheal approach are indicated. In tracheotomy related tears, the fact that an opening in the trachea already exists and that the lesion rarely extends beyond the carina, should guide the surgeon to make every effort to repair the laceration through this existing access. Our extended tracheotomy technique together with the use of thoracoscopic instruments has been shown to be very helpful in the immediate successful treatment of this fearsome complication

## References

- 1 Marty-Ané CH, Picard E, Jonquet O, Mary H. *Membranous tracheal rupture after endotracheal intubation*. Ann Thorac Surg 1995;60:1367-71.
- 2 Hasan A, Low DE, Ganado AL, Norton R, Watson DC. *Tracheal rupture with disposable polyvinylchloride double-lumen endotracheal tubes*. J Cardiovasc Anaesth 1992;6:208-11.
- 3 Sternfeld D, Wright S. *Tracheal rupture and the creation of a false passage after emergency intubation*. Ann Emerg Med 2003;42:88-92.
- 4 Walz MK, Schmidt U. *Tracheal lesion caused by percutaneous dilatational tracheostomy – a clinico-pathological study*. Intensive Care Med 1999;25:102-5.
- 5 Jacobs JR, Thawley SE, Abata R, Sessions DG, Ogura JH.

- Posterior tracheal laceration: a rare complication of tracheostomy.* Laryngoscope 1978;88:1942-6.
- <sup>6</sup> Ross HM, Grant FJ, Wilson RS, Burt ME. *Nonoperative management of tracheal laceration during endotracheal intubation.* Ann Thorac Surg 1997;63:240-2.
- <sup>7</sup> Mussi A, Ambrogi MC, Menconi G, Ribechini A, Angeletti CA. *Surgical approaches to membranous tracheal wall lacerations.* J Thorac Cardiovasc Surg 2000;120:115-8.
- <sup>8</sup> Angelillo-Mackinlay T. *Transcervical repair of distal membranous tracheal laceration.* Ann Thorac Surg 1995;59:531-2.

Received January 10, 2007 - Accepted May 24, 2007