

CASE SERIES AND REPORTS

Sinonasal and rhinopharyngeal solitary fibrous tumour: a case report and review of the literature

Tumore fibroso solitario nasosinusale e rinofaringeo: un caso clinico e una revisione della letteratura

S. RIZZO, A.A.M. GIUNTA, A. PENNACCHI

Department of Otorhinolaryngology-Head and Neck Surgery Santa Maria Hospital of Terni, Italy

SUMMARY

Solitary fibrous tumours are rare neoplasms that arise mostly from the pleura. Much more rarely they can also be found in extrapleural sites, including the head and neck. We report a rare case of a sinonasal and rhinopharyngeal solitary fibrous tumour. The tumour, measuring 67 x 28 x 55 mm, was first embolised and then successfully removed through endonasal endoscopic surgery. Histopathologic analysis confirmed the nature of the lesion, which was positive for CD34 and vimentin. A post-operative CT scan and endoscopic follow-up demonstrated total resection and absence of recurrence after 13 months.

KEY WORDS: Solitary fibrous tumour • Extrapleural solitary fibrous tumour • Endoscopic resection • Sinonasal tumour • Rhinopharyngeal tumour • Case report

RIASSUNTO

I tumori fibrosi solitari sono neoplasie rare, che si sviluppano principalmente a livello pleurico. Molto più raramente possono comunque coinvolgere sedi extrapleuriche tra cui la testa e il collo. Riportiamo un raro caso di tumore fibroso solitario extrapleurico nasosinusale e rinofaringeo. La neoplasia, di 67 x 28 x 55 mm, è stata prima embolizzata e poi asportata con successo per via endoscopica transnasale. L'esame istologico ha confermato la natura della lesione, che si è dimostrata positiva alla CD34 e alla Vimentina. Una TC post-operatoria e uno stretto programma di follow-up endoscopico hanno dimostrato l'assenza di persistenze e o recidive di malattia dopo 13 mesi.

PAROLE CHIAVE: Tumore fibroso solitario • Tumore fibroso solitario extrapleurico • Tumore naso-sinusale • Tumore rinofaringeo • Caso clinico

Acta Otorhinolaryngol Ital 2015;35:455-458

Introduction

Solitary fibrous tumours (SFTs) are rare neoplasms arising in the majority of the cases from the pleura. Extrapleural forms are much more rare, especially in the head and neck. To our knowledge, no more than 31 cases involving nasal cavities and paranasal sinuses have been described. We present an additional case of a sinonasal and rhinopharyngeal SFT.

Case report

A case of massive sinonasal and rhinopharyngeal extrapleural SFT has been treated at Santa Maria Hospital of Terni, Italy. The patient, a 26-year-old man, came to our attention complaining of nasal obstruction, muco-purulent rhinorrhea and frequent epistaxis. He was also affected by a right temporo-mandibular joint ankylosis as the result of a previous trauma. Endoscopic evaluation showed a reddish mass, completely obliterating the left nasal cav-

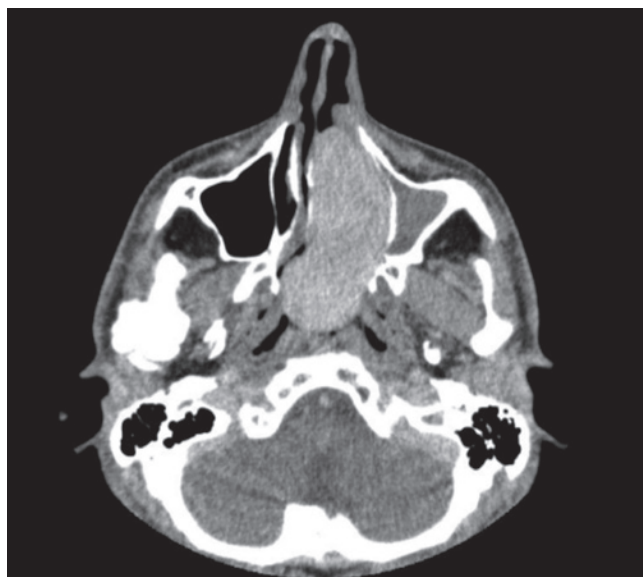


Fig. 1. Sinonasal and rhinopharyngeal solitary fibrous tumour. CT image axial section.

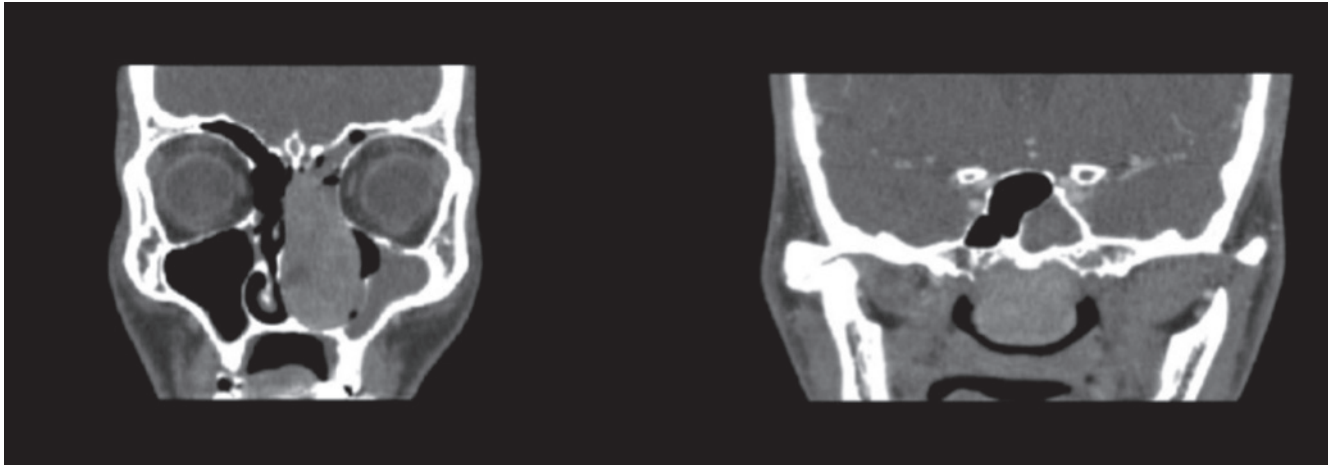


Fig. 2. Same patient. CT coronal sections.

ity and rhinopharynx. A CT scan (Figs. 1, 2) revealed an isodense, solid, neoplasm with mild and homogeneous contrast enhancement, of 67 x 28 x 55 mm, involving rhinopharynx, left nasal cavity, ethmoid cells and sphenoid sinus up to the level of the optic nerve.

We performed embolisation of the mass and subsequent surgical resection. A tracheotomy under local anaesthesia was necessary since it was impossible to introduce the endotracheal tube through the mouth because of the temporomandibular joint disease. After tracheotomy, total anaesthesia was obtained and we performed an endoscopic piecemeal resection of the mass with subsequent elevation and resection of the periosteum of the bones that the tumor contacted. Haemostasis was obtained by electrocautery and nasal packing. The packing was removed after five days, and no complications were noted.

Histological examination confirmed the lesion to be an extrapleural SFT with positivity for CD34 and vimentin (Fig. 3). After one month, the surgical cavity was clear and well-epithelialised. Follow-up CT confirmed total resection of the neoplasm (Fig. 4). The patient is still disease free after 13 months and is following our endoscopic follow-up programme (Fig. 5).

Discussion

Solitary fibrous tumours (SFTs) are rare neoplasms of mesenchymal origin first described by Klemperer and Rabin in 1931, and classified in pleural SFTs and extrapleural SFTs. Extrapleural forms, much more rare, can be found in several anatomical sites, including the head and neck. In the head and neck, SFTs have been described at the level of external ear canal, lacrimal sac, larynx, thy-

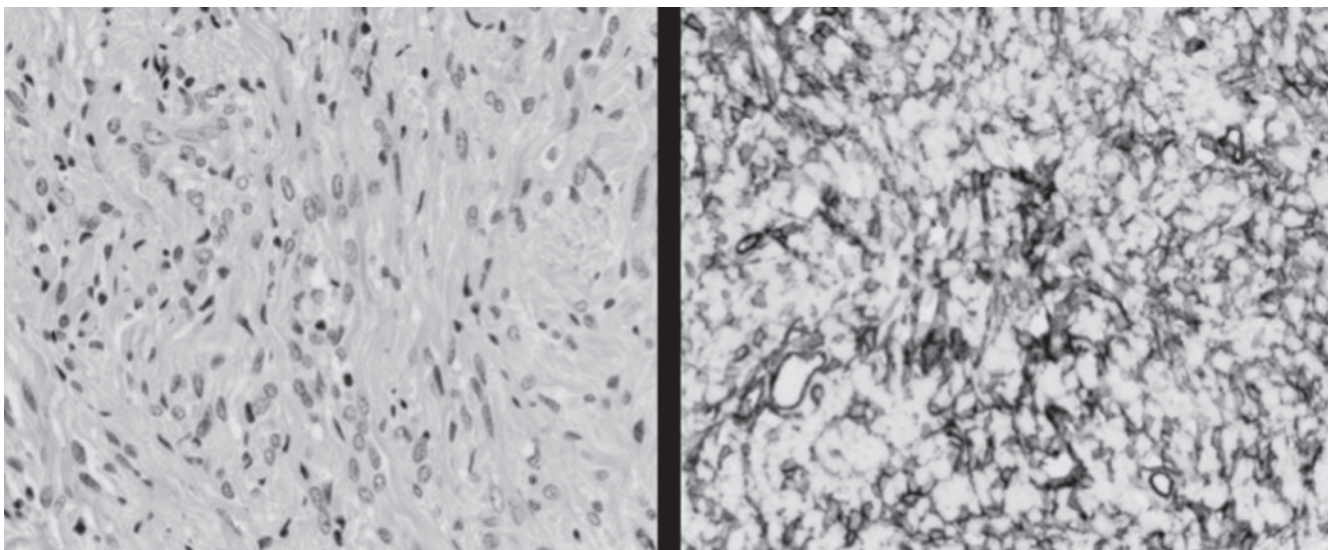


Fig. 3. Solitary fibrous tumour. Original magnification 20x. On H&E staining the tumour has a monotonous appearance and is composed of rounded-to-spindle cells with vesicular nuclei. On CD34 staining, the strong positivity of cells is evident.

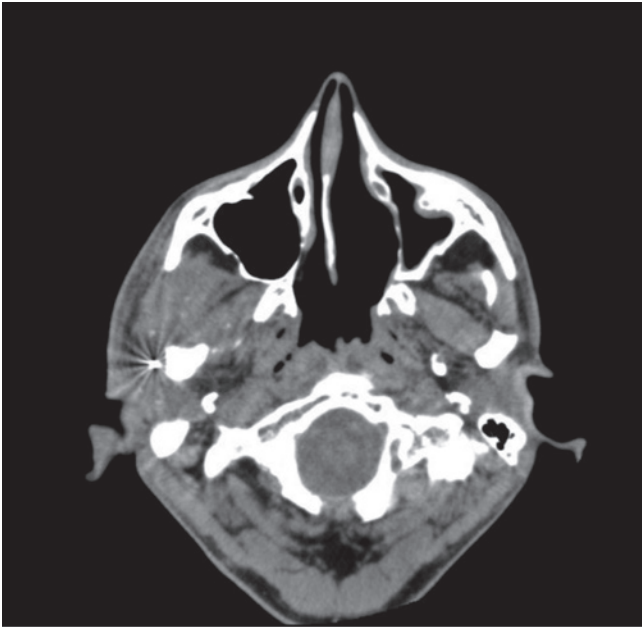


Fig. 4. Post-operative result.

roid gland, major salivary glands, parapharyngeal space, nasal cavity, orbit and rhinopharynx. These tumours usually show a benign behaviour and present themselves as space-occupying masses, which compress neighbour structures and determine a certain degree of bone resorption. In the sinonasal tract, they lead to nasal obstruction, more commonly unilateral, as well as nasal discharge, epistaxis and headache.

Malignant forms, with local aggressiveness and metastatic potential, albeit described, are exceptional, amounting for less than 5-10% of extrapleural SFTs. A markedly increased cellularity, nuclear atypia, intensive mitotic activity (> 4 mitoses/10 high power fields) and necrotic areas are to be considered as malignant criteria.

From a histological point of view, these neoplasms are capsulated tumours, constituted of fibrous tissue and capillaries surrounded by round or spindle cells with vesicular nuclei, without a well-defined growth pattern and with some combinations of different patterns.

By immunohistochemical analysis, cells are positive for CD34, vimentin and frequently bcl-2, and negative for keratin, desmin and S100 protein.

In our opinion, for sinonasal forms, CT is the best imaging modality for diagnosis since it allows precise knowledge of tumour extension and the amount of bone resorption. CT findings are a well-demarcated isodense mass with heterogeneous contrast enhancement. MRI should be considered as a second step examination reserved for cases with orbit or endocranial extension. At MRI, the tumor appears as hypo- or isointense on T1-weighted images and hypo- or, more commonly, hyperintense on T2-weighted images, with heterogeneous contrast enhancement after gadolinium infusion.

Treatment of choice is surgical resection with negative margins. Although not amenable to en bloc resection, endoscopic sinus surgery with piecemeal resection and subsequent elevation and resection of the periosteum of the tumour-contacting bone has been demonstrated to be a good option since it allows complete clearance of the tumour by a mini invasive procedure. We also embolised the tumour before the operation to decrease bleeding, but other authors have intervened without any additional treatment and report no particular bleeding complications during the procedure or in the post-operative period.

Alternative treatment modalities, such as radiotherapy or embolisation, even if described in literature, cannot be considered as effective.

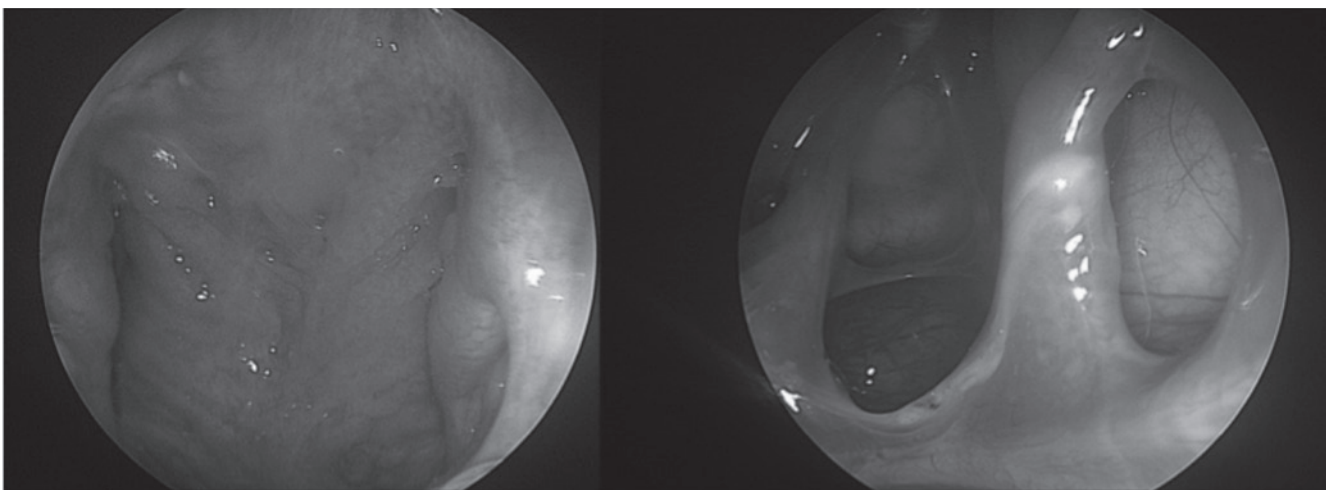


Fig. 5. Endoscopic outcome at one year post-surgery.

References

- Briselli M, Mark EJ. *Solitary fibrous tumor of the pleura: Eight new cases and review of 360 cases in literature.* Cancer 1981;47:2678-89.
- Cox DP, Daniels T, Jordan RC. *Solitary fibrous tumor of the head and neck.* Oral Surg Oral Med Oral Pathol Oral Radiol Endod 2010;110:79-84.
- Daigeler A, Lehnhardt M, Langer S, et al. *Clinicopathological findings in a case series of extrathoracic solitary fibrous tumors of soft tissues.* BMC Surg 2006;6:10.
- Eloy P H, Nollevaux MC, Watelet JB, et al. *Endonasal endoscopic resection of an ethmoidal solitary fibrous tumor.* Eur Arch Otorhinolaryngol 2006;263:833-7.
- Fujikura T, ishida M, Sekine K, et al. *Solitary fibrous tumor arising from the superior nasal turbinate: a case report.* J Nippon Med Sch 2012;79:373-6.
- Goodlad JR, Fletcher CD. *Solitary fibrous tumour arising at unusual sites: analysis of a series.* Histopathology 1991;19:515-22.
- Insabato L, Siano M, Somma A, et al. *Extrapleural solitary fibrous tumor: a clinicopathologic study of 19 cases.* Int J Surg Pathol 2009;17:250-4.
- Janjua A, Sklar M, Macmillan C, et al. *Endoscopic resection of solitary fibrous tumors of the nose and paranasal sinuses.* Skull Base 2011;21:129-34.
- Kim HJ, Lee HK, Seo JJ, et al. *MR imaging of solitary fibrous tumors in the head and neck.* Korean J Radiol 2005;6:136-42.
- Kim TA, Brunberg JA, Peason JP, et al. *Solitary fibrous tumor of the paranasal sinuses: CT and MR appearance.* AJNR Am J Neuroradiol 1996;17:1767-72.
- Klemperer P, Rabin CB. *Primary neoplasms of the pleura: a report of five cases.* Arch Pathol (Chic) 1931;11:385-412.
- Martínez V, Jiménez ML, Cuatrecasas M, et al. *Solitary naso-sinusal fibrous tumor.* Acta Otorrinolaringol Esp 1995;46:323-6.
- Tenna S, Poccia I, Cagli B, et al. *A locally aggressive solitary fibrous tumor of the leg: Case report and literature review.* Int J Surg Case Rep 2012;3:177-80.
- Traweek ST, Kandalaf P. *The human hematopoietic progenitor cell antigen (CD34) in vascular neoplasia.* Am J Clin Pathol 1996;96:25-31.
- Vallat-Decouvelaere AV, Dry SM, Fletcher CD. *Atypical and malignant solitary fibrous tumors in extrathoracic locations: evidence of their comparability to intra-thoracic tumors.* Am J Surg Pathol 1998;22:1501-11.
- Wu WW, Chu JT, Romansky SG, et al. *Pediatric renal solitary fibrous tumor: report of a rare case and review of the literature.* Int J Surg Pathol 2015;23:34-47.

Received: August 5, 2013 - Accepted: September 5, 2013